

Birla Central Library

PILANI (Jaipur State)

Class No :- 574.4

Book No :- S 283 L

Accession No :- 30146

MCGRAW-HILL PUBLICATIONS IN THE
ZOOLOGICAL SCIENCES

A. FRANKLIN SHULL, CONSULTING EDITOR

LABORATORY STUDIES
IN COMPARATIVE ANATOMY

*The quality of the materials used in the manufacture
of this book is governed by continued postwar shortages.*

SELECTED TITLES FROM
MCGRAW-HILL PUBLICATIONS IN THE
ZOOLOGICAL SCIENCES

A. FRANKLIN SHULL, *Consulting Editor*

- Baitsell* · HUMAN BIOLOGY
Breland · MANUAL OF COMPARATIVE ANATOMY
Burlingame · HEREDITY AND SOCIAL PROBLEMS
Chapman · ANIMAL ECOLOGY
Clausen · ENTOMOPHAGOUS INSECTS
Frost · GENERAL ENTOMOLOGY
Goldschmidt · PHYSIOLOGICAL GENETICS
Graham · FOREST ENTOMOLOGY
Haupt · FUNDAMENTALS OF BIOLOGY
Hyman · THE INVERTEBRATES: PROTOZOA THROUGH CTENOPHORA
Johannsen and Butt · EMBRYOLOGY OF INSECTS AND MYRIAPODS
Metcalf and Flint · INSECT LIFE
Mitchell · GENERAL PHYSIOLOGY
Mitchell and Taylor · LABORATORY MANUAL OF GENERAL PHYSIOLOGY
Pearse · ANIMAL ECOLOGY
Reed and Young · LABORATORY STUDIES IN ZOOLOGY
Riley and Johannsen · MEDICAL ENTOMOLOGY
Rogers · TEXTBOOK OF COMPARATIVE PHYSIOLOGY
LABORATORY OUTLINES IN COMPARATIVE PHYSIOLOGY
Senning · LABORATORY STUDIES IN COMPARATIVE ANATOMY
Shull · EVOLUTION
HEREDITY
Shull, LaRue, and Rùthven · PRINCIPLES OF ANIMAL BIOLOGY
LABORATORY DIRECTIONS IN PRINCIPLES OF ANIMAL BIOLOGY
Snodgrass · PRINCIPLES OF INSECT MORPHOLOGY
Storer · GENERAL ZOOLOGY
LABORATORY MANUAL FOR GENERAL ZOOLOGY
Van Cleave · INVERTEBRATE ZOOLOGY
Welch · LIMNOLOGY
Wieman · GENERAL ZOOLOGY
AN INTRODUCTION TO VERTEBRATE EMBRYOLOGY
Wolcott · ANIMAL BIOLOGY
Wolcott and Powell · LABORATORY GUIDE IN ANIMAL BIOLOGY

There are also the related series of McGraw-Hill Publications in the Botanical Sciences, of which Edmund W. Sinnott is Consulting Editor, and in the Agricultural Sciences, of which Leon J. Cole is Consulting Editor.

LABORATORY STUDIES
IN
COMPARATIVE ANATOMY

BY
W. C. SENNING, PH.D.
Department of Zoology, Cornell University

FIRST EDITION
SIXTH IMPRESSION

McGRAW-HILL BOOK COMPANY, INC.
NEW YORK AND LONDON
1937

COPYRIGHT, 1937, BY THE
MCGRAW-HILL BOOK COMPANY, INC.

PRINTED IN THE UNITED STATES OF AMERICA

*All rights reserved. This book, or
parts thereof, may not be reproduced
in any form without permission of
the publishers.*

PREFACE

The studies in the comparative anatomy of vertebrates presented here are the result of a number of years of teaching experience in rather large laboratory classes. From year to year, those parts of the outlines which have appeared difficult to the students have been eliminated or revised. The result is a set of outlines with which the average student is able to do independent work. When a satisfactory understanding of the definitive structure is dependent upon, or may be gained more readily from, a knowledge of its development, short developmental accounts of the structures in question are given. These are not intended to eliminate the necessity of textbook readings, but rather to give the student readily available, summarized information which may be helpful in the understanding of laboratory work. These brief accounts are supplemented from time to time with oral discussions by the laboratory instructor.

It is the opinion of the author that, in an elementary course in comparative anatomy, as much information as can be grasped by the average student may be presented by a careful study of a few selected forms. It is believed that more valuable training is to be gained by careful work upon a few rather than superficial work upon a larger number of animals. The careful study of a few forms well chosen will give the student the background and structural framework into which subsequently acquired knowledge of vertebrate animals may be fitted. For this reason only three animals, the Shark, Necturus and the Cat, have been chosen for study.

It has been the experience of the writer that a student learns to appreciate the phylogenetic significance and importance of structures more readily in a study by systems of organs than by type forms. Such a study presents, however, numerous mechanical difficulties in the care and preservation of specimens extending over a period of time. Certain of the studies presented in these outlines have been grouped whenever possible to eliminate such difficulties. It has been found advisable to use

demonstration specimens frequently. Added student interest may be stimulated by saving the best dissections made by students from year to year and presenting them as models to be equaled or bettered.

As a means of recording laboratory observations, each student is supplied with outline drawings to be labeled, or completed and labeled, depending upon the nature of the particular study. While the value of drawings made by the students is fully recognized, it is also clear that a drawing hurriedly executed may be of less value for both future reference and training in careful observation than no drawing at all. This is especially true if the study necessitates a complicated drawing involving a great amount of time. The method of supplying outline drawings saves time which may be more profitably devoted to further and more detailed observations. The frequent use of oral and written quizzes and dissection checks may be used to inculcate the principle of careful observation.

The writer wishes to acknowledge his indebtedness to the many instructors, especially Dr. A. S. Hazzard, Dr. R. P. Hunter and Dr. R. C. Tasker, who have used these outlines while they were being developed into their present form. Particularly am I indebted to Dr. H. D. Reed for reading the manuscript and offering many valuable suggestions and criticisms.

W. C. S.

ITHACA, N. Y.,
June, 1937.

CONTENTS

	PAGE
PREFACE.	v
INTRODUCTION	1
General Directions	1
Supplies, Textbooks, and Instruments.	1
Care of Study Preparations and Materials.	1
Laboratory Records.	2
Anatomical Terms of Place and Direction	3
CHAPTER I	
THE SKELETAL SYSTEM	5
Divisions of the Skeletal System	5
The Skull	6
Past History.	6
The Cartilaginous Skull	7
The Primitive Chondrocranium.	7
The Skull of the Shark	8
The Teeth of the Shark	16
The Cartilage and Dermal Bone Skull.	17
The Skull of the Sturgeon	17
The Cartilage, Dermal Bone, and Cartilage Bone Skull	19
The Skull of Necturus.	19
The Teeth of Necturus	24
The True Bony Skull	26
The Skull of the Cat	28
The Teeth of the Cat	36
The Vertebral Column, Ribs, and Sternum.	38
Early Development of the Vertebral Column.	39
The Vertebral Column and Ribs of the Shark	40
Development of the Vertebrae	43
The Vertebral Column and Ribs of Necturus.	44
Development of the Vertebrae	47
The Vertebral Column, Ribs, and Sternum of the Cat.	48
Development of the Vertebrae	52
The Appendicular Skeleton.	56
The Appendicular Skeleton of the Shark.	56
The Appendicular Skeleton of Necturus	59
The Generalized Plan of Structure of the Girdles	62
The Generalized Plan of Structure of the Pentadactyl Appendage	62
The Appendicular Skeleton of the Cat.	64

CHAPTER II

THE MUSCULAR SYSTEM.	70
Divisions of the Muscular System.	70
The Relations of the Skeletal and Muscular Systems	71
The Origin, Insertion, and Action of Muscles.	72
The Muscular System of the Shark	73
The Trunk Musculature.	73
The Musculature of the Pectoral Girdle and Limb	74
The Muscular System of Necturus	76
The Trunk Musculature.	76
The Musculature of the Pectoral Girdle	77
Muscles of the Upper Arm.	80
The Muscles of the Head and Visceral Skeleton.	81
The Muscular System of the Cat.	84
The Trunk Musculature.	84
The Musculature of the Pectoral Girdle and Fore Limb	88

CHAPTER III

THE NERVOUS SYSTEM AND SENSE ORGANS.	98
The Divisions of the Nervous System.	98
The Nervous System and Sense Organs of the Shark	99
The Cutaneous Sense Organs.	99
The Nose	102
The Eye.	102
The Eye Muscles.	102
The Innervation of the Eye Muscles	104
The Ear.	105
The Brain.	107
The Development of the Brain.	107
The Cranial Nerves.	109
The Spinal Cord and the Occipital and Spinal Nerves.	113
The Sympathetic System of Nerves.	115
The Gross Anatomy of the Sympathetic System of the Cat	115

CHAPTER IV

THE VISCERA.	117
The Digestive and Respiratory Systems of the Shark	117
The Mouth or Oral Cavity and Pharynx.	117
The Organs of the Abdominal Cavity	119
The Supporting Membranes	121
The Major Digestive Glands.	123
The Development of the Liver and Pancreas.	124
The Urinogenital System of the Shark.	126
The Urinogenital System of the Female	126
The Urinogenital System of the Male	128
The Development of the Kidney Systems of Vertebrates.	131
The Digestive and Respiratory Systems of Necturus	136

CONTENTS

ix

	PAGE
The Mouth Cavity and Pharynx	136
The Organs of the Abdominal Cavity	138
The Urinogenital System of Necturus	139
The Urinogenital System of the Female	139
The Urinogenital System of the Male	140
The Digestive and Respiratory Systems of the Cat	142
The Mouth Cavity and Pharynx	142
The Organs of the Abdominal Cavity	144
The Urinogenital System of the Cat	148
The Urinogenital System of the Female	148
The Urinogenital System of the Male	150
Vestigial and Rudimentary Structures in the Urinogenital System of Mammals	154

CHAPTER V

THE CIRCULATORY SYSTEM	155
The Divisions of the Circulatory System	155
The Blood Vascular System of the Shark	156
The Heart	157
The Arteries	158
The Veins	163
The Pericardioperitoneal Canal	167
The Blood Vascular System of Necturus	168
The Heart	168
The Arteries	168
The Veins	172
The Blood Vascular System of the Cat	176
The Heart	176
The Veins Cephalad of the Heart	177
The Arteries Cephalad of the Heart	178
The Arteries Caudad of the Heart	181
The Veins Caudad of the Heart	184
The Pulmonary Veins and Internal Structure of the Heart	186

LABORATORY STUDIES IN COMPARATIVE ANATOMY

INTRODUCTION

GENERAL DIRECTIONS

Supplies, Textbook and Instruments. Students in the course should provide themselves with the following:

1. A copy of the textbook chosen for the course.
2. The laboratory outlines and one set of the plates to be used with the outlines.
3. Hard drawing pencils, 5H or 6H.
4. A pad of emery paper for pointing pencil leads.
5. One set of thin-lead, colored crayons comprised of the following colors: blue, brown, red, yellow, orange, green, gray.
6. A pencil eraser.
7. A set of dissecting instruments chosen not for the number but for the quality of the instruments contained. It should include the following:
 - 1 pair scissors, heavy, straight, one blunt point.
 - 1 pair scissors, fine, straight, sharp points.
 - 1 pair Carmalt's straight splinter forceps.
 - 1 pair forceps, heavy, straight points with corrugated tips.
 - 2 scalpels, one medium large, one small fine or in place of the two scalpels, one set of assorted scalpel blades and detachable handle may be substituted.
 - 1 blunt seeker or probe.
 - 1 small Pike-Arkansas or Belgium sharpening stone.
8. A laboratory coat or rubber apron is advisable.

Care of the Study Preparations, Material and Order in the Laboratory. During the course of the year, many demonstration and study preparations will be assigned for the use of the student. The students must recognize their responsibility for keeping these

2 LABORATORY STUDIES IN COMPARATIVE ANATOMY

preparations in the best of condition. All preparations must be returned to their proper place at the end of each laboratory period. Others use the same preparations, and it is essential that any preparation found damaged, broken or with parts missing be reported to the instructor immediately. All specimens being dissected by the student must always be placed in the assigned containers. It is not the instructor's obligation to look for misplaced specimens.

Whether the laboratory is a desirable place in which to work depends on the student. His cooperation is a necessity.

Laboratory Records. Each student shall provide himself with a set of plates drawn for use with this manual in which some drawings are complete; others are to be completed. The plates are to be completed and labeled as a record of laboratory observations. This task should not be undertaken, however, until the dissections have been demonstrated to the satisfaction of the instructor. All plates must be completed in the laboratory. Credit should not be given for plates completed outside the laboratory.

The plates may be spoiled by careless labeling. Good and uniform results may be obtained by observing the following suggestions:

1. Place the plate number in the upper right-hand corner of the sheet.
2. Below the figure, place the figure number and title of the drawing.
3. In the lower right-hand corner, the plate should bear the student's name and the date of completion.
4. The names of labeled parts should be connected by guide lines with the parts they designate.
5. Guide lines should be as short as possible. It is permissible and often advisable to label on both sides of the drawing. Strive for balance in the completed plate.
6. Do not allow guide lines to cross the drawing more than is necessary. They should never cross each other.
7. A carefully drawn, broken guide line is preferable, but to save time a solid line is permissible if drawn with a sharp, hard pencil.
8. When possible, guide lines should be parallel, but for clearness and room for labeling, they may diverge toward the margin

of the plate. All labeling should be parallel with the upper or lower margin of the plate.

9. Print all labels using a ruled guide line.
10. Erase all projecting parts of guide lines.

ANATOMICAL TERMS OF PLACE AND DIRECTION

It is convenient to be able to locate parts in an animal irrespective of the animal's position in relation to its environment. The following terms are in common usage in comparative anatomy. Of the two adverbial forms in common usage, *e.g.*, laterad and laterally, proximad and proximally, dorsad and dorsally, etc., the shorter form is preferred and used in these outlines.

Dorsum, the back, the upper side of an appendage or part.

Dorsal, pertaining to the back or upper side.

Dorsad, toward the dorsum or back.

Venter, the belly, the underside of an appendage or part.

Ventral, pertaining to the belly or underside.

Ventrad, toward the ventral side.

Cephalon, the head.

Cephalic, of or pertaining to the head, situated near the head.

Cephalad, toward the head or anterior end of the body.

Cauda, the tail.

Caudal, of or pertaining to the tail.

Caudad, toward the tail or posterior part of the body.

Meson, the imaginary middle plane of the body dividing it into right and left halves.

Mesal, pertaining to or situated near the middle plane.

Mesad, toward the meson.

Lateral, lying at or pertaining to the side.

Laterad, toward the side.

Ectal, pertaining to the outer surface of a body.

Ectad, outwards, or toward the surface.

Ental, pertaining to the inner part or mass of a body.

Proximal, designating that part of a limb or other part which is nearest its point of attachment.

Proximad, toward the proximal or attached end.

Distal, remote from the origin or attachment, the free end of a limb or part.

Distad, toward the distal or free end.

For clearness and brevity, it is often convenient to compound anatomical adverbs and adjectives, *e.g.*, **cephalo-laterad** is interpreted as extending toward the head and side of the body, **caudo-ventrad**, extending toward the tail and venter of an animal, etc.

4 LABORATORY STUDIES IN COMPARATIVE ANATOMY

It is convenient and necessary at times to refer to definitely placed sections through the body of an animal. That section, passing through the meson of the body, is a **mid-sagittal section**. Such a section passes cephalo-caudad, from dorsum to venter, and divides the animal into right and left halves. All sections parallel to the mid-sagittal are **sagittal sections**. A section passing through the body at right angles to the long axis is a **transverse** or **cross section**. Such a section may be taken at any point along the long axis. Any section cutting the body at right angles to the sagittal and transverse sections, dividing the animal into dorsal and ventral parts, is a **frontal section**. These sections are considered as fixed in their relations in the animal regardless of the animal's position in relation to the substratum. Thus, a frontal section in an animal such as man, walking in an upright posture, would be perpendicular to the horizontal plane of space, while such a section, in a quadruped, would be parallel to the horizontal plane.

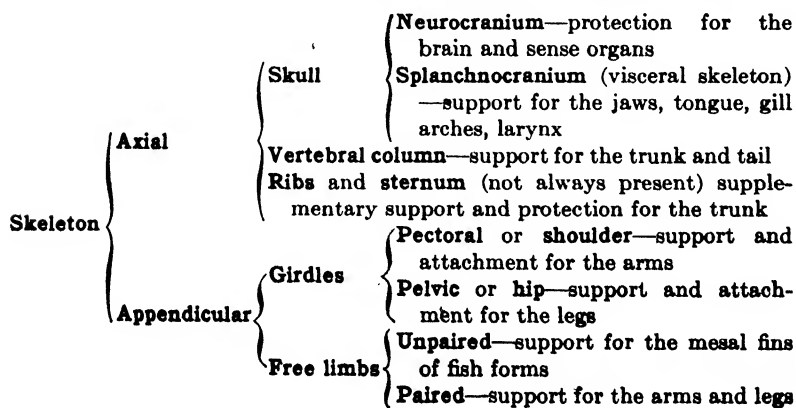
CHAPTER I

THE SKELETAL SYSTEM

The skeletal system of an animal includes all the supporting and protective tissues of the body, the various types of connective tissue everywhere in the body as well as the cartilage and bone. In the following study, however, the term skeletal system is used in a restricted sense to mean those parts of cartilage or bone which constitute the hard skeletal framework of the animal.

The skeleton of a vertebrate, strictly speaking, is composed of **exoskeletal** and **endoskeletal** parts. The exoskeletal parts are those formed from the integument, while the endoskeletal parts are those formed internally to the integument. However, certain portions of the exoskeleton, the **dermal bones** forming in and from the dermis of the integument, become so intimately associated with the endoskeleton that when the term "endoskeleton" is used, it is meant to include both the internal skeleton and the associated dermal bones.

The location of the parts of the internal skeleton is determined by the skeletal requirements of the animal. Skeletal elements will be found wherever there is need for protection, support or the attachment of muscles to bring about movement. Based on the functions performed, the skeleton may be divided as follows:



The sternum, classified above with the axial skeleton, forms a close association with the pectoral girdle in some animals and may be considered as a part of the appendicular skeleton. For our purposes it is considered as a part of the axial skeleton, since in most cases when present, it aids the ribs and vertebrae in the protection and support of the trunk region.

THE SKULL

Past History. The skull, in all probability, has passed through the following stages in its progressive evolution:

1. **The Membranocranium.** This is a purely hypothetical stage, since it is not found in any living vertebrate. It is thought to have been a connective-tissue supporting and protecting framework for the brain and sense organs.

2. **The Cartilage or Chondrocranium.** The membranocranium, in the course of its evolution, was replaced by cartilage. The elasmobranchs possess a chondrocranium which is practically complete, but there are no living intermediates between it and the membranocranium.

3. **The Cartilage and Dermal Bone Cranium.** Bone is added to the chondrocranium in the ganoid fishes. It is deposited in the connective-tissue layer of the skin and is, therefore, of the membrane or dermal type. In the head region of the ganoids, the ganoid scales, which represent the plate portion of the placoid scale of elasmobranchs, fuse to form large bony plates. These entirely surround the cartilaginous neurocranium and the mandibular arch of the splanchnocranium. Because of the clothing nature of these bones when they first appear, they are designated by some as investing bones. Thus, **dermal, membrane and investing** bones are all synonymous names for the same kind of bone.

4. **The Cartilage, Dermal Bone and Cartilage Bone Cranium.** In addition to the dermal bones formed outside of the chondrocranium, centers of ossification appear within the cartilage. Bone formed thus replaces and reduces the amount of cartilage present. Since bone of this type forms within the cartilage, it is designated as cartilage bone; also, since it replaces in part the cartilage present, it may be designated as replacement bone. Thus, **cartilage** and **replacement** bones are identical. This type of skull in the definitive state is found in ganoids and amphibians.

5. **The True Bony Skull.** Here cartilage has almost entirely disappeared, and the skull is composed of investing and replacement bones. These two types of bones, different in origin, may in many cases, become very closely knit together, or even fuse together in such a way as to be indistinguishable. Reptiles, birds and mammals possess this type of skull.

THE CARTILAGINOUS SKULL

Among living vertebrates the cartilaginous skull, or chondrocranium, persists as the definitive skull in only the cyclostomes and elasmobranchs. It is quite probable, however, that the chondrocranium of neither the cyclostome nor the elasmobranch represents the most primitive cartilaginous skull which may have been possessed by the earliest vertebrates.

The Primitive Chondrocranium.

To get some conception of a more primitive type, one may resort to the study of developmental stages of living vertebrates. As the ontogeny of the skull in various vertebrates is surprisingly similar, it is not improbable that these developmental stages represent actual stages in the evolution of the chondrocranium.

In early stages, there are in the anterior or head region of vertebrates, in addition to the brain, three pairs of sense organs. Naming these in the cephalo-caudal direction, they are the **olfactory, optic and otic sense organs**. The **notochord** extends as far cephalad beneath the brain as the hypophysis. At first that part of the brain anterior to the notochord, and the sense organs, have little or no support. All are protected by surrounding connective-tissue capsules.

Support is soon provided for the brain by the appearance of two sets of paired cartilages, the **parachordal bars** and **prechordal bars** or **trabeculae**. The parachordal bars appear at either side of the notochord and extend as far cephalad as the anterior end of the notochord. The prechordal bars develop anterior to the parachordal bars and lie beneath the brain one on either side of the mid-line. **Cartilaginous capsules** develop surrounding the olfactory and otic sense organs. The capsule surrounding the eye usually does not chondrify but may in some few cases.

An expansion by growth and a fusion between the cartilages present occurs next. The parachordal bars expand and fuse with

each other beneath the brain and, in doing so, embed the anterior end of the notochord in the cartilage. This region is now called the **basilar plate**. The basilar plate fuses laterally with the otic capsules. Anteriorly, the basilar plate fuses with the caudal ends of the prechordal bars, and the prechordal bars fuse with each other at their anterior ends to form the **ethmoid plate**. In time the prechordal bars of opposite sides may spread in toward the mid-line and fuse beneath the brain, or fusion may never be completed in this region. Anteriorly, the ethmoid plate may fuse with the olfactory capsules. The optic capsule which is represented by the sclerotic coat of the eye, except in very few animals, never fuses with the neurocranium, thus providing the necessary freedom of movement of the eye.

At this stage then, the neurocranium consists of a ventral support, platformlike, upon which the brain rests. Side walls are lacking except in so far as the sense capsules form side walls in the otic and olfactory regions. Later side walls are formed in the region between the otic and olfactory capsules either by an upward growth of the lateral margins of the prechordal bars or by the appearance in this region of a pair of distinct **alisphenoid cartilages**. These eventually fuse posteriorly with the otic capsules and ventrally with the trabeculae.

Finally, the side walls grow across toward the mid-line above the brain forming a roof, thus completing the chondrocranium. The roof, however, is generally incomplete, possessing gaps called **fontanels**. In the shark the roof is practically complete, the anterior fontanel being the only place where cartilage fails to form. This gap is closed by a tough connective-tissue membrane. In higher vertebrates, the cartilaginous roof is restricted to a mere arch in the occipital region.

The brain case, therefore, is built up by a growth and subsequent fusion of the parachordal and prechordal bars. The sense capsules form independently, and, except in the case of the optic capsules, fuse with the brain case.

The Skull of the Shark.

Divisions of the Skull. The skull of any vertebrate is divided according to the organs protected or supported by it. The skull of the shark, therefore, may be divided as follows:

A. Neurocranium or cranium.

- a. **Brain case**—median portion surrounding the brain.
- b. **Olfactory capsules**—surrounding the olfactory sense organs.
- c. **Optic capsules**—represented by the sclerotic coat of the eye and usually not fused with the remainder of the skull. The orbit is the excavation in the skull which lodges the eyeball.
- d. **Otic capsules**—surrounding the auditory sense organs.

B. Splanchnocranium or visceral skeleton.

- a. **Arch 1. Mandibular arch**—supporting the jaws.
- b. **Arch 2. Hyoid arch**—supporting the tongue.
- c. **Arches 3 to 7. Gill arches**—supporting the gills.

Preparation of the Skull for Study. For the following study of the spiny dogfish (*Squalus acanthias*), a specimen preserved in brine is provided for dissection by the student.

Carefully remove the skin from both dorsal and ventral regions of the head. In removing the skin from the angles of the mouth, be careful not to destroy some small cartilages which lie just beneath the skin at this point. Try to locate these by probing with the fingers before removing the skin. If unable to do so, consult your instructor for their location. After the skin is removed, carefully dissect away the muscles and connective tissue from the cranium and visceral arches. Never allow the scalpel to slip and cut or nick the cartilage of the cranium or to sever a visceral arch. Clean the visceral arches of the left side only. This should be done sufficiently well to reveal the components of each arch. From at least one arch, the gill rays and gill rakers should not be removed. Work as rapidly as possible as the brine in which the specimens are kept does not prevent the formation of rather unpleasant odors. After the dissection is complete, study the preparation carefully since a demonstration quiz may be called for before the plates are handed out to be labeled. A dissection is not complete until an exact identification can be made of every structure mentioned in the manual.

Dorsal Aspect of the Cranium. Projecting anteriorly from the brain case is the troughlike **rostrum**. At the caudal end of the rostrum will be found a large opening in the cranium, the **anterior fontanel**. The opening may be closed with connective tissue, and if this is the case it should be removed.

On either side, opposite the base of the rostrum, are the thin-walled **nasal capsules**. Before removing the olfactory organs, note that the walls of the capsules are very thin and that they extend to the nasal opening.

If the rostrum has been carefully cleaned, two ligaments will be seen extending caudo-laterad from the tip of this structure, one attaching to the dorsal surface of the nasal capsule and the other to the ventral. The dorsal of these is called the **dorsal ramus of the rostral ligament** and the other the **ventral ramus**.

Directly caudad of the nasal capsules is the **anteorbital process** which is continued in a posterior direction as the **supraorbital crest** and terminates in the strong **postorbital process** just behind the orbit. Continuous caudally with the postorbital process is the narrow **supraotic crest** which extends caudad to terminate in the **postotic process** at the caudo-lateral angle of the cranium. The **brain case** is the median part of the cranium caudad of the rostrum, its limits being located externally by two longitudinal furrows, one on each side. Its relations can be better determined later, when the cranium is opened.

The caudo-lateral parts of the cranium consist of the **otic capsules**. Between these, on the middle line is a depression, the **endolymphatic fossa**. Opening into the fossa are four foramina, two on either side. The more cephalic is the opening for the **endolymphatic duct** and the more caudal for the **perilymph duct**. Radiating from the lateral margin of this fossa are two ridges, one extending laterad and cephalad to a point opposite the postorbital process and the other laterad and caudad toward the postero-lateral corner of the cranium. These lodge the **anterior** and **posterior semicircular canals** of the internal ear, respectively.

The following foramina perforate the dorsal surface of the cranium:

1. On the mid-line just back of the rostrum is the **epiphysial foramen**. This is the locus of the epiphysis, a slight dorsal extension of the brain.

2. Caudad to the nasal capsule is a large opening, the **superficial ophthalmic foramen**, for the superficial ophthalmic trunk of the fifth and seventh cranial nerves.

3. In a line extending caudad of the superficial ophthalmic foramen is a series of small foramina for the passage of slender twigs of the superficial ophthalmic trunk which supply the supraorbital branch of the cephalic canal system.

4. At the caudo-lateral angle of the cranium is located the large **glossopharyngeal foramen** for the passage of the ninth cranial nerve.

5. Just mesad of the glossopharyngeal foramen is the **vagus foramen** for the tenth cranial nerve.

6. By carefully separating the neural arch (dorsal portion) of the first vertebra from the cranium, a large opening into the brain cavity is exposed. This is the **foramen magnum** through which the spinal cord passes. *Do not entirely separate the vertebral column from the cranium.*

Plate 1. Figure 1. Drawing of the Dorsal Aspect of the Cranium of the Shark.

Label the following structures:

anteorbital process	superficial ophthalmic foramen
brain case	otic capsule
endolymphatic fossa	perilymph duct
foramen magnum	endolymph duct
nasal capsule	postorbital process
rostrum	supraorbital crest
glossopharyngeal foramen	epiphysial foramen
vagus foramen	foramina for the twigs of the superficial ophthalmic
elevation caused by the anterior semicircular canal	supplying supra-orbital branch of the cephalic canal system
elevation caused by the posterior semicircular canal	

The Lateral Aspect of the Cranium. This aspect of the cranium presents the rostrum with a strong median **keel** projecting ventrally, the nasal capsule, the orbit with its two processes mentioned above and the otic capsule. An elevation marking the position of the horizontal semicircular canal passes horizontally across the otic capsule.

Several foramina perforate the orbit:

1. Just dorsad of the middle of the ventral margin is the **large optic foramen** for the passage of the optic nerve from the eye.

2. In the cephalic portion of the roof of the orbit is the **large superficial ophthalmic foramen** and, just caudad of this, the series of small foramina which have already been seen and named on the dorsal side.

3. Cephalad and somewhat ventrad of the superficial ophthalmic foramen is the **deep ophthalmic foramen** for the deep ophthalmic branch of the fifth cranial nerve. Probe this foramen with a stiff bristle and see where it leads.

12 LABORATORY STUDIES IN COMPARATIVE ANATOMY

4. In the posterior portion of the orbit, just cephalad of the postorbital process is a large opening, the **trigemino-facial foramen**, for the passage of the fifth and seventh cranial nerves.

5. In the dorsal portion of the orbit, a little above the middle of a line between the trigemino-facial and superficial ophthalmic foramina, is a small opening, the **trochlearis foramen**, for the passage of the fourth cranial nerve.

6. A short distance anterior to the trigemino-facial foramen and just caudad of the process of the upper jaw which projects into the orbit is the **occulomotor foramen** for the third cranial nerve.

7. Just ventrad of the trigemino-facial foramen is a small opening, the **abducens foramen**, for the passage of the sixth cranial nerve.

8. Ventrad of the abducens foramen is the larger **transbasal canal** by means of which the blood sinuses of the two orbits communicate.

Several other small openings perforate the orbit. These are foramina for blood vessels and are not described or located since they are not important in subsequent work.

Near the ventral margin of the cranium, just caudad of the postorbital process, is a process projecting from the side of the otic capsule. This process is perforated by a foramen for the passage of the hyomandibular trunk of the facial nerve.

A careful study of the nerve foramina is advisable since a thorough knowledge of them will greatly facilitate the dissection of the cranial nerves to be made later on another specimen.

The Splanchnocranium. This division of the skull is also commonly referred to as the visceral skeleton since it is associated with the anterior end of the alimentary tract. It is composed of a number of parts called the **visceral arches**. It is quite probable that in a more primitive ancestral skull all the visceral arches were similar in structure, but in the shark, certain of the arches have been modified depending upon the specific function performed by the arch.

Arch 1. The **mandibular arch** is made up of the **pterygo-quadrangle cartilage** which supports and forms the margin of the upper jaw and **Meckel's cartilage** which serves a similar purpose in the lower jaw. The pterygoquadrangle presents two processes. The more anterior is the **palatine process** which projects into the orbit and articulates with the neurocranium at the basilar process,

described below. The more caudal is the **quadrate process**. This is a dorso-lateral expansion from the caudal end of the pterygoquadrate cartilage. *Carefully work out the articulation between upper and lower jaw.*

It is thought that the upper and lower jaws were formed from a single visceral arch which bent upon itself at its middle, the point of bending eventually forming the articulation between upper and lower jaws.

The **labial cartilages** are found at the angle between the pterygoquadrate and Meckel's cartilages. There are two sets of these; one made up of two cartilages extending around the angle of the mouth. The other is a single cartilage located externally to the upper jaw. Some would attach considerable significance to the presence of the labial cartilages, interpreting them as vestiges of preoral visceral arches. It seems more probable, however, that they have no such significance, simply having formed as support for the folds of skin in this region.

Arch 2. This is comprised of a dorsal **hyomandibular cartilage**, a middle **ceratohyal** and a median, ventral **basihyal**. The two latter elements together comprise the **hyoid proper**. The two dorsal elements of this arch bear upon their caudal edges long delicate strands of cartilage, the **gill rays** which support the gill borne by this arch. The **spiracle** opens just cephalad of the hyomandibular cartilage. This cartilage also connects the jaws with the cranium. *Carefully work out the relations of the mandibular and hyoid arches to the cranium and to each other.* The relations exemplified here are known as the **hyostylic** type of jaw suspension. Understand and be able to explain these relationships as they are.

Arches 3 to 7. The **gill arches** are very much alike, each being composed of several parts. The most dorsal of these is called the **pharyngobranchial**. This articulates ventrally with a short **epibranchial** which is followed by the **ceratobranchial**. This element terminates ventrally in a flat, circular enlargement. The ventral end of each ceratobranchial overlaps the one behind it. The ceratobranchial of fourth visceral arch articulates mesally with a small cartilage, the **hypobranchial**. This cartilage curves mesad and caudad and articulates with an unpaired mesal element, the **anterior basibranchial**. Note that superficially it appears as if the most anterior hypobranchial articulates with the

14 LABORATORY STUDIES IN COMPARATIVE ANATOMY

ceratobranchial of the third visceral arch, but a careful examination will show the relations described above.

The ceratobranchials of arches 5 and 6 articulate mesally with hypobranchials also, and these hypobranchials articulate caudally with the large, flat, triangular **posterior basibranchial**.

Pharyngobranchials of the sixth and seventh arches are fused dorsally.

Note the short projections, the **gill rakers**, extending into the pharynx from the mesal side of the gill arches. Do all the gill arches bear gill rays? Which divisions of each arch possess these structures?

Plate 2. Figure 2. Drawing of the Lateral Aspect of the Cranium and Visceral Skeleton of the Shark.

Label the following structures:

mandibular arch	postorbital process
Meckel's cartilage	supraotic crest
pterygoquadrate cartilage	rostrum
hyoid arch	nasal capsule
hyomandibular cartilage	orbit
ceratohyal	otic capsule
gill arch	ridge caused by horizontal semi-
pharyngobranchial	circular canal
epibranchial	gill ray
ceratobranchial	labial cartilages
glossopharyngeal foramen	quadrate process
anteorbital process	palatine process
supraorbital crest	

Color the visceral arches as follows: arch 1 light blue; arch 2 light brown; arch 3 light yellow; arch 4 light red; arch 5 light orange; arch 6 light green; arch 7 gray. Do not apply too much color. A faint tinge is sufficient. Color is used to emphasize certain definite facts. For this reason a color legend is necessary stating what each color is meant to represent. No drawing in which color is used is complete without this legend. Do not color the labial cartilages.

Plate 3. Figure 3. Diagram of the Lateral Aspect of the Orbit.

In this diagram locate accurately and label the following:

optic foramen	trochlearis foramen
superficial ophthalmic foramen	oculomotor foramen
deep ophthalmic foramen	abducens foramen
trigemino-facial foramen	transbasal canal

Plate 3. Figure 4. Ventral Aspect of the Visceral Arches of the Shark.

Label the following:

anterior basibranchial
 basihyal
 ceratohyal
 Meckel's cartilage
 quadrate process

posterior basibranchial
 ceratobranchials
 hypobranchials
 pterygoquadrate cartilage

Use the same colors as in Plate 2, Fig. 2. Do not color basibranchials. Color is used in these figures to indicate arch components. The basibranchials do not belong to any one particular arch. Apply only a slight amount of color. Do not forget to add color legend.

Ventral Aspect of the Cranium. *Detach the mandibular and hyoid arches and expose the venter of the cranium.*

In this aspect notice the rostrum with its strong median keel projecting cephalad. On either side of the base of the rostrum are the nasal capsules, and between these and the keel of the rostrum are two fenestrae, across the openings of which are stretched sheets of connective tissue.

Between the orbits, the floor of the cranium narrows abruptly, forming a bridge between the broader anterior and posterior portions. Caudad of this bridge will be seen on each side a rounded projection, the **basilar process**. The anterior surface of this process serves as the articulation for the palatine process of the upper jaw. On a median line just a little caudad of the basilar processes is a small opening, the **carotid foramen**, through which the carotid commissure arteries pass. This foramen also marks approximately the anterior extent of the notochord into the skull.

Regions of the Cranium. It will be convenient for future work upon the skull to designate and name the various regions as follows:

1. **Occipital region**, the part of the brain case proper surrounding and extending a short distance cephalad of the foramen magnum.

2. **Otic region**, that part of the cranium surrounding and adjacent to the inner ear (indicated in the shark by the presence of the semicircular canals).

3. **Orbitotemporal region**, that part of the brain case proper anterior to the occipital region and included between the orbits.

4. **Ethmoid region**, that part of the skull anterior to the orbitotemporal region including nasal capsules and the part of the brain case between the nasal capsules.

Plate 4. Figure 5. Ventral Aspect of the Cranium of the Shark.

By dotted lines indicate and label the principal regions of the cranium. Also label the following:

- | | |
|---------------------|----------------------------------|
| anteorbital process | nasal capsule |
| orbit | superficial ophthalmic foramen |
| basilar process | palato-basilar articular surface |
| postorbital process | carotid foramen |
| rostral keel | |

Internal Relationships of the Cranium. After the study of the external structures and the drawings have been completed, the cranium may be sectioned to determine internal relationships. *Make a series of transections through the cranium, each about one-fourth of an inch thick, and lay these out in order.* Study the extent and relations of the brain case to the skull as a whole and to the ethmoid and otic regions. Identify the three semicircular canals. Notice the way in which they are embedded in the cartilage of the otic region. A detailed study of these will be made later on another specimen.

Teeth of the Shark. The teeth of vertebrates do not belong specifically to the skeletal system. They develop independently of, and only secondarily become associated with, the skeleton. It is because of this secondary association, however, that they should be studied at this time.

The teeth of the shark may be considered as modified placoid scales. Placoid scales are present in the shark covering the entire surface of the body. They are minute in size, being just visible to the unaided eye. Each is composed of an embedded plate portion and a projecting spine. The spine of each scale inclines toward the tail. This fact may be verified by stroking the skin of the shark first toward the tail and then toward the head. The points of the spines may be felt in stroking toward the head.

On the ental surface of the upper and lower jaws of the shark, the placoid scales are much larger than elsewhere on the body and serve as teeth. Notice that, while differing in size, the teeth all have the same general shape. This is known as **homodont dentition**. Notice that the teeth are arranged in transverse rows across the jaws and that the teeth of each row back of the first are a little smaller than those of the preceding row. As the marginal teeth are worn or broken off by use, subsequent rows of teeth grow, move up into place and become functional. This succession is continuous throughout the entire lifetime of the individual, new teeth being formed continually to take the place of those worn and broken away. This is called **polyphyodont succession**. *Insert a scalpel under a group of teeth and tear them away from the jaw.* Notice that they have no special socket or groove for attachment but merely rest upon the cartilage. This is known as the **acrodont** type of attachment.

Approximately how many teeth does the shark possess? Approximately what percentage of these is functional at any one time?

The Disarticulated Visceral Skeleton. *Disarticulate the parts of the visceral skeleton. Study the parts sufficiently to be able to identify each independently and identify the arch to which it belongs. An unknown quiz on these and parts of the cranium will be given after the completion of the work.*

THE CARTILAGE AND DERMAL BONE SKULL

The skull of the cartilage ganoid (Chondrostei) represents the stage in which bone is first added to the chondrocranium.

The Skull of the Sturgeon.

Examine a demonstration specimen of the sturgeon.

Notice the particular type of scalation found on the body. There are five longitudinal rows of large bony plates, called **scutes**; a mid-dorsal row, and two lateral rows on either side of the mid-dorsal row. The body, between the longitudinal rows of scutes, is covered by scales not greatly unlike the placoid scales of the shark. It is thought that the bony scutes found here have been formed by the fusion of a number of placoid scales. Only the plate portion of the scales is involved in this fusion, the spine being lost. The plate portion of the placoid scale is formed from

the dermis of the integument, so the scute formed by their fusion is a product of the dermis and, accordingly, is called a "dermal bone."

The Chondrocranium. In the head region of the sturgeon, notice that the scutes, here called **dermal bones**, flatten out and form an outer bony box surrounding and protecting underlying parts. Were one to dissect away these bones, one would find beneath them a complete chondrocranium not unlike that in the shark. Thus, here the skull is double, being composed of an inner cartilaginous and an outer bony cranium. The two are separated, however, even in the adult skull, by a layer of connective tissue surrounding the cartilage, the perichondrium.

The Dermal Bones. Although some of the numerous dermal bones present in the skull of the cartilage ganoid are not constant in number and position, many are and may be named and homologized with certain of the dermal bones of higher vertebrates.

The paired **parietal** bones may be located one on either side of the mid-dorsal line, extending as far cephalad as the eyes and almost as far caudad as the posterior margin of the operculum. The **operculum** is the flap covering the gill region. On the mid-line wedged in between the caudo-medial margins of the parietals is the unpaired **dermoccipital**, and just caudad of the dermoccipital, the median **nuchal** bone. Laterad of the parietals are the large **squamosal** bones. Just caudad of the squamosals are the **supratemporal** bones. The **frontal** bones lie anterior to the parietals. The two frontals are separated at the mid-line by a pair of **rostral** bones. There are a large number of rostral bones, this name being applied to all those anterior to the frontals which cover and protect the rostrum or snout of the animal. Notice that around the margin of the rostrum the individual bones are not so distinct as elsewhere in the skull.

A series of bones surround the orbit. Anterior to the squamosal forming the caudo-dorsal margin of the orbit is the **post-frontal** bone and anterior to this, dorsad of the eye, the **prefrontal** bone. Completing the margin of the orbit on the ventral side are two **suborbital** bones. Caudad of the orbit and covering the gill region is the large **operculare**.

A single bone, the **parasphenoid**, is present on the ventral surface of the skull. This extends from the caudal end of the skull beneath the anterior vertebrae to the tip of the rostrum.

Only the anterior part of this bone is visible in the demonstration specimen.

The Visceral Skeleton. A study of the visceral skeleton of the sturgeon will not be made. Its history in general, however, is not unlike that of the cranium. It would be found that, while the pterygoquadrate and Meckel's cartilages are the functional jaws, dermal bones develop here as in the neurocranium and partially surround the cartilages. The remaining visceral arches need no special mention, since except in minor details, they persist as in the elasmobranch.

Plate 5. Figure 6. Dorsal Aspect of the Skull of the Sturgeon.

Label completely. From this point on it will be left to the student to pick out the labels which should be included. All the names appearing in the text in bold-face type should be included in all drawings in which the respective parts appear.

THE CARTILAGE, DERMAL BONE AND CARTILAGE BONE SKULL

Supplementing the dermal bones described above, cartilage or replacement bone is added to the skull in the ganoids. Except in old individuals, very few cartilage bones occur in the chondrocranium of the cartilage ganoids. This type of bone is more characteristic of the bony ganoids (Holostei). In the ganoids, centers of ossification appear within the chondrocranium. This bone is not formed from, but within, the cartilage by a rather involved process. The cartilage which is first laid down is reabsorbed and bone-forming cells produce bone which replaces the absorbed cartilage.

Although the bony ganoid illustrates a more primitive type of skull in which cartilage, dermal bone and cartilage bone is present, the skull of a urodele amphibian (*Necturus maculosus*) may be used to illustrate this stage in the evolution of the skull.

The Skull of Necturus.

Examine a preserved specimen of *Necturus*. Notice that the investing or dermal bones are not visible on the surface. Although formed in the dermis of the integument as in lower forms, they have sunk beneath the skin and have become more intimately associated with the chondrocranium.

The Chondrocranium. *A balsam mount of the chondrocranium is used for this study. It was prepared by carefully removing the investing or dermal bones, thus exposing the cartilage and ossifications of the primordial cranium.*

The chondrocranium of *Necturus* is rather simple, consisting of two **otic capsules** connected posteriorly by means of the **supra- and basioccipital arches**; and two **trabeculae** extending cephalad to the anterior region of the skull. The trabeculae unite anteriorly to form the **internasal or ethmoid plate** and then diverge to form the **cornua trabecularum**. *Note! The basioccipital arch is very narrow and is often destroyed in the preparation of the balsam mount. If it is not present in the preparation, identify it on a demonstration specimen.* The otic capsules are two large, hollow, oval bodies each perforated ventrally by a large opening, the **fenestra ovalis or fenestra vestibuli**, into which is fitted the **columella**. The columella does not belong to the neurocranium proper but rather to the splanchnocranium and will be treated in detail later.

Anterior to the otic capsules at about the middle of the trabecular bars, there are given off laterally, one on each side, the **quadrate processes**. This, like the columella, is not a morphological part of the neurocranium. It belongs to the splanchnocranium and represents "what is left" of the pterygoquadrate element of the first visceral arch of the shark. It has become much shortened and has fused directly with the chondrocranium. This will be explained in detail when the visceral skeleton is treated.

Cephalad of the quadrate processes are the laterally projecting **anteorbital processes** which are attached to the trabecular bars by means of connective tissue. *Note! These are often lost in the preparation of the chondrocranium and, if not present in your specimen, should be located in a demonstration preparation.*

The **nasal capsules** of *Necturus*, unlike those in most other animals, do not fuse with other parts of the chondrocranium. It is impossible to preserve these in their proper relationships in a prepared specimen. *Study their relationships in a demonstration specimen.*

From the above study, it can be seen that the chondrocranium of *Necturus* is much reduced when compared with that of the shark. This is to be accounted for by the fact that the dermal

bones form early and rapidly, more or less completely and intimately surrounding the brain, thereby preventing the growth and expansion of the cartilage. Thus the chondrocranium of *Necturus* is not provided with the opportunity to develop much beyond a point which in the shark would be embryonic. The trabeculae do not fuse across the mid-line except at the nasal plate, nor do they form side walls.

The amount of cartilage present is further reduced by the appearance of certain cartilage bones. These may be identified in the specimen by a difference in color due to staining technic.

The Cartilage Bones. Two ossifications are present in the otic capsule. The anterior portion of the ear capsule ossifies to form the **prootic** bone, and the posterior, to form the **opisthotic** bone. On either side of the foramen magnum are the **exoccipital** bones, each of which bears an **occipital condyle**. A condyle is a bony process bearing an articular surface. In this case the articulation is with the first vertebra. The exoccipital bones are connected dorsally and ventrally by the supra- and basioccipital arches, respectively. The distal end of the quadrate process ossifies as the **quadrate** bone. This forms a heavy support for the articulation of the lower jaw. The columella is a cartilage bone.

The Dermal Bones. *For this study a dried skull is used. It should be understood by the student that this preparation represents the chondrocranium and its ossifications, the cartilage bones, plus the dermal bones which have been left in place. Because of the drying, this preparation will not show well the cartilaginous parts and should be studied along with the balsam mount used above. In the following description all the bones of the skull are described in their relative positions; the dermal bones are indicated by bold-face type.*

The dorsal surface is covered by the following bones:

At the extreme cephalic margin of the cranium, are the two **premaxillary** bones each possessing an alveolar or tooth-bearing process extending caudo-laterad, and an ascending process extending dorso-caudad.

The **frontal** bones form the anterior portion of the cranial roof. They extend caudad partially overlapping the anterior portion of the succeeding bones, the **parietals**. These form the posterior portion of the roof of the cranium, the two meeting at the mid-line. Caudad they partly cover the otic capsules. The prootic, opisthotic and exoccipital bones are slightly visible from the

dorsal surface. Compare this region with that of the chondrocranium from which the dermal bones have been removed.

Extending cephalo-laterad from the opisthotic is a splintlike bone, the **squamosal**. Ventrally, it gives off the **opercular process** which articulates with the columella.

Beginning at the middle of the squamosal and extending laterad and cephalad along its mesal margin is the quadrate bone expanding distally to form the articulation for the lower jaw. What is its relation to the quadrate cartilage? Upon a complete skull, locate the quadrate cartilage.

Extending mesad and cephalad from the cephalic end of the quadrate is the **palatopterygoid** bone bearing several teeth on its cephalo-ventral surface. Between the anterior end of this bone and the angle between the two processes of the premaxillary is the **vomer**. The greater portion of this bone is visible from the ventral surface.

Nearly the entire ventral surface of the cranium is formed by the large **parasphenoid**. Note that a great part of the otic capsule is visible from the ventral surface. Locate the prootic, opisthotic and exoccipital bones.

Note again the fenestra ovalis filled by the platelike columella which is articulated with the opercular process of the squamosal bone. Locate the premaxillary, vomer, palatopterygoid and quadrate bones. Locate the site of the anteorbital process, the internasal plate and the trabeculoquadrate isthmus of the chondrocranium. The last is the cartilaginous part of the quadrate process which extends between the trabeculum and the quadrate bone.

In a study of the cranium of Necturus, it is essential that constant reference be made to a disarticulated skull. It is not sufficient to identify and locate the various bones in place. In addition one must be able to identify each bone when seen alone. Disarticulated skulls are furnished for this study. At the end of this study an identification quiz will be held covering all parts of the skull of Necturus.

Plate 6. Figure 7. Dorsal Aspect of the Skull of Necturus with Dermal Bones Removed on Right Side to Expose Entire Right Half of Chondrocranium.

Label completely and color dermal bones light yellow; cartilage bones light brown; cartilage light blue.

Plate 6. Figure 8. Ventral Aspect of the Skull of Necturus.

Label and color as in the preceding figure. Do not fail to add the color legend to the plate.

The Visceral Skeleton. Necturus belongs to that group of vertebrates, the Amphibia, which have affected certain structural changes that are to be correlated with the transition from an aquatic to a semiterrestrial mode of life. Not all amphibia have been equally successful in this respect; some are still entirely aquatic, others almost entirely terrestrial. All are physiologically aquatic. Necturus is entirely aquatic but, nevertheless, constitutes a striking example of the manner in which structures are remodeled for new services when they have become functionless in their original capacity.

Each of the seven visceral arches of the shark is represented in Necturus in a modified or reduced state. In the main, the modifications are to be associated with the change to a different mode of respiration. Certain of the modifications are in line with the general modifications elsewhere in the skeleton; *i.e.*, there is a tendency toward more or less complete replacement of the cartilage present by bone of both the dermal and cartilage types.

Arch 1. Mandibular Arch. This, as in the shark, is composed of a dorsal **pterygoquadrate** element and **Meckel's cartilage**. As in the neurocranium already studied, the cartilages of this arch become encased in dermal bones, in consequence of which, they are very much reduced.

In Necturus, the pterygoquadrate element persists as the quadrate process. As described above, this ossifies at its distal end to form the quadrate bone, which articulates with Meckel's cartilage of the lower jaw. Again carefully examine the relationships of the quadrate process. Note that, unlike the pterygoquadrate of the shark, it does not form the functional upper jaw. The premaxillary, vomer and palatopterygoid bones, already mentioned as a part of the skull, have replaced a great portion of this cartilage and constitute the functional upper jaw.

The ventral element, Meckel's cartilage, which alone formed the lower jaw of the shark, persists as a very complete cartilage

but is encased by three dermal bones; the **dentary**, the **angulare** and the **splénial**. The proximal end of Meckel's cartilage forms a rounded surface which articulates with the quadrate bone. Almost the whole ectal surface of the lower jaw is formed by the dentary which meets its fellow of the opposite side at the **symphysis**. The angulare is the next in size and forms two-thirds of the ental surface. A small portion of this bone appears on the caudo-ventral margin of the ectal surface. The splénial, the smallest of the three, appears as an oval scale on the ental surface of the lower jaw between the dentary and the angulare. *Note! The dried specimen does not show Meckel's cartilage distinctly. A lower jaw preserved in alcohol should be studied for the relations of this element.*

From the above study, it can be seen that the primitive cartilaginous parts functioning as upper and lower jaws in the shark have here been replaced by dermal bones functioning in their stead. For convenience, the primitive cartilaginous jaws may be called the **primary**, and the complex of dermal bones, which in higher vertebrates usurp their function, the **secondary jaws**.

The Teeth. Which of the bones in the upper and lower jaws bear teeth? About how many are present in each? How does the total number in *Necturus* compare with the number in the shark? Notice that here, as in the shark, the teeth are **homodont**. While the method of replacement is obviously not the same as in the shark, succession is continuous throughout life and is, therefore, the **polyphyodont** type. Notice the way in which the teeth are attached to the bones. When the teeth are fastened to the lateral side of the bone as in *Necturus*, the attachment is known as the **pleurodont** type.

Arches 2 to 5. In *Necturus* where internal gills are absent and the visceral arches are freed from their primitive support of the respiratory organs, parts of a number of the visceral arches combine to form a single structure called the **hypobranchial apparatus**. This serves to support the tongue and the ventral region immediately caudad of the tongue.

For the study of the hypobranchial apparatus, a balsam mount will be supplied. To understand the relation of the hypobranchial apparatus to the rest of the skeleton and to the other parts of the body, it will be necessary to study a demonstration specimen in which the arches have been exposed.

The **hyoid**, or **arch 2**, of the shark is represented in *Necturus* by the **columella** (hyomandibula of sharks) and the **hyoid proper**. The hyoid proper forms the anterior part of the hypobranchial apparatus and consists of two cartilages upon either side; the smaller more mesal element is the **hypohyal**, and the larger more lateral element, the **ceratohyal**.

At this time review the type of jaw suspension in the shark. Recall that in the shark the hyomandibula serves to suspend the jaw from the neurocranium and that this condition is called the **hystylic** type of jaw suspension. In *Necturus*, the primary jaws are replaced by secondary jaws of dermal bone. Associated with this change, a new type of jaw suspension has made its appearance. The pterygoquadrate is shortened and fused with the neurocranium, and the dermal bones which develop replacing the reduced pterygoquadrate fuse with the neurocranium. The lower jaw is suspended directly from the neurocranium by means of the shortened pterygoquadrate. This is called the **autostylic** type of jaw suspension.

As a result of this new type of jaw suspension, the hyomandibula is released from its suspensory function and becomes modified to serve in the capacity of a sound-transmitting organ. That is, the hyomandibula becomes the columella, the function of which is to transmit vibrations to the inner ear.

Arches 3 to 5 are those arches which guard and regulate the two gill slits and which serve as the supports of the external gills. In regard to the number of parts present, these arches are simpler in *Necturus* than in the shark. Movement of the gills in *Necturus* does not involve skeletal parts to the same extent as in the shark; consequently, the arches involved are much simplified.

On the median line, extending caudad from between the two hypohyals of the hyoid arch, is the **anterior basibranchial**. **Arch 3** extends caudo-laterad from the posterior end of the anterior basibranchial, and it comprises two cartilages on each side, a proximal **ceratobranchial** and a distal **epibranchial**. **Arch 4** also consists of two parts, **ceratobranchial** and **epibranchial**. The former is a small cartilage just caudad of the point of articulation of the ceratobranchial and epibranchial of arch 3. The epibranchial of arch 4 is a slender cartilage extending caudo-laterad of the ceratobranchial. **Arch 5** is composed of a single very slender **epibranchial** only, lying along the caudal

margin of the epibranchial of arch 4. Projecting caudad from the medial ends of the ceratobranchials of arch 3 is the slender **posterior basibranchial**. This element is partially ossified. What type of bone is this?

Since only three gills are present in *Necturus*, and these are attached to the distal ends of gill arches 3, 4 and 5, the remaining two arches are free to become vestigial or to be remodeled to function in a new capacity. **Arch 6** persists in a vestigial state as a single cartilage on each side embedded in the muscles of the throat region. **Arch 7** is represented by the **laryngeal cartilages**. These constitute a pair of cartilages lying one on either side of the glottis. They support this opening and protect the very short trachea. These will be demonstrated later when the respiratory system is studied.

Plate 7. Figure 9. Ectal and Ental Aspects of One-half of the Lower Jaw of *Necturus*.

Label completely and color dermal bones light yellow; cartilage light blue.

Plate 7. Figure 10. Ventral Aspect of the Hypobranchial Apparatus of *Necturus*.

Label completely and color cartilage light blue; cartilage bone light brown.

Plate 8. Figure 11. Diagram of the Lateral Aspect of the Cranium and Visceral Arches of *Necturus*.

Label completely and color to show homologies with the visceral arches of the shark. Do not color to indicate dermal and cartilage bones. Use the same color scheme as in Plate 2, Fig. 2.

THE TRUE BONY SKULL

The skull of the adult amniote is composed almost entirely of bone, the cartilaginous cranium having been lost or replaced during embryonic development. The chondrocranium, during its development, is confined mainly to the ventral surface of the brain. As in the skull just studied, the early development of investing bones prevents the formation of a complete chondrocranium. In most amniotes, however, it is more complete than that found in *Necturus*. The para- and prechordal bars spread and fuse across the mid-line, low side walls are formed, and in the occipital region a supraoccipital arch is formed. The

COMPARATIVE SUMMARY FOR THE SKULL OF THE SHARK AND NECTURUS

	Shark	Necturus
Neurocranium Chondrocranium	Complete except anterior fontanel Sense capsule, except optic, attached Entirely cartilaginous	Very much reduced—trabeculae with ethmoid plate, nasal capsules, anteorbital processes remain anteriorly; otic capsules, parachordal bars, supra- and basioccipital arches, posteriorly Otic capsule, only, attached Partially ossified: In otic capsule; prootic and opisthotic bones In occipital region; exoccipitals
Dermal bones	None	Form roof, side walls and venter of brain case: frontals, parietals, squamosals and parasphenoid
Splanchnocranium 1. Mandibular arch a. Pterygoquadrate	Complete—halves meet anteriorly Entirely cartilaginous Primary-jaw functional	Reduced to quadrate processes attached to neurocranium Partially ossified: quadrate bones Secondary jaw formed by premaxillaries, vomers and palatopterygoids functional
b. Meckel's cartilage	Complete—halves meet anteriorly Primary jaw	Almost complete but encased in dermal bones Secondary jaw composed of dentary, angular and splenial
c. Teeth	Hyostylic jaw suspension Homodont dentition Polyphyodont replacement Aerodont attachment	Autoalylic jaw suspension Homodont dentition Polyphyodont replacement Pleurodont attachment
2. Hyoid arch	Hyomandibula Ceratohyal Basihyal Bears one-half gill	Columella (ossified) Ceratohyal Hypohyals (2) Gill function lost
3 to 7. Gill arches	Pharyngobranchials (6 and 7 fused) Epibranchials (except arch 7) Ceratobranchials Hypobranchials (except 3 and 7)	Lacking Epibranchials 3, 4 and 5 present Ceratobranchials 3 and 4 present Lacking
Other parts	Anterior basibranchial Posterior basibranchial	Arch 6, vestigial Arch 7, laryngeal cartilages Anterior basibranchial Posterior basibranchial (partially ossified)

supraoccipital arch is all that remains of the roof of the chondrocranium. Around the ear and nasal organs, cartilaginous capsules develop and fuse with other parts of the chondrocranium.

Since cartilage bone develops within cartilage, it is easy to understand why, in the amniote, these are confined mainly to the ventral and caudal portions of the skull. Their position in the skull is predetermined by the presence of cartilage in earlier stages of development. Dermal bones form the greater portion of the side walls and roof of the skull.

In the following study, the skull of the domestic cat is used to illustrate the bony stage in the phylogeny of the skull.

The Skull of the Cat.

For this study a whole and a disarticulated skull will be furnished. Make constant use of the disarticulated skull. It is not sufficient to be able to identify the bones in place. Their exact boundaries and relationships may be learned only by supplementing a study of the whole skull with one of the disarticulated elements.

The skull of the cat may be considered as divided into **cranial** and **facial** divisions. The bones belonging to the former bound the cranial cavity and form the brain case, the bones of the latter support the face. The bones of the facial division are, for the most part, those which are first morphologically associated with the splanchnocranium but which, later, fuse with, and become a part of, the neurocranium. This association, already seen in *Necturus*, becomes much closer in the cat.

Dorsal Aspect of the Skull. In dorsal view the skull presents a smooth convex surface, narrow anteriorly and broadening toward its caudal end. Projecting laterally are the two **zygomatic arches**. The following bones are visible in this view.

The **premaxillaries** are the most cephalic bones of the dorsal surface and form the extreme cephalic portion of the upper jaw. These bones bear the six small incisor teeth and form the ventral and lateral margins of the nasal opening. Dorsally they articulate with the **nasals**, two long, narrow bones extending caudad from the dorsal border of the nasal opening to a point between the orbits.

The **maxillaries** articulate with the nasals and premaxillaries. The **frontal process** of each of these bones extends dorso-caudad as far as the caudal ends of the nasals. These bones bear all the

teeth of the upper jaw except those borne by the premaxillaries. The body of the maxillary is seen, in the dorsal aspect, to form a large part of the floor of the orbit.

The **frontals** lie between the orbits. They articulate with each other on the mid-line, and anteriorly, with the frontal processes of the maxillaries and the nasals. Laterad, each bears a strong **postorbital process**.

The **parietals** form the roof of the caudal portion of the brain cavity. They articulate cephalad with the frontals.

The **interparietal** is a single triangular bone on the mid-line between the diverging caudal margins of the parietals. This bone may be fused with those surrounding it. This happens quite early in the cat. Of the mid-dorsal line this bone bears the major portion of the **sagittal crest**. This crest may not be well developed in a small skull since it becomes prominent and increases in size with the age of the animal.

The **lachrymal** bone is a small thin scale of bone in the cephalomesal margin of the orbit. It is wedged in between the maxillary laterally and the frontal mesally. Its anterior margin is notched obliquely by a foramen, the beginning of the **nasolachrymal canal**. The inner surface of this bone looks into the nasal cavity.

The horizontal plate of the **palatine** bone forms a part of the floor of the orbit. It is bounded laterally by the maxillary, anteriorly by the lachrymal and mesally by the frontal. The greater portion of this bone is not visible in this aspect and will be described later.

The **zygomatic arch** is made up of the **malar** bone and the **zygomatic process** of the **temporal** bone. It will be found from subsequent study that the temporal bone is composed of four elements which are separate in the embryo but coossified in the adult. It is the **squamosal** portion of this bone that is visible in the dorsal aspect. Mesally the squamosal is bounded by the parietal. The malar bone is bounded anteriorly by the maxillary and posteriorly by the zygomatic process of the squamous portion of the temporal bone. Dorsally it bears a **frontal process** which almost meets the postorbital process of the frontal bone. Occasionally in very old individuals, these two processes meet and fuse.

The **supraoccipital** bone forms the caudal margin of the dorsal aspect of the skull. A small portion of the **mastoid** bone is also

visible in this aspect. These two bones are more completely described below.

Caudal Aspect of the Skull. The caudal surface is formed largely by the occipital bone which surrounds the **foramen magnum**. Examine the skull of a kitten and note that it is composed of a dorsal element, the **supraoccipital**, two lateral **exoccipitals** and a ventral **basioccipital**. They fuse early in postnatal life, thus forming the single occipital bone. On either side of the foramen magnum, the occipital bone bears the **occipital condyles** for articulation with the first vertebra. By a study of the kitten's skull, determine to what extent the exoccipitals and basioccipital are concerned with the formation of the condyles.

The margin of the occipital bounding the parietal bones is elevated to form a crescentic ridge called the **lambdoidal crest**. Like the sagittal crest, this may not be very prominent in the skull of a young animal.

The caudal aspect of the skull also presents two rounded ventral projections, the **auditory** or **tympanic bullae**. Each bulla is formed by a **tympanic** bone. This is one of the four which, in the adult, fuse to form the temporal bone.

Laterad of the occipital condyle and separated from it by a deep groove is a blunt projection, the **jugular process**, extending ventrad for a short distance over the caudal portion of the tympanic bulla.

The **mastoid** bone appears in this aspect as roughly triangular in outline, wedged in between the exoccipital mesally and the squamosal laterally. Its ventral margin projects slightly over the auditory bulla as the **mastoid process**. The outline of this bone is not very distinct. It is another of the four components which early fuse to form the temporal bone. *Carefully study the disarticulated skull to determine its exact boundaries.*

Just ventrad of the mastoid process is a small pit in the side of the auditory bulla, the **tympanohyal fossa**. It is at this point that the anterior horn of the hyoid articulates with the skull.

Ventral Aspect of the Skull. The ventral surface of the skull is much more complicated than the aspects described above. Posteriorly is seen the **foramen magnum**. Cephalad of the occipital condyles are the rounded auditory bullae. Cephalad of these, the skull narrows abruptly between the orbits and then

broadens into that portion forming the roof of the mouth. The zygomatic arch is also apparent in this view.

Of the bones which appear in the ventral aspect, some have already been discussed and will not be treated further. These are to be included, however, when labeling the drawing of the ventral surface and should be reviewed from this aspect.

The basioccipital, on the mid-line, extends cephalad from the foramen magnum to a level between the cephalic margins of the auditory bullae.

Cephalad of the basioccipital, forming the middle portion of the ventral surface of the skull, is the sphenoidal complex of bones. This is composed of unpaired **basisphenoid** and **presphenoid** and paired **alisphenoids**, **orbitosphenoids** and **pterygoids**. These bones are all separate in the kitten but fuse more or less completely in the adult.

The basisphenoid is single and articulates posteriorly with the basioccipital. Extending latero-dorsad from this element is the alisphenoid. The suture between these two bones is lost very early. At its dorsal extremity, the alisphenoid articulates with the cephalo-lateral margin of the parietal.

The presphenoid lies on the mid-ventral line just cephalad of the basisphenoid. The suture between these two bones does not disappear until late in life. Projecting latero-dorsad from the presphenoid on each side, is the orbitosphenoid. This is pierced by the large **optic foramen** and takes part in the formation of the orbit. The suture between pre- and orbitosphenoid disappears early. In the whole skull, this suture is partially covered by the pterygoid bone. The pterygoid fuses early at its posterior margin with the alisphenoid. Each pterygoid bone terminates ventrally in a sharp **hamular process**. *Important! Because of overlapping and fusion of bones, it is necessary to make a very careful study of the disarticulated skull in order to understand this particular region.*

The palatine bones form the posterior portion of the roof of the mouth. The anterior portion of each of these bones is broad and platelike, the posterior part, narrowing abruptly, articulates with the pterygoid. The suture between palatine and pterygoid bones disappears in the adult cat. The palatine overlaps the anterior portion of the suture between the pre- and orbitosphenoid bones.

The maxillaries are cephalad of the palatines in the roof of the mouth. At their lateral margins, these bones bear the canine, premolar and molar teeth. The bones of opposite sides meet cephalad, but diverge caudad to enclose the palatal plates of the palatine bones.

The premaxillaries articulate posteriorly with the maxillaries and form the anterior portion of the roof of the mouth. To either side of the mid-line between the premaxillary and maxillary bones are two large openings, the **anterior palatine foramina**.

The bony plate formed by the premaxillary, maxillary and palatine bones in the roof of the mouth is called the **hard palate**. Notice that this extends caudad about as far as the caudal margin of the teeth.

On the mid-line at the caudal margin of the hard palate and dorsad to it, is a large opening into the nasal cavity. Look forward into this opening. Anteriorly it is divided by the **vomer** bone into two passages, the **posterior nares** or **choanae**. Posteriorly, the vomer articulates with the presphenoid, anteriorly with the maxillaries. The relationships here may be determined best by a careful study of the disarticulated skull.

All the components of the zygomatic arch which are visible from the ventral side, have been described above. Review them again from this aspect.

Cephalic Aspect of the Skull. This aspect presents no new structures except those which may be seen through the nares lying in the nasal cavity.

Extending dorsad from the vomer to the mid-dorsal line is the thin sheetlike **mesethmoid** separating the nasal cavity into two separate halves. In the natural condition, this bone is continuous cephalad with a cartilaginous plate which completes the separation of the nasal cavity all the way to the tip of the nose. This cartilage represents the only part of the chondrocranium that persists in the adult cat.

To either side of the mesethmoid, filling the nasal cavity, are the complicated scroll-like **lateral ethmoid** bones. These support the extensive epithelial lining of the nasal chamber. *Important! The ethmoid bones are very fragile and may be partially destroyed in your study specimens. Consult the demonstration specimens if necessary.*

Lateral Aspect of the Skull. This aspect of the skull may be resolved into three portions; temporal, orbital and facial divisions.

The temporal bone forms the caudal division. It forms the side and a part of the base of the lateral wall of the cranial cavity. It also houses the internal organs of hearing. The temporal bone is composed of four parts, all separate in the skull of the young kitten but fused in the adult. Some of these have already been seen but may now be reviewed and studied in more detail. They are: the squamosal, the expanded portion to which the zygomatic arch is attached; the mastoid, lying between the caudal border of the squamosal and the exoccipital element of the occipital bone; the tympanic which forms the auditory bulla; and the **petrous** which contains the inner ear.

On the ventral side of the zygomatic process, near its base, is the **mandibular fossa** for the articulation of the lower jaw. Compare the articulation of the upper and lower jaw of the cat with that in *Necturus*, and note the different bones involved.

The auditory bulla is pierced laterally by an opening, the **external auditory meatus**. Around this opening, the tympanic bone is thickened and elevated to form the **tympanic ring**. The cartilage of the external ear is attached to the lateral side of this ring, the tympanic membrane or eardrum, to the inner side.

The cavity within the auditory bulla is almost completely divided into two chambers by a bony septum, seen best in the disarticulated skull. The outer of the two chambers thus formed is the true tympanic portion of the auditory bulla or **middle ear** and contains the auditory ossicles to be described below in the discussion of the visceral skeleton.

At the anterior end of the auditory bulla just mesad of the tympanic ring, there is a groove in the dorsal margin of the tympanic bone which, fitting against the ventral side of the alisphenoid, forms a passage into the cavity of the middle ear. This is the **Eustachian tube** by means of which the cavity of the middle ear connects with the pharynx.

The petrous bone is covered by the other three parts of the temporal bone and is not visible in an external view. It may be seen, however, through the external auditory meatus, but for exact relations it must be studied in the disarticulated skull. In the adult skull, it is very firmly fused with the mastoid bone.

34 LABORATORY STUDIES IN COMPARATIVE ANATOMY

It lies anterior to the mastoid bone. On its ventral surface, it has a prominent central swelling which projects into the cavities of the auditory bulla.

Two openings pierce the petrous bone and connect middle and inner ear cavities. One, the larger and more ventral of the two, faces almost caudad. It is nearly circular and is called the **fenestra rotunda** or **fenestra cochleae**. In life it is closed by a membrane. The dorsal one faces laterad and is slightly elliptical in shape. This is the **fenestra ovalis** or **fenestra vestibuli** into which the plate of the stapes fits. The stapes will be discussed later under the visceral skeleton.

From this aspect, review the bones forming the orbital and facial divisions of the skull. They have all been treated above in the description of the dorsal and ventral aspects.

Classification of the Bones of the Skull. In the directions given above, dermal and cartilage bones have been discussed together. It should be remembered that these two types of bones have distinct developmental origins even though, in the adult skull, they become compactly interrelated and, in some cases, actually fuse with one another.

Below are listed by regions the ossifications of the chondrocranium which occur in the cat. These are the cartilage or replacement bones, and bones not appearing in this list are dermal bones.

Occipital region

Supraoccipital
Exoccipitals (2)
Basioccipital

} fuse into a single occipital bone

Otic region

Mastoid—represents opisthotic of lower forms

Petrous—represents prootic of lower forms

Orbitotemporal region

Basisphenoid

Presphenoid

Alisphenoids (2)

Orbitosphenoids (2)

Ethmoid region

Mesethmoid

Lateral ethmoids (2)

Plate 9. Figure 12. Ventral Aspect of the Skull of the Cat.

Label completely and color dermal bones light yellow; cartilage bones light brown.

Plate 10. Figure 13. Dorsal Aspect of the Skull of the Cat.
Label completely and color as in the preceding figure.

The Visceral Skeleton. Since gills are never functional in amniotes, the visceral arches which develop to support these structures in aquatic vertebrates are free to be modified to serve new functions. It will be seen in the following study that these changes, initiated in the amphibia, have become quite complete in the cat.

Arch 1. Mandibular Arch. In the cat the upper jaw is composed entirely of dermal bones. Only the premaxillary and maxillary bones bear teeth. Palatine, pterygoid and vomer bones, which in *Necturus* were seen to form a part of the margin of the jaw, have moved mesad of the margin of the jaw in the cat. Notice the part which the bones primitively associated with the pterygoquadrate cartilage now play in the formation of the hard palate.

The lower jaw is composed of a single bone, the **mandible** or **dentary** bone. It is formed by two halves immovably united at the **symphysis**. Each half consists of a horizontal and vertical ramus. The horizontal ramus bears the teeth. The vertical ramus is divided into two portions; a larger, more dorsal **coronoid process**, and a smaller, more ventral **condyloid process**. It is through the condyloid process that the mandible articulates with the squamosal portion of the temporal bone at the mandibular fossa. The ventral border of the mandible is prolonged slightly caudad as the **angular process**.

The articulation between dentary and squamosal bones seen here is a state peculiar to mammals. As a result of this new articulation, the jaw is morphologically shorter than in lower forms. Recall that in *Necturus* the articulation between upper and lower jaw was effected by means of the pterygoquadrate element and Meckel's cartilage. Owing to this new articulation the primitive jaw elements disappear as such in the cat.

The pterygoquadrate element of the primitive arch becomes the incus. The proximal end of Meckel's cartilage ossifies to form the articular bone which is taken into the middle ear where it becomes another of the auditory ossicles, the malleus.

The Auditory Ossicles. *Study the auditory ossicles in a special preparation taken from a dried skull.*

These are three bones which constitute the sound transmitting apparatus of the middle ear. They extend as an irregular chain from the tympanic membrane to the fenestra vestibuli of the petrous bone. The **malleus** consists of a slender handlelike portion which attaches to the tympanic membrane and a rounded head which articulates with the **incus**, the middle of the three ear bones. The incus possesses a body and two projecting fangs, one of which articulates with the **stapes**. This is the innermost of the three ear bones and has the form of a stirrup. The base of the stapes fits into the fenestra vestibuli (fenestra ovalis).

The stapes of the cat represents the columella of *Necturus* which in turn was derived from the hyomandibula of the shark. It can be seen, then, that the components of two arches contribute to the auditory ossicles. The stapes is a component of the second visceral arch, treated here rather than later with the hyoid arch.

The Teeth. The teeth in the cat, unlike those in the shark and *Necturus*, are not all of the same general form. They are differentiated into **incisors** for cutting, **canines** for tearing and **premolars** and **molars** for grinding and crunching. When thus differentiated, the dentition is called **heterodont**.

In the cat, the teeth are not replaced continuously throughout life but are restricted to two sets, a temporary or deciduous set called the **milk dentition**, and a second set, the **permanent dentition**. When the dentition is restricted to two sets, the succession is called **diphyodont**.

In animals with heterodont dentition, the number of the teeth in each of the categories is constant for the species and may be expressed as the **dental formula** of the animal. In the cat, the number of teeth in the milk and permanent dentitions is not the same. There are twenty-six in the milk set and thirty in the permanent set. In the milk dentition of the cat, all teeth caudad of the canines are called deciduous molars. In the permanent set these are replaced by the premolars. The permanent molars have no predecessors in the milk dentition.

The double dentition of the cat may be expressed by the following formulas, in which *d* stands for deciduous, *i*, for incisor, *c*, for canine, *pm*, for premolar and *m*, for molar. The numerator of the fraction expresses the number of upper teeth, and the

denominator, the number of lower teeth, of any one kind. The teeth are numbered from the middle point of the jaw backward. Only the teeth of one side are expressed in the formulas. Milk dentition:

$$di^{3/3}, dc^{1/1}, dm^{3/2}.$$

Permanent dentition:

$$i^{3/3}, c^{1/1}, pm^{3/2}, m^{1/1}.$$

The attachment of the tooth to the jaw in the cat differs from any that has been observed previously. The tooth is cemented in a bony socket. This is the **thecodont** type of attachment.

Arches 2 and 3. The Hyoid Apparatus. In the cat, as in the two forms previously studied, the hyoid arch forms the support of the tongue. The hyoid of the cat is of bone and consists of a basal transverse bar called the **body** (basihyal) and two cornua attached to the body. The **cranial cornu** is the longer of the two, and arising from the end of the body, it extends first laterad and then caudo-dorsad, meeting the skull at the tympanohyal fossa. The cranial cornu is composed of four elements. Named from the one articulating with the body, they are: (1) the **ceratohyal**; (2) the **epihyal**; (3) the **stylohyal**; and (4) the **tympanohyal**.

The **caudal cornu** arises from the body just caudad of the cranial cornu and projects caudad. It consists of a single element, the **thyrohyal** which articulates with the larynx described below.

The thyrohyal is a modification of the third arch as represented in the shark and Necturus. The second arch forms the remainder of the hyoid apparatus plus the stapes as described above.

Arches 4 to 7. The Larynx. The larynx is the expanded upper portion of the air passage into the lungs and has for its function the production of voice. It consists of three unpaired and one set of paired cartilages.

The most anterior cartilage is the **epiglottis** which bends back and closes the glottis when food is swallowed. The next caudad is the **thyroid** which partially conceals the other elements and which articulates with the caudal cornu of the hyoid. This is a U-shaped cartilage, the open side of which points dorsad.

Caudad of the thyroid is the cricoid cartilage, to the caudal border of which the first tracheal ring is attached. Articulated to the anterior margin of the cricoid cartilage, and located one on either side of the glottis are the paired arytenoid cartilages. The vocal cords are attached to the apices of the two arytenoid cartilages.

The larynx represents modifications of the four posterior visceral arches. The thyroid cartilage represents arches 4 and 5 which have fused to form the single cartilage of the adult. Arch 6 is represented by the epiglottis while arch 7 is represented by the cricoid, arytenoids and the cephalic tracheal rings.

For review, complete the table given on page 27 to include the skull of the cat. Time will not be taken during the laboratory period for this work. Each student should do this individually outside of the laboratory.

Plate 11. Figure 14. Lateral Aspect of the Skull and Larynx of the Cat.

In this figure carefully draw in the sutures between bones. They have purposely been omitted. Label completely and color to show the homology of the visceral arches as in Plate 2, Fig. 2.

THE VERTEBRAL COLUMN, RIBS AND STERNUM

In the early chordates, the long axis of the body was supported by the **notochord**. This condition is seen in *Amphioxus* where the notochord is the sole axial support of the animal. In vertebrates, the notochord appears early during ontogeny but is later replaced, either in part or completely, by cartilaginous or bony vertebrae. From the subsequent studies, however, it will be seen that this replacement is a gradual one. In the lowest class of vertebrates, the Cyclostomata, the notochord remains throughout life as the chief axial support, even though structures which may be interpreted as primitive vertebrae are present. In the highest class of vertebrates, the Mammalia, the notochord, although present during ontogeny, disappears entirely as a supporting structure in the adult. In all vertebrates, the notochord forms the foundation around or upon which the segmented vertebral column is formed.

A knowledge of the development of the vertebral column is necessary in order to clearly understand the definitive structure.

Early Development of the Vertebral Column. The vertebral column is formed from the mesenchyme contributed by the **sclerotomes** of the paraxial mesoderm. Recall that the paraxial mesoderm is divided into somites. The number of vertebrae correspond closely to the number of somites in the trunk region, but a vertebra is not formed by the mesenchyme from the sclerotomes of a single pair of somites.

In most animals, the sclerotome is divided transversely into cephalic and caudal parts by a cleft, the **fissure of von Ebner**. The mesenchyme of that part of the sclerotome anterior to the fissure is usually less dense than that caudad of the fissure, and these are designated, respectively, as **cranial** and **caudal part-**

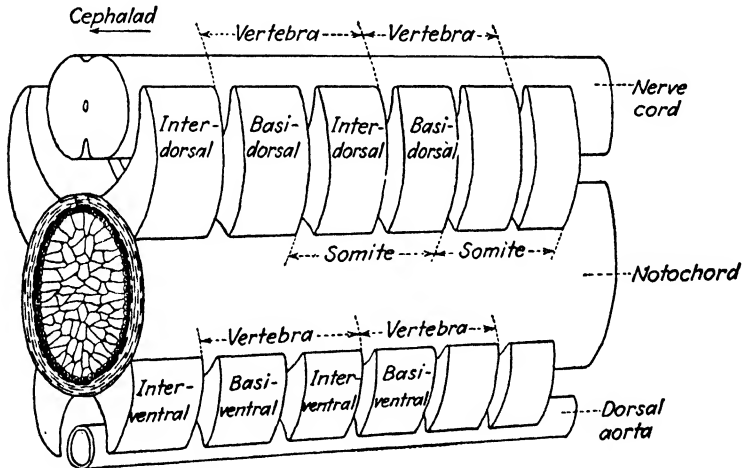


FIG. 1.—Diagram to illustrate the arrangement of the arcualia in the vertebral column of vertebrates showing their relations in the definitive vertebra and to the somite.

sclerotomes. The fissure of von Ebner marks the future articulation between contiguous vertebrae. It can be seen, then, that a definitive vertebra is formed by a fusion of the caudal part-sclerotomes of one somite with the cranial part-sclerotomes of the next somite caudad. Since the definitive muscle segments correspond with the somites, it results that the definitive vertebra lies between two muscle segments rather than within a single muscle segment.

The division of the sclerotome described above occurs in most animals before the sclerotome breaks away from the remainder

of the somite. The mesenchyme of the cranial and caudal part-scleretomes next breaks away from the somites and settles around the notochord and neural tube. The mesenchyme forms a continuous sheath around the notochord and neural tube, but in many animals, the cranial and caudal part-scleretomes retain their identity and chondrify as distinct cartilages, called **arcualia**.

The arcualia are named as follows: The posterior part-scleretomes give rise to a dorsal pair, a single cartilage forming on each side of the neural tube, and a ventral pair beneath the notochord, one on each side of the dorsal aorta. These form the major portion of the definitive vertebra and are called, respectively, the **basidorsals** and **basiventrals**. Similarly, the anterior part-scleretomes give rise to a dorsal pair of **interdorsals** and a ventral pair of **interventrals**.

A careful study of Fig. 1 will aid in visualizing the above description.

In the lower vertebrates, all the arcualia usually appear and remain more or less separate throughout life; in the higher vertebrates, some arcualia may fail to form and all those which do appear fuse into a single piece. To understand completely the structure of the vertebral column, then, it is necessary to trace the fate of each of the arcualia and to determine the part that each plays in the formation of the definitive vertebra.

Such a study will show also that the vertebral column, like the skull, at first cartilaginous, completely ossifies later. It differs from the skull, however, in that no dermal bones become associated with it. The bony vertebra is entirely of cartilage or replacement bone.

In the replacement of the notochord by the segmented vertebral column, flexibility, a necessary feature of successful axial support, is obtained in quite a different manner. The notochord is uniformly flexible throughout its length; the vertebral column, composed as it is of a series of solid masses, is given flexibility as a whole by the joints between successive vertebrae.

The Vertebral Column and Ribs of the Shark.

Functions of the Vertebral Column. In addition to its main function as (1) the axial support for the trunk and tail regions, the vertebral column functions also in the shark (2) to support the mesal fins, (3) for the attachment of the segmental muscles,

(4) for protection of the nerve cord and (5) for protection of the caudal aorta and vein in the tail region.

Parts of a Vertebra. The chief divisions of a vertebra are: the **body** or **centrum** which surrounds and replaces the notochord; the **neural arch** which surrounds and protects the nerve cord; and in the tail region, the **hemal arch** which surrounds and protects the blood vessels which pass along the ventral side of the vertebral centra. In addition to these, the vertebra may give off lateral **transverse processes** for the articulation of the ribs with the vertebrae.

Regional Differentiation. The vertebral column of the shark exhibits very little regional differentiation. By this it is meant that the vertebrae of one region do not differ markedly from those of any other region. The animal is buoyed up by the water in which it lives so that the forces acting upon all parts of the vertebral column are nearly the same. The differentiation of the vertebral column into **trunk** and **caudal** or tail regions is determined wholly by the presence or absence of the body cavity. No propelling force is applied to the vertebral column through either the pectoral or pelvic fins, consequently, no modifications are to be detected at these levels.

From the same shark that was used for the study of the skull, remove that section of the vertebral column included between the posterior margins of the first and second dorsal fins. To do this, first remove and preserve the pelvic girdle and fin. With the fingers, locate the barlike pelvic girdle extending across the ventral body wall. This is not connected with the vertebral column in the shark and may be removed without cutting through any part of the skeleton. The section of the vertebral column removed will include a number of typical trunk vertebrae, a number of typical tail vertebrae and also those vertebrae which show the transition from one type to the other. Remove the muscles and connective tissue from this section of the vertebral column. Do this carefully and thoroughly so that the divisions of each vertebra can be plainly seen.

Caudal Vertebrae. The caudal vertebrae in the shark are characterized by the possession of complete **hemal arches** which surround the blood vessels ventrad of the centra.

Viewing a caudal vertebra in cross section, or from its end, note the circular **centrum** located between the dorsal **neural arch** and the ventral hemal arch. Note that the centrum surrounds

the notochord which appears as a semigelatinous mass. Detach a single vertebra and remove the notochord. What is the shape of the cavity of the centrum? This is the **amphicoelous** type of vertebra, so named because the centrum is cup-shaped at each end.

Lime salts are often deposited in cartilage. In effect this provides a structure much like bone, but not to be considered as such since it differs developmentally from true bone. The centra of the vertebrae of the shark have become extensively calcified. *Examine the dried specimens of vertebrae taken from large sharks.* In which part of the centrum are the calcium deposits?

Note the partition dividing the hemal arch into a dorsal and ventral canal. The dorsal one contains the dorsal aorta, and the ventral, the caudal vein.

Viewed laterally, it will be seen that the neural arch is composed of a series of alternating plates. The one above and attached to the centrum is the **neural plate**. The cartilages intercalated between the neural plates are called the **intercalary plates**. Note that the intercalary plates are not connected with the centrum but that those of opposite sides are continuous over the mid-dorsal line. Are the neural plates of opposite sides continuous? With a needle or the point of the knife dissect out two consecutive intercalary plates. Determine accurately the relation between neural and intercalary plates.

Note the nerve foramina piercing the neural and intercalary plates. That piercing the intercalary plate is for the dorsal or **sensory** branch of the spinal nerve and that piercing the neural plate, for the ventral or **motor** branch.

Note also that the hemal arch is composed of **hemal plates**. Compare these with the plates forming the neural arch.

Are intercalary plates present in the hemal arch? *Make a median sagittal section of several consecutive vertebrae. Remove the nerve cord from the neural arch and identify all parts.*

Trunk Vertebrae. The trunk vertebrae are characterized by the absence of a complete hemal arch. Follow the hemal plates forward from the tail region and notice that, in the trunk region, they shorten and form blunt **transverse processes**. In line with the transverse processes, wedged in between successive trunk vertebrae, are small triangular elements, the **ventral intercalary plates**. These cartilages are quite small and may have been

removed in cleaning the vertebral column. If so, locate them in an undissected region of the vertebral column. Trace this element toward the tail and notice that it takes no part in the formation of the hemal arch.

In the trunk vertebrae, locate the centrum, neural arch, dorsal intercalary plates and neural plates. Compare these with the same structures in the tail region. *Make sagittal sections of the trunk vertebrae as well as transverse sections at various levels and identify all parts.*

Ribs. In the trunk region, short cartilaginous ribs articulate with the transverse processes of the vertebrae. Dissect out several of them and notice that they follow the connective tissue septa between muscle segments.

The ribs of the shark are of no functional importance. Being so small and short, and of cartilage, they offer little or no support or protection to other parts.

Development of the Vertebrae. From the description of the early development of the vertebral column, it can be seen that the neural and hemal arches are the first parts of the vertebra to appear and that the centrum appears later. The arcualia, at first, merely rest upon the sheath of the notochord. The centrum is not formed in the same manner in all groups of vertebrates. In the shark, cartilaginous cells from the bases of the basidorsal and basiventral arcualia pierce the primary sheath of the notochord and migrate into the thick, fibrous secondary sheath. These cells then form a cartilaginous centrum within the fibrous sheath of the notochord. Such vertebrae, in which the fibrous sheath of the notochord forms a part of the centrum, are called **chordacentrous** vertebrae.

The interdorsals and interventrals play no part in the formation of the centrum, but form, respectively, the dorsal and ventral intercalary plates.

Although in the shark no fusion occurs between the basal and intercalary elements, the relationship between these is indicated by the spinal nerves. Each spinal nerve has two roots, a dorsal sensory root and a ventral motor root. As seen above, the intercalary plates are pierced by the foramina for the sensory roots, and the neural plates, by those for the motor roots. The motor nerve piercing a neural plate unites with a sensory nerve piercing the intercalary plate caudad to form the segmental

nerve. Thus a complete vertebra in the shark is to be thought of as comprising the centrum with its arches plus the intercalary elements immediately following.

Plate 12. Figure 15. Diagrams of the Tail Vertebrae of the Shark Showing :

- a. End View of a Section Taken between Vertebrae.
- b. Lateral Aspect of Two Vertebrae.
- c. Mid-sagittal Aspect of Two Vertebrae.
- d. End View of a Cross Section Taken through the Center of a Vertebra.

Label completely.

Plate 13. Figure 16. Diagrams of the Trunk Vertebrae of the Shark Showing the Same Aspects as in Fig. 15.

Label completely.

The Vertebral Column and Ribs of Necturus.

A prepared specimen of the vertebral column of Necturus will be provided for this study. Also consult the demonstration specimens provided for the purpose.

Regional Differentiation. The individual vertebrae of the vertebral column of Necturus exhibit little more differentiation than do those of the shark. Four regions are to be recognized, however. Naming from the anterior end they are the **cervical, trunk, sacral** and **caudal**.

The trunk and tail vertebrae of Necturus, as in the shark, may be distinguished by the presence or absence of the hemal arch.

Independent movement of the head is a distinct advantage, if not a necessity, in terrestrial vertebrates in which most stimuli are received by major sense organs located on the head and not by a lateral line system of sense organs extending the length of the body. It is to be understood that Necturus is entirely aquatic, but in common with other members of the group to which it belongs, some of which are terrestrial, the first vertebra has been specially modified to articulate with the skull in such a way that more movement between skull and vertebral column is possible than in fish forms.

Since Necturus is aquatic, the limbs which have replaced the fins are not important locomotor organs. Because they are used relatively little in locomotion, they are too small to produce any

marked effect upon the vertebral column. The most noticeable difference from the condition seen in fishes is the attachment of the pelvic girdle to a vertebra by means of a pair of specialized ribs. As the posterior limbs are the chief locomotor organs when a terrestrial animal progresses over the substratum, this connection results in a more effective application of locomotor force to the vertebral column. Owing, however, to the fact that no great amount of force is exerted by the hind legs in *Necturus*, this region is not greatly strengthened or modified, and only a single vertebra is involved.

The vertebral column of *Necturus* differs structurally from that of the shark in its complete ossification. It also possesses accessory articular processes, called **zygapophyses**, which are not present in the shark. The transverse processes, simple structures in the shark, are much more complicated in *Necturus*.

A Typical Trunk Vertebra. The following table shows in synoptic form the parts of a trunk vertebra:

Centrum (amphicoelous type)

Anterior and posterior concavities

Neural arch

Neural plate

Anterior and posterior zygapophyses

Neural spine

Transverse process

Diapophysis—articulating with dorsal head of rib

Parapophysis—articulation with ventral head of rib

Vertical lamina—between diapophysis and parapophysis

Horizontal lamina—between parapophysis and centrum

Ventral foramen

Anterior vertebral fossa

Posterior vertebral fossa

The **centrum** is in the form of a slender hourglass, its ends marked by very deep cup-shaped excavations, and is, therefore, of the **amphicoelous** type. In the living animal, these excavations are filled by the **notochord**. Is the notochord continuous or restricted to the intervertebral spaces?

The **neural arch** is somewhat flattened to form a **neural plate** over the dorsal side of the neural tube. On the mid-line projecting caudad from the neural plate is the **neural spine**. Anteriorly, the neural plate bears the two **anterior zygapophyses** which articulate with the **posterior zygapophyses** of the preceding

vertebra. Carefully work out the details of the articulation between vertebrae.

The **transverse process** projects laterad and caudad from the vertebra. It consists essentially of two irregular bony masses, one dorsad, the **diapophysis**, arising from the neural arch, and the other, the **parapophysis**, ventrad, arising from the centrum. The parapophysis presents distally a deep socket, the **pleurapophysial socket**, which contains the **pleurapophysial cartilage** described below. The two divisions of the transverse process possess two flattened laminae, of which one, the **vertical lamina**, is vertical and dorsal connecting the two divisions of the transverse process, the other, the **horizontal lamina**, is ventral and horizontal. The latter is applied to the ventral side of the parapophysis and spreads out proximally over nearly the entire length of the centrum with which it is fused. This lamina is perforated by the **ventral foramen**, situated immediately posterior to the parapophysis and transmitting the collateral vertebral blood vessels. As the vertical lamina meets the horizontal one almost at right angles, they form with the sides of the centrum two fossae, the **anterior and posterior vertebral fossae**.

The Sacral Vertebra. The sacrum of *Necturus* consists of a single vertebra. It is not markedly different from the vertebrae immediately in front or behind, but may be distinguished from the others by the fact that a pleurapophysial socket is present in the ends of both diapophysis and parapophysis. Locate this vertebra and designate by number its position in the vertebral column.

The Caudal Vertebrae. All those vertebrae caudad of the sacrum are usually loosely considered as caudal vertebrae. Note, however, that the **hemal arch** is not present until the third or fourth vertebra caudad of the sacral vertebra. Only those vertebrae which possess a hemal arch are true caudal vertebrae; those lacking the hemal arch belong to the trunk region. In a cleared demonstration specimen of *Necturus*, note that the body cavity extends caudad as far as the vertebra with the first hemal arch.

Trace each of the parts mentioned in the description of a typical trunk vertebra into the caudal region and note their modifications. Is the hemal arch of the caudal vertebra formed from modified transverse processes or is it an independent structure? How

many caudal vertebrae are there? *Count these in the demonstration specimen.*

The Cervical Vertebra. Compare this vertebra with those that follow it and note how it is especially modified to articulate with the skull. Does it possess all the parts of a typical trunk vertebra?

Ribs. The ribs of *Necturus*, compared with those in the shark, are structurally more complicated but of little more functional importance. The ribs are relatively short, forked proximally and articulate with the transverse processes of the vertebrae by the two heads. The dorsal, or **tubercular head**, articulates with the diapophysis; the ventral, or **capitular head**, with the parapophysis. The latter articulation is much the stronger of the two. Notice that the capitular head of the rib bears a pleurapophysial socket for the pleurapophysial cartilage as does the parapophysis of the transverse process. How does the tubercular head of the rib articulate with the diapophysis?

In a cleared demonstration specimen, notice that the pelvic girdle is attached to the vertebral column by means of a rib somewhat heavier and stronger than the others. This is called the **sacral rib**. Notice, also, corresponding with the diapophysis of the sacral vertebra, the tubercular head of this rib bears a pleurapophysial socket.

In the demonstration specimen, determine which of the vertebrae do and which do not bear ribs.

Development of the Vertebrae. In the development of the vertebrae of *Necturus*, only the basidorsal- and basiventral-arch elements appear. These appear at definite intervals along the notochord, one pair for each myoseptum which separates the successive myotomes. The basidorsal arcualia form the neural arches. The anterior and posterior zygapophyses develop later as projections from the neural arch, so the basidorsals are to be considered as giving origin to these structures also. The morphology of the transverse processes of *Necturus* is rather involved and will not be treated in this study. The basiventral arcualia form the hemal arch in the caudal region. Interdorsal and interventral arcualia do not appear.

The centrum of *Necturus* forms differently than in the shark. Cells from the bases of the arcualia do not pierce the outer sheath of the notochord, but the scleroblastic tissue, which forms the

arcualia in their place, surrounds the notochord externally to the sheaths and later ossifies to form the centrum. Such vertebrae in which the centra are formed externally to, and surrounding, the notochord and its sheaths are called **arcocentrous** vertebrae.

Plate 14. Figure 17. Dorsal Aspect of a Trunk Vertebra of Necturus with Rib Attached.

Figure 18. Ventral Aspect of a Trunk Vertebra of Necturus.

Figure 19. Cephalic Aspect of the Cervical Vertebra of Necturus.

Figure 20. Lateral Aspect of a Caudal Vertebra of Necturus.

Label completely and indicate the anterior end of each vertebra by a small arrow pointed toward the head.

The Vertebral Column, Ribs and Sternum of the Cat.

The notochord, as such, is lost in early developmental stages in reptiles, birds and mammals. The definitive vertebrae of the cat show no vestige of this structure since the centrum is composed of solid bone, but, between the vertebrae, a vestige of the notochord does remain. It is represented by a series of detached expansions, or **nuclei pulposi**, one of which occurs in each intervertebral ligament which binds the contiguous vertebrae together.

Regional Differentiation. The vertebral column of the cat shows a greater amount of regional differentiation than that of any of the forms previously studied. This is due in part to the support of the body axis at two points. That part of the column anterior to the pectoral girdle is called the **cervical** region. The trunk region, that portion between the pectoral and pelvic girdles, has become differentiated into two regions, a cephalic **thoracic** and a caudal **lumbar** region. The vertebrae of the thoracic region bear functional ribs. The vertebrae taking part in the attachment of the pelvic girdle are fused, in the adult, and constitute the **sacral** region. Posterior to the sacrum is the **caudal** region.

Determine the number of vertebrae in each region. Study the mounted skeletons carefully as well as the disarticulated vertebral columns which are issued for study.

The Cervical Vertebrae. The first two vertebrae of the cervical region are especially modified in the cat so that a firm attachment with the skull is effected but in such a way that marked

freedom of movement of the head is possible. These will be described later after a less-modified cervical vertebra is studied.

Study the fourth cervical vertebra. Locate the bony **centrum** with its neural arch. Examine the articulation between contiguous centra. Both anterior and posterior faces of the centrum are flat, or nearly so. Vertebrae of this type are called **amphiplatyan** and are characteristic of mammals. Contiguous vertebrae are joined by an intervertebral ligament. Identify these structures in the mounted skeletons. The so-called **transverse process** of the cervical vertebra which projects ventro-laterad comprises three parts; (1) a dorsal projection, arising from the neural arch and (2) a ventral projection, arising from the centrum. Laterally these are permanently fused with (3) a short rib, so that a space, the **transverse foramen**, is formed along the side of the vertebra. These foramina of the cervical vertebrae, placed together, form a canal, the **vertebral canal**, for the vertebral artery. Locate the **anterior** and **posterior articular surfaces** on the neural arch. Dorsally the neural arch projects as a short **neural spine**.

The first cervical vertebra, or **atlas**, is especially modified to articulate with the skull. It is ringlike in shape with broad, flat lateral **transverse processes**. Locate the two strong **anterior articular surfaces** which engage the occipital condyles of the skull. Locate the **transverse foramen**, opening anteriorly at about the middle of the ventral surface of the transverse process. From this foramen, a groove leads around to the **atlantal foramen** on the dorsal side. The vertebral artery runs forward through the vertebral canal and, emerging on the ventral surface of the transverse process, extends around to the dorsal side through the atlantal foramen into the neural canal where it continues forward into the cranial cavity of the skull. Notice that the atlas lacks a centrum.

The second cervical vertebra is the **axis** or **epistropheus**. Craniad, the centrum of the axis projects as the slender **odontoid process**. This process represents the centrum of the atlas which, instead of fusing with its own vertebra, joins the next one caudad. In the vertebral column of a young cat, locate the suture indicating this fusion. The odontoid process forms a pivot to provide for rotary movement of the head. Laterad of the odontoid process the centrum bears the **anterior articular surfaces**.

Locate the **transverse processes**, **transverse foramina** and **posterior articular surfaces**. Notice the modifications of the **neural spine** which are peculiar to this vertebra.

Each of the seven cervical vertebrae may be distinguished from the others by differences in structure mainly in the transverse processes and neural spines. What are these differences?

The Thoracic Vertebrae. These are the most typical of all the vertebrae, and the fourth one of these will be described. In cephalic aspect, the **centrum** will be seen ventrad of the **neural canal**. The neural canal is surrounded by an oval ring, the **neural arch**, which bears several processes. Projecting laterad from the neural arch is the **transverse process**, the lateral face of which articulates with the dorsal head of the rib. The strong **neural spine** projects dorsad from the neural arch.

The neural arch is divided into two parts. That portion between the centrum and the transverse process is called the **pedicle** and that between the transverse process and the neural spine, the **lamina**. Locate the **anterior articular surfaces**.

Note these features in the lateral view of the vertebra. At the caudal end of the centrum, at its dorso-lateral angle, is a smooth surface called the **caudal costal demifacet**. In a corresponding position on the cranial end of the centrum is the **cranial costal demifacet**. When consecutive centra are placed together, the two demifacets form the **costal facet** which articulates with the ventral head of the rib.

Compare each of the thoracic vertebrae with the one studied. Following the thoracic vertebrae caudad, notice the gradual increase in the size of the centrum. The neural spines of the first four thoracic vertebrae are of about equal length. From the fourth through the eleventh, they become successively shorter and then, in the twelfth and thirteenth, successively longer than in the eleventh. The transverse processes from the seventh vertebra caudad tend to divide into three parts. These three divisions will be described and named in the study of the lumbar region. Compare the articular processes in the anterior end of the thoracic region with those in the posterior end. Notice that from the tenth to the thirteenth thoracic vertebra, owing to interlocking of the articular processes, very little rotary motion between vertebrae is possible.

The Lumbar Vertebrae. These are larger than the thoracic vertebrae. On them, locate the **centrum**, **pedicles**, **laminae** and **neural spine**. The transverse process in this region has separated into three divisions. The most ventral, extending cephalo-laterad, is the **pseudo-transverse process**. Of the two dorsal processes, the anterior is the **mammillary** and the posterior, the **accessory**. On a mounted skeleton, trace the thoracic transverse processes caudad into the lumbar region and note their division into these three distinct parts. Locate the **anterior** and **posterior articular surfaces**. What role do the accessory and mammillary processes play in the articulation between vertebrae?

The individual vertebrae of the lumbar region do not differ markedly from each other, but certain differences do appear in the centrum and the processes. Follow each of these through the lumbar region and be able to characterize as accurately as possible each of the vertebrae.

The Sacral Vertebrae. In an adult cat, the sacral vertebrae are fused into a single bone, the **sacrum**. In a kitten, the vertebrae are separate, and the number fusing may be determined. Piercing the dorsal side of the sacrum, on either side of the mid-line, are two pairs of **dorsal sacral foramina**. In a corresponding position on the ventral side are the **ventral sacral foramina**. What do these represent? Do they give a clue as to the number of vertebrae fusing to form the sacrum?

Laterally, the sacrum articulates with the ilium of the pelvic girdle. As in *Necturus*, this attachment is effected by means of a sacral rib or **costal element**; in the cat, however, this costal element fuses with the vertebra so as to become an indistinguishable part of it.

The Caudal Vertebrae. The caudal vertebrae gradually decrease in size from the anterior to the posterior end. The neural arch, transverse and articular processes, become reduced until, in the final vertebrae, only the centrum persists. How far caudad may these structures be identified?

The hemal arch, which has been characteristic of the caudal vertebrae in the two forms previously studied, is very much reduced but is present, however, as the **chevron bone**. Examine the demonstration specimen to determine how many of these there are and on which vertebrae they appear.

tant part in the formation of the centrum. Amniotes, of which the cat is a representative, differ in this respect. It should be made clear at this time that individual arcualia do not appear as such during development in amniotes and that the interpretation of the parts present as arcualia is based on their relation to the part-scleretome and on their position in the vertebra relative to other parts. On this basis, it is agreed that the centrum of amniotes is formed mainly by interdorsal and interventral arcualia rather than basidorsals and basiventrals, but it is not agreed as to the relative part played by each of these. Some argue that interventrals form the greater part of the centrum, while others are of the opinion that the interdorsals form the greater part.

The diagrams in Fig. 2 present graphically the fate of the arcualia in the definitive vertebrae of *Necturus* and one view of their fate in the cat. At the present time, there is a difference of opinion concerning their fate in the cat. The diagrams also present the probable phylogeny of the vertebral column of terrestrial vertebrates. It should be pointed out that, while from the functional aspect it is of little or no importance which of the arcualia constitute a given part of the definitive vertebrae, the structure of the vertebrae is a valuable guide in a study of phylogeny, and, therefore, the combination of arcualia in the formation of vertebrae becomes important.

A comparison of *Necturus* (Fig. 2, *F*) with the cat (Fig. 2, *G*) will show that the morphology of the vertebrae in these two animals is quite different. They are both thought, however, to have been derived from a common type possessed by some primitive ancestral tetrapod (Fig. 2, *A*).

In this primitive vertebra, the neural arch is seen to be formed by the basidorsal arcualia. The centrum is divided into two regions. The anterior region formed mainly from the basiventrals is called the **hypocentrum**, and the posterior region formed from the interdorsals and interventrals is called the **pleurocentrum**. It may be emphasized that this condition is not hypothetical but is known to have obtained in certain fossil animals which are thought to have been closely related to the ancestors of living tetrapods.

Divergent paths from this common type have been followed by **amphibians** and **amniotes**. In **amphibia**, the **hypocentrum** has

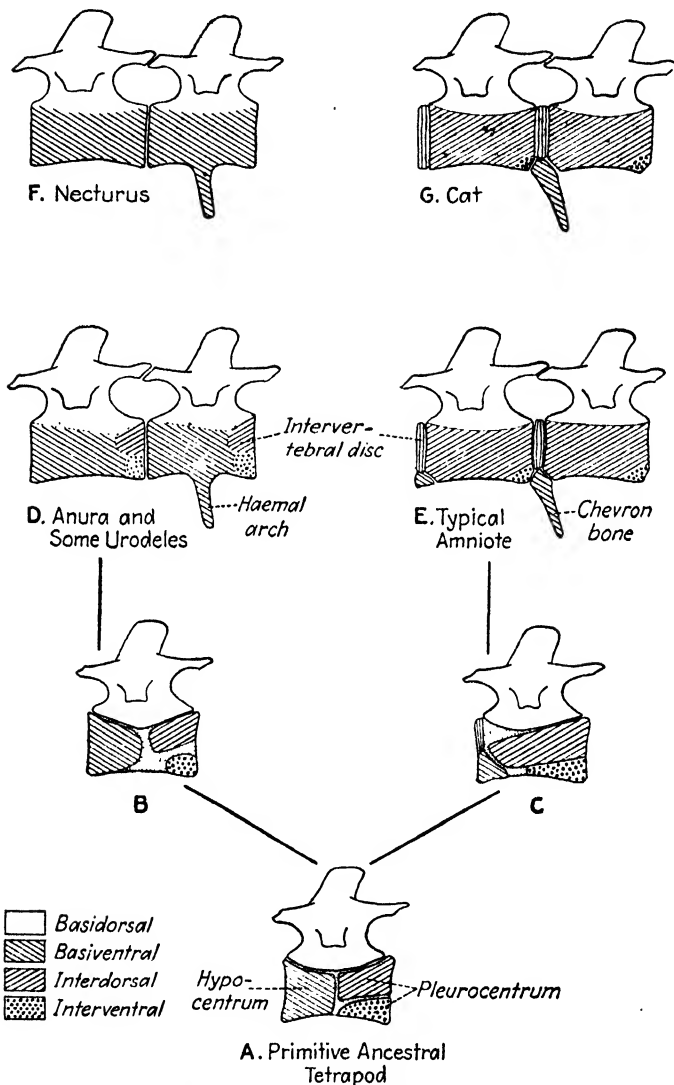


FIG. 2.—Diagram to show the probable phylogeny of the vertebral column in amphibia and in amniotes and to show the role of the arcualia in the formation of the vertebrae. In Figs. D to G caudal and trunk vertebrae are shown. (Modified from Goodrich.)

gained in importance at the expense of the pleurocentrum. In amniotes, the reverse is true; the pleurocentrum has gained at the expense of the hypocentrum.

It has been previously mentioned that only basidorsals and basiventrals are represented in the vertebrae of Necturus. Such is not the case in all amphibia. Recall that the vertebrae of Necturus are amphicoelous and that the intervening space between successive vertebrae is filled with the persistent notochord. In the Anura and some of the Urodela, the notochord in the intervertebral space is replaced by a nodule of cartilage which is considered by some workers to represent fused intercalary elements, interdorsals and interventrals. This cartilage usually fuses with the basiventrals anterior to it and forms a small part of the definitive centrum (Fig. 2, D). When this is the case a **procoelous vertebra** results. In some cases, the fusion is between the intervertebral cartilage and the posterior basiventrals, in which case an **opisthocoelous vertebra** results.

In amniotes, the morphology of the posterior zygapophyses is not so simple as it is in amphibia where they develop as processes of the neural arch. In amniotes, they chondrify as separate cartilages which later fuse with the neural arch. These cartilages have been interpreted as representing dorsal portions of the interdorsal arcualia. The major portion of this arch element, however, is to be identified in the pleurocentrum. The hypocentrum becomes less important in amniotes and eventually, in mammals (Fig. 2, G), disappears except in the tail region where it forms the chevron bone. The centrum is then made up, for the most part, of interdorsals. The interventrals are present, but they form a smaller part of the centrum as the pleurocentrum gains in importance. In the most primitive living reptiles, hypocentra are still present in the definitive vertebral column (Fig. 2, E).

Plate 15. Figure 21. Dorsal Aspect of the Atlas of the Cat.

Figure 22. Lateral Aspect of the Axis of the Cat.

Figure 23. Lateral Aspect of a Thoracic Vertebra of the Cat.

Figure 24. Lateral Aspect of a Lumbar Vertebra of the Cat.

Label completely and indicate the anterior end of each vertebra by a small arrow pointed toward the head.

THE APPENDICULAR SKELETON

The appendicular skeleton includes the skeletal support for the median and paired appendages, and the girdles which support and attach the paired appendages to the body. The pectoral girdle supports the anterior or pectoral appendages while the pelvic girdle supports the posterior or pelvic appendages. The sternum described above as a part of the axial skeleton in the cat may be considered also as a part of the appendicular skeleton.

Two very different types of appendages are present in vertebrates: the fin type, in Pisces; and the pentadactyl-limb type, in four-footed animals.

Fishes use their fins mainly as balancing organs rather than to drive the body forward through the water. Forward movement is accomplished mainly by lateral movements of the body. Since the paired fins of most fishes play only a limited part in locomotion, they are usually unattached to the axial skeleton. On the other hand, terrestrial vertebrates use their pectoral and pelvic limbs as locomotor organs. Of the two, the pelvic limbs are the more important as walking appendages, and these become attached to the axial skeleton by means of their girdle.

The Appendicular Skeleton of the Shark.

The Pectoral Girdle and Fin. *If the pectoral girdle has already been removed from the body during the dissection of the axial skeleton, before beginning this dissection, study the specimen and orient the girdle so as to determine its proper position in the body. Carefully remove the skin covering the girdle. Remove the skin covering the dorsal surface of the fin. Carefully clean away all the muscles covering the girdle and the muscles from the dorsal surface of the fin. Clean up thoroughly the articulation between the girdle and fin but do not sever one from the other. Leave the ventral surface of the fin undissected for the time being.*

The pectoral girdle is a U-shaped cartilage partially encompassing the body. It is composed of two halves joined at the mid-ventral line. Note the rounded projection bearing the **glenoid surface** articulating with the fin skeleton. This projection more or less arbitrarily divides each half of the girdle into a dorsal and ventral division.

The ventral division is the **coracoid** portion. It bears posteriorly a strong **coracoid process** from which the muscles which insert on the ventral surface of the fin take their origin. The dorsal division is the **scapula** which is tipped with a dorsal **suprascapula**.

Cephalad of the glenoid surface, but piercing the coracoid portion of the girdle, is the **coracoid foramen** for the passage of nerves and blood vessels to the fin. Cephalad of this foramen is a **calcified area** in the girdle.

The skeleton of the fin is made up of a proximal row of three large cartilages and a large number of distal **radials**. The proximal row consists of a cephalic **propterygium**, a middle **mesopterygium** and a caudal **metapterygium**. Which of these articulate with the glenoid surface of the girdle? The radials are arranged, three in a series, to form a cartilaginous fin ray.

The expanded, distal portion of the fin is supported by dermal elements called **actinotrichia**. *On the ventral surface of the fin, where the muscles have not been removed, study the relationship of the actinotrichia to the muscles and to the underlying endoskeletal parts.* Notice that the muscles are arranged in bundles, each bundle ending in a small tendon which is continuous with the actinotrichia.

Plate 16. Figure 25. Lateral Aspect of the Pectoral Girdle and a Portion of the Fin of the Shark to Show Position in the Body.

Label completely and color as follows: scapula light yellow; suprascapula light blue; coracoid light brown. Do not forget to add the color legend.

Plate 16. Figure 26. Ventral Aspect of the Pectoral Girdle and Fin of the Shark.

Label and color as in the preceding figure. The actinotrichia have been purposely omitted from this figure. Draw in a few showing their relation to the radials.

The Pelvic Girdle and Fin. *After making certain that its orientation in the body is understood, remove the skin, muscles and connective tissue to expose the skeleton of the pelvic girdle and fin. The fin skeleton, on one side only, need be exposed.*

The pelvic girdle is composed of a single horizontal cartilaginous element called the **ischiopubic bar**. This bar is slightly concave dorsally and is enlarged at its lateral ends. The cephalo-lateral margin of the ischiopubic bar projects slightly dorsad as a short **iliac process** for the attachment of muscles. The girdle is perforated on either side by two foramina. The more mesal of these is the **obturator foramen** for the passage of nerves to the fin. The more lateral one is for the passage of a blood vessel.

At the caudo-lateral margin of the girdle is the **acetabular surface** for the articulation of the skeleton of the fin.

The skeleton of the fin is composed of two proximal basal elements and numerous distal radials. The anterior basal element, the **propterygium**, projects laterad. Does it bear radials? The posterior basal element, the **metapterygium**, extends caudad and bears laterally numerous **radials**.

In the male shark, certain of the skeletal parts of the pelvic fin are modified to form a support for the **claspers**. These are the copulatory organs. If your specimen is a female shark, notice the claspers on a male specimen. On the undissected fin, note the groove on the medial side of the clasper. When the two claspers of opposite sides come together, a tube is formed through which the seminal fluid passes from the male into the genital organs of the female. Examine the end of the clasper and notice the strong hook used to hold the clasper in the oviduct.

After the above study is complete, detach the pectoral and pelvic fins from their girdles. Notice that the articulation is by a ball-and-socket joint, and that the socket is borne by the appendage and the ball by the girdle. This arrangement does not permit the freedom of movement that is possible when the socket is borne by the girdle, but the fins of fishes are not called upon to execute a wide variety of movements. The paddlelike use of the fin does not require intrinsic flexibility between skeletal parts of the fin, nor does it require movement through a large radius between girdle and fin.

It should be especially noted that there is no direct skeletal attachment between the vertebral column and pelvic girdle. Would anything be gained by such an attachment?

Compare the skeleton of the pectoral girdle and fin with that of the pelvic girdle and fin. Notice that they are, part for part, **almost identical**.

Plate 17. Figure 27. Ventral Aspect of the Pelvic Girdle and Fin of the Male Shark.

Plate 17. Figure 28. Ventral Aspect of the Pelvic Girdle and Fin of the Female Shark.

Just above the ischiopubic bar in one of the figures on this plate, draw a cephalic aspect of the pelvic girdle showing the iliac processes. Color ischiopubic bar light brown; iliac process light yellow. Label completely.

The Appendicular Skeleton of Necturus.

Balsam mounts will be used for the study of the appendicular skeleton of Necturus, but reference should be made to the demonstration specimens to determine the position and relationships of these parts in the body and to each other.

The Pectoral Girdle and Limb of Necturus. The pectoral girdle consists of two halves, but unlike the shark, they do not articulate with each other at the mid-line. Each half of the girdle is entirely free from the other half and from other parts of the skeleton also. When the two halves are placed together, they form a U-shaped structure almost entirely encircling the anterior end of the trunk region.

Each half of the pectoral girdle is composed of three parts which come together at the **glenoid fossa**, the point of articulation with the limb. The dorsal or scapular extension is narrow at its origin but broadens out dorsally into a thin plate of cartilage. The narrow part of the extension becomes ossified to form the **scapula**. Dorsad of this is the unossified **suprascapula**. Of the two ventral elements, the anterior, or **procoracoid**, is long and narrow and is directed cephalad, while the posterior, the **coracoid**, forms an almost circular plate which bends around the ventral side of the body. The coracoid of one side may extend across the mid-line and be overlapped by that of the other side. The two ventral elements are unossified. A short distance ventrocephalad of the **glenoid fossa**, locate the **coracoid foramen**.

The pectoral limb or arm, naming from the proximal end, is divided into **upper arm**, **forearm** and the **manus** or hand. The manus includes the **carpus** or wrist, the **metacarpus** or palm, and the **fingers**. With the exception of the carpus which is entirely cartilaginous, the bones of the pectoral limb consists each of a bony central shaft or diaphysis and two cartilaginous ends or

epiphyses, an exception being found in the distal phalanges which are without terminal epiphyses.

The upper arm is supported by the **humerus**. Locate the **diaphysis** and the **epiphyses**. The rounded proximal end is the **head** which fits into the glenoid fossa, forming a ball-and-socket joint. The distal end of the humerus bears a deep, median groove which separates two distinct masses, the lateral of which is the **external condyle** and the mesal, the **internal condyle**.

The next division of the arm is supported by two slender bones, an anterior or preaxial **radius**, and a posterior or postaxial **ulna**. The radius bears proximally a socket or depression into which fits the external condyle of the humerus. The proximal end of the ulna is prolonged into a curved **olecranon process** which lies in the deep groove between the two condyles of the humerus.

The carpus or wrist is made up of several small cartilages arranged in three rows. The proximal row consists of two elements, a mesal **radiale** articulating with the distal end of the radius, and a larger lateral one opposite the ulna which represents the fusion of two originally distinct elements, a mesal **intermedium** and a lateral **ulnare**. This is perforated by the **foramen carpale** representing the line of fusion of the two elements. Three cartilages comprise the distal row. The first two digits on the radial side of the wrist each have opposite their bases a distinct element, a **carpale**. The carpals corresponding to the last two digits on the ulnar side of the wrist have fused into a single large element. Between the proximal and distal rows, mentioned above, is a single element, the **centrale**.

The metacarpus or palm is supported by a row of four **metacarpals**.

Four digits are present in *Necturus*, the thumb being absent. How many **phalanges** are there in each of the digits present?

Plate 18. Figure 29. Lateral Aspect of the Left Half of the Pectoral Girdle of *Necturus*.

Label completely and color to show homologies with the girdle of the shark using the same colors as on Plate 16.

Plate 18. Figure 30. Dorsal Aspect of the Left Arm of *Necturus*.

Counting the thumb as digit 1 and as absent from the radial side of the hand, designate the carpals and digits by the proper number

according to their position. Label completely and color the bone light brown; cartilage light blue. This plate will require two color legends.

The Pelvic Girdle and Limb of Necturus. The pelvic girdle consists of a single, ventral, flat, triangular element called the **ischiopubic plate**, and the two lateral **ilia**. The ilia project dorso-laterad from the lateral margins of the ventral plate and articulate with the vertebral column by means of the **sacral ribs**. The anterior median angle of ischiopubic plate is tapered and extends along the mid-line of the abdomen.

The caudo-lateral angles of the girdle are ossified. The ilium also is partially ossified. It has at its distal end a cartilaginous epiphysis through which it articulates with the sacral rib.

Ventrad of the point of attachment of the ilium is the **acetabulum**, the fossa for the articulation of the leg skeleton. On the ventral side, a little cephalo-mesad of the acetabulum, is the **obturator foramen**. A line extending through the obturator foramina of the two sides divides the ischiopubic plate into the cephalic **pubis** and the caudal **ischium**. The caudo-lateral margin of the ischium has a well-defined **tuberosity**. The ventral face of the ischium shows a slight ridge along the mid-ventral line, the **crista muscularis** for the attachment of certain of the appendicular muscles. The dorsal face of the ischiopubic plate is excavated for the accommodation of the viscera.

The pelvic limb or leg is almost an exact duplicate of the pectoral limb. Naming from the proximal end, it is divided into **thigh, shank** and **pes** or foot, the foot being further divided into the **tarsus** or ankle, the **metatarsus** or sole and the **digits** or toes.

The **femur** corresponds with the humerus of the arm and supports the thigh. The proximal epiphysis of the femur is rounded to form the **head** which fits into the acetabulum of the pelvic girdle forming a ball-and-socket joint. The distal end of the femur presents **internal** and **external condyles** which articulate, respectively, with the **fibula** and **tibia** of the shank. Of these two bones, the tibia is preaxial, corresponding with the radius of the arm, and the fibula is postaxial, corresponding with the ulna.

The pes is identical in structure with the manus. At the end of the tibia is the **tibiale** and at the end of the fibula is a larger

cartilage representing fused **fibulare** and **intermedium**. The **foramen tarsale** marks the point of fusion between these two elements. Three **tarsals** are present, but as in the carpus, the larger cartilage on the postaxial side of the foot represents a fusion between two originally distinct tarsals. Between the proximal and distal rows of ankle cartilages is the single **centrale**.

The number and arrangement of the **phalanges** in the toes correspond with the number and arrangement in the fingers.

The Generalized Plan of Structure of the Appendicular Girdles. In spite of the differences that exist, there is surprising uniformity in the plan of structure of the limb girdles of all vertebrate animals. Not only does the pectoral girdle of one vertebrate resemble that of other vertebrates, and the pelvic girdle of one resemble that of others, but there is also a similarity of structure between the pectoral and pelvic girdles in all vertebrates. This similarity is more marked in those animals in which the pectoral and pelvic appendages are put to similar uses but can be recognized also in those animals where the limbs vary widely in use.

It is possible to recognize a generalized plan of structure in the girdles of all vertebrates in which the girdle is composed of two halves. Each half is made up of three parts, two of which are ventral and one of which is dorsal. These three parts come together at the point of articulation with the free appendage.

The pectoral girdle of *Necturus* illustrates this structural plan. It has been seen that the pectoral girdle is made up of two halves, each composed of a ventral and anterior procoracoid, a ventral but posterior coracoid, and a dorsal scapula. Each part in the pectoral girdle has its counterpart in the pelvic girdle, the procoracoid corresponding to the pubis, the coracoid, to the ischium, and the scapula, to the ilium.

While not fully expressed, the rudiments of this plan may be recognized in the girdles of the shark. In the study of the cat which follows, the girdles will be seen to conform, in general, with this plan.

The Generalized Plan of Structure of the Free Appendage. The shark with its fin type of appendage and *Necturus* with its pentadactyl type present two very different free appendages between which there is little or no similarity in structure. The pentadactyl appendage must have been derived from the fin type,

but the stages by which this transition has been made are not very complete. It is thought, however, that, by a loss or fusion of the numerous cartilaginous fin rays present in primitive fishes and by a rearrangement of those that persisted, the pentadactyl limb has been evolved. This supposition is not entirely hypothetical, for the structure of the fins in living lobe fins and more especially in the fossil *Crossopterygii* is strongly suggestive of the way in which this transformation may have been accomplished.

Four-footed vertebrates all follow the same morphological plan of structure for both fore and hind limbs, regardless of the purpose for which the appendages are used. Such a generalized plan is illustrated below.

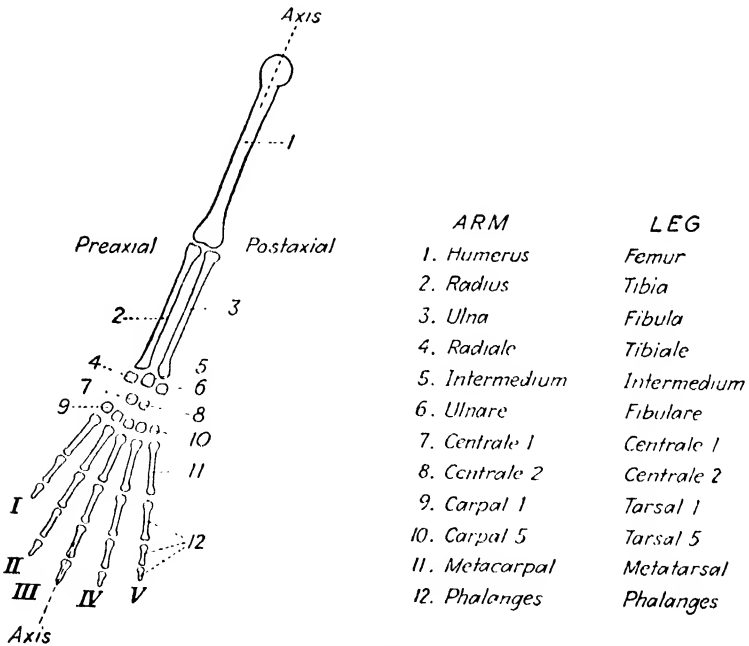


FIG. 3.—Diagram of a generalized pentadactyl appendage.

Compare the fore and hind limbs of *Necturus* with the generalized limb and determine the modifications which have been necessary to derive them. Have the modifications been the same for both limbs? Do the same in the study, which follows, of the limbs of the cat.

Plate 19. Figure 31. Ventral Aspect of the Pelvic Girdle of Necturus.

Label completely and color the bone light brown; cartilage light blue.

Plate 19. Figure 32. Lateral Aspect of the Pelvic Girdle of Necturus Showing Its Attachment to the Vertebral Column.

Label completely and color the ischiopubic plate light brown; ilium light yellow. This will necessitate a different color legend.

Plate 19. Figure 33. Dorsal Aspect of the Right Pelvic Limb of Necturus.

Number the digits as in the pectoral limb. Label completely and color bone light brown; cartilage light blue.

The Appendicular Skeleton of the Cat.

For this study, disarticulated girdles and special skeletal mounts of the limbs will be used. Also study the mounted skeletons carefully for the relation of parts. Where necessary, refer to the skeleton of the kitten.

The Pectoral Girdle and Limb of the Cat. The pectoral girdle consists, in the main, of a flat triangular **scapula**. No suprascapular element can be seen in the adult cat. Refer to a demonstration specimen of the scapula of a kitten and note the narrow **suprascapular cartilage** along the dorsal border of the scapula. The ventral end of the scapula is hollowed out for the articulation of the head of the humerus. This depression is called the **glenoid fossa**.

The coracoid element of the girdle is very much reduced and is represented by the **coracoid process**, a curved projection extending inward from the anterior margin of the glenoid fossa. Look at the coracoid process on the scapula of a kitten. Sometimes the suture between scapular and coracoid elements may be seen.

The scapula presents three borders: the dorsal or **vertebral border**, the caudal or **glenoid border** and the cephalic or **coracoid border**. The coracoid border of the scapula projects slightly forward over the glenoid fossa as the **bicipital tubercle**. This process is just laterad of the coracoid process.

From the lateral surface of the scapula projects a ridge for muscular attachments, the **spine**. The ventral end of the spine is free and is called the **acromion process**. Projecting caudad from the spine is the **metacromion process**. The spine divides

the lateral face of the scapula into two divisions: that anterior to the spine is called the **supraspinatus fossa** and that posterior, the **infraspinatus fossa**.

The pectoral girdle, like the skull, has associated with it certain dermal bones. The number of such bones is largest in the aquatic bony vertebrates where they may form a major portion of the girdle and serve as an attachment between the girdle and axial skeleton. The number is reduced in terrestrial vertebrates. None is present in *Necturus*, but in the cat, one of these, the **clavicle**, remains.

The clavicle of the cat is a slender bone extending between the ventral margin of the scapula and the manubrium of the sternum. This bone is better developed in climbing than in running mammals. In climbing mammals, it forms a strong brace between the sternum and scapula by means of which the latter is held in position. Locate the clavicle on a mounted skeleton.

The proximal division of the arm, the **upper arm**, is supported by the **humerus**. The **head** of the humerus is the enlarged rounded swelling on the posterior part of the upper extremity of this bone. The articular surface of the head is very smooth and fits into the glenoid cavity of the scapula.

The **greater tuberosity** is a broad, flattened process applied to the outer side of the head. At the extreme caudal end of the greater tuberosity is a marked depression, the **infraspinatus fossa**.

The **lesser tuberosity** is a smaller process closely applied to the medial side of the head of the humerus. Between the lesser and greater tuberosities is the **bicipital groove**.

In an anterior view of the humerus, the **pectoral ridge** will be seen extending ventrad from the anterior portion of the greater tuberosity. The two rounded projections at the extreme distal end of the humerus are the **external** and **internal condyles**. Just above the internal condyle is the **supracondyloid foramen** enclosed laterally by the **supracondyloid bar**. The **internal supracondyloid process** is the projection on the medial side of the humerus between the supracondyloid foramen and the internal condyle.

The lateral surface of the humerus presents the following features. Extending from the infraspinatus fossa, downward and forward to the pectoral ridge is the **deltoid ridge**. At the distal end of the humerus, laterad of the external condyle is a

roughened tubercle, the **external supracondyloid process**. Extending upward and backward from the latter toward the caudal margin of the humerus is the **supracondyloid ridge**.

The bones of the **forearm** are the **radius** and **ulna**. The ulna lies laterad of the radius except in the region of the elbow joint where it is more nearly caudad of the radius.

The notch or groove on the ulna into which the distal end of the humerus fits is called the **greater sigmoid cavity**. That portion of the ulna proximad of this cavity is the **olecranon process**. The distal extremity of the ulna terminates in a tapering head which is called the **styloid process**.

The radius is the shorter of the two bones of the forearm. Its head articulates with the external condyle of the humerus and its distal end with the wrist. On the mesal side, the distal end of the radius is prolonged into a **styloid process**. On the ventro-lateral side of the radius, a short distance distad of the head, is a roughened, low prominence, the **bicipital tuberosity**.

The structural features of the three bones of the arm and the scapula described above should be located and memorized very thoroughly. A knowledge of them is very important in the study of the musculature of the arm which will be made later.

The **carpus** or wrist is the proximal and smallest part of the hand. The seven carpal bones are arranged in two approximately transverse rows with three in the proximal and four in the distal row. Naming from the radial side of the wrist, the proximal row is composed of a large **scapholunar**, a medial **cuneiform** and a laterally projecting **pisiform**. Again, naming from the radial side, the distal row is composed of the **trapezium**, the **trapezoid**, the **os magnum** and the **unciform**.

These bones, with the exception of the pisiform, have come about as a result of a fusion between the morphological elements of the wrist named and diagrammed on page 63. The arm of the cat differs from the typical pentadactyl limb in that only one centrale is present during development. The scapholunar has resulted from a fusion of the radiale, the intermedium and the single centrale. The cuneiform represents the ulnare. The trapezium, trapezoid and os magnum represent, respectively, carpals 1, 2 and 3. The unciform represents a fusion of carpals 4 and 5.

The pisiform is a **sesamoid bone**. These are bones which develop within tendons near joints. They are not preformed in cartilage and, for this reason, have no equivalents in the typical pentadactyl appendage. The pisiform is sometimes called the **ulnar sesamoid** bone since a **radial sesamoid** bone also may be present. The radial sesamoid, when present, is a very small bone just distad of the mesal margin of the scapholunar. Is it present in your specimen?

The **metacarpus** forms the middle region of the hand. It is composed of five long bones, the **metacarpals**, extending between the wrist and the distal portion of the hand.

The **digits** are supported by the **phalanges**. Determine the number of phalanges present in each digit. Look at the phalanges from the lateral aspect and note the position and relations of the terminal phalanx. How is the epidermal claw supported? Are sesamoid bones present near any of the joints of the fingers?

Polydactylism is not uncommon in the cat. By polydactylism is meant an increase in the number of digits present over the normal number, which is five. When supernumerary digits are present, they are always added to the radial side of the hand, in which case, usually only the thumb is abnormal, the other fingers being normal. Polydactylism is sometimes, but not always, accompanied by abnormalities in the wrist bones. If one hand is abnormal, usually both are abnormal. When the hands are abnormal, the feet may be also, but not necessarily so.

Plate 20. Figure 34. Lateral Aspect of the Scapula of the Cat.

Label completely but do not color.

Plate 20. Figure 35. Mesal and Ventral Views of the Scapula of a Kitten.

Label completely and color the suprascapular cartilage light blue; scapula light yellow; coracoid process light brown.

Plate 21. Figure 36. Cephalo-lateral Aspect of the Right Fore Limb of the Cat.

Label completely. After the descriptive names of the bones, in parentheses, add the morphological equivalents. Number the digits. By bracketing, label the divisions of the arm in addition to the separate parts.

The Pelvic Girdle and Limb of the Cat. The pelvic girdle of the cat consists of two **innominate bones** which form the ventral wall and sides of the pelvis. The two are united below at the **symphysis** but are separated above by the sacrum of the vertebral column.

Each innominate bone comprises four elements which are separate in early life but fused into a single structure in the adult. Three of these bones are arranged around the cup-shaped cavity, the **acetabulum**, into which the head of the femur fits. Their boundaries may be seen best in a young specimen.

The **ilium** is the elongated part of the girdle which projects upward, forward and outward to articulate with the sacrum. Its ventral boundary is at a line drawn nearly at right angles to its long dimension through the anterior fifth of the acetabulum. The **ischium** and **pubis** surround the oval opening, or **obturator foramen**, in the lower part of the bone. The ischium is caudal, extending from the ilium around the caudal margin of the obturator foramen to a point midway between the anterior and posterior ends of the symphysis of the two innominate bones. The pubis is the anterior, extending from the acetabulum around the anterior margin of the obturator foramen to meet the ischium. The pubis is excluded from the acetabulum by the small triangular **acetabular bone**.

The **femur** is the single bone of the **thigh**. It articulates above by a ball-and-socket joint with the acetabulum of the innominate bone, and below by a hinge joint with the larger of the two bones of the shank.

The rounded articular knob at the proximal end of the femur is called the **head**. Its inner surface is marked at about its middle by a deep, round pit, the insertion of the round ligament which unites the femur and the acetabulum. The **neck** separates the head from the shaft of the femur. The neck passes outward almost horizontally to the **greater trochanter**, a prominent process for muscular attachment. On the caudal surface of the proximal portion of the femur will be seen a smaller projection, the **lesser trochanter**. The depression between the head and greater trochanter on the caudal face of the femur is the **digital fossa**.

The distal extremity of the femur bears the **external** and **internal condyles**. The internal condyle is on the same side of the femur as the head. Between the two condyles on the anterior

side of the femur is a shallow articular groove, the **trocilea**, into which fits the **patella**, or knee cap. The patella is a sesamoid bone.

In the cat the **tibia** is much larger than the fibula and is found on the inner side of the **shank**. The **fibula** is exceedingly slender and takes no part in the articulation of the shank with the thigh or of the shank with the foot.

The **tarsus** is constituted of seven tarsal bones. The tarsus is relatively much longer than the carpus in the cat. It forms about a third of the entire foot, whereas the carpus formed only about one-eighth of the length of the hand.

The tarsal bone articulating with the tibia is the **astragalus**. This bone represents two embryologically distinct elements, the tibiale and the intermedium. The large bone lying ventrad of the astragalus and projecting backward as the heel is the **calcaneum**. This represents the fibulare. Just distad of the astragalus is the **scaphoid** or **navicular** which represents the centrale. The distal part of the tarsus is composed of four bones arranged approximately in one transverse row. Naming from the inner or tibial side they are as follows: **entocuneiform**, **mesocuneiform**, **ectocuneiform** and **cuboid**. Of these, the first three represent, respectively, tarsals 1, 2 and 3. The cuboid represents a fusion of tarsals 4 and 5.

The **metatarsus** is made up of four long, slender **metatarsals**. On the medial side of the foot, just distad of the entocuneiform, notice a very small bone. This is the first metatarsal and is vestigial in the cat. In cases of polydactylism this digit is usually normal.

The terminal portion of the foot is made up of the **phalanges**. Compare these in number and arrangement with those in the hand.

Plate 22. Figure 37. Ventral Aspect of the Pelvic Girdle and Sacrum of the Cat.

Label completely and color ischium and pubis light brown; ilium light yellow.

Plate 22. Figure 38. Lateral Aspect of the Pelvic Girdle of the Cat.

Label and color as in the preceding figure.

Plate 23. Figure 39. Cephalic Aspect of the Right Hind Limb of the Cat.

Label completely according to the instructions given for Fig. 36.

CHAPTER II

THE MUSCULAR SYSTEM

Based on histological differences, three kinds of muscles may be distinguished in vertebrates, the involuntary or **smooth** muscles, the **cardiac** muscle, and the voluntary, skeletal or **striated** muscles. The smooth muscles are located, for the most part, in the walls of the hollow organs such as the viscera, blood vessels, and urinogenital tracts and in the integument and its derivatives. Cardiac muscle is found only in the heart and in certain of the larger blood vessels where they joint the heart. Owing to their distribution these two groups of muscles do not come within the scope of a course in gross anatomy. The skeletal muscles, on the other hand, form a large portion of the bulk of an animal's body. They keep pace with the general phylogenetic changes in vertebrates and, because of this, are of special interest in a comparative study. In the following studies, the term muscular system is used to include only the voluntary or skeletal muscles.

Divisions of the Muscular System. The voluntary muscles may be divided into three groups, metameric, branchiomic and integumentary.

The **metameric muscles** include most of the muscles of the body. They originate from the myotome of the paraxial mesoderm. From their embryonic dorsal position, the myotomes grow, and extend ventrad between the parietal peritoneum and the integument to form the general musculature of the body wall. The muscles belonging to this group, since the somites are segmental structures, are segmented also, although in higher vertebrates their segmental nature may be obscured by secondary modifications. The horizontal septum divides this group of muscles into a dorsal **epaxial** and a ventral **hypaxial mass**. The **appendicular muscles** are derived from the metameric muscles.

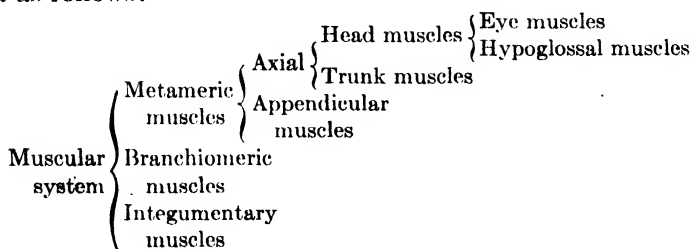
Except for the somewhat isolated groups of eye and hypoglossal muscles, metameric muscles are absent on the head. The **eye muscles** are those which move the eyeball within the orbit and

are developed from myotomes present on the head. The **hypoglossal muscles** are present in the tongue region, and while of metameric origin, they have moved into their definitive position from the occipital region which, strictly speaking, may not be considered as belonging only to the head region.

The **branchiomic muscles** differ in origin from the metameric muscles. The muscles of this group are associated with the primitive splanchnocranium and its derivatives. Unlike the metameric muscles, they develop from the mesoderm of the hypomere or lateral mesoderm rather than the paraxial mesoderm. In the gill region, the lateral mesoderm is interrupted by the gill slits. The visceral arches develop in this region, and associated with these the branchiomic muscles develop from the mesoderm of the region. In the higher vertebrates, the musculature of this region is complicated by the fact that certain metameric muscles, mentioned above, migrate into it and secondarily become associated with the indigenous muscles.

The **integumentary muscles** are not distinctive in origin. They develop as slips from either or both of the metameric and branchiomic groups. For functional reasons, they are considered as a separate group. They originate in their definitive position as slips from underlying muscles. They insert into the skin to produce movement of the integument or integumentary derivatives.

The divisions of the muscular system may be briefly summarized as follows:



The Relations of the Skeletal and Muscular Systems. The function of the muscular system is that of producing the necessary movement of a part or parts of the animal. In this function, it is aided by the skeletal system. The skeleton constitutes the supporting framework of the animal and is passive, therefore, in its inherent function. All movement of skeletal parts results

from muscular activity and this system is to be considered as the active agent in movement. The skeleton, in its shape and in the structure and relations of its elements, is an all but perfect reflection of the mechanical needs of the animal, conforming to the stresses and strains to which it is subjected by the action of the muscular system.

The Origin, Insertion and Action of Muscles. In the studies of the individual muscles which follow, the student should be familiar with what is meant by the terms, origin, insertion and action of a muscle.

The **origin** of a muscle is to be considered as the fixed end while the **insertion** is that end which is attached to the part to be moved. It is not always easy to determine which is the origin and which is the insertion. In cases where both ends are attached to movable parts, the designation of one end or the other as origin or insertion may be quite arbitrary.

By the **action** of a muscle, one means the movement produced by the muscle in contracting. In considering the action of a muscle, it is sometimes necessary to take into account the different positions of the bones and muscles involved, for the action may differ according to the varying position of these parts. Furthermore, rarely is any given movement the effect of a single muscle, but rather, the effect of several muscles acting jointly. The student should determine these group relationships.

As illustrated by their attachments, muscles do not always function with the greatest mechanical advantage in relation to the work they perform. Some of the factors, other than those of mechanical advantage, which affect the arrangement of muscles are as follows:

1. The need of keeping the appendages of the body from becoming heavy and ponderous.
2. The undesirability of large muscular masses near or over joints.
3. The necessity for rapidity of movement of parts.

In a general course such as this, time will not permit a complete and detailed study of the entire musculature of the three type forms. Accordingly, the muscles of a few regions only will be studied, but these are chosen to include examples of the major divisions of the muscular system. Furthermore, the fundamental principle underlying most modifications of the muscular system

can be illustrated as well by a study of the muscles of a few regions as by the musculature of the entire body.

It will be found that the number of movements possible, in an animal, is directly proportional to the number of muscles present. In brief, the simpler the functional demands upon the muscles, the simpler and more generalized will the system be. This principle should be borne in mind while comparing aquatic, transitional and terrestrial animals. It will be found that an animal buoyed up by the water in which it lives and moving about by lateral undulations of the body is in need of, and possesses, a much simpler system of muscles than a terrestrial species supported and propelled by its limbs.

Muscular System of the Shark.

Only the axial trunk muscles and appendicular muscles of the pectoral girdle will be studied at this time. A study of the eye muscles will be made later when the sense organs of the head are dissected.

The Trunk Musculature. The muscles of the trunk belong to the metameric group. Except for the relationships of the myosepta, this group in the shark is quite primitive.

In the region between the first dorsal fin and the pelvic fins, carefully remove the skin from the lateral surface on the left side of the trunk region. Remove this between the mid-dorsal and mid-ventral lines. Caution! The skin is firmly fastened by tough connective tissue fibers to the underlying muscles. Great care must be exercised to avoid injury to the muscles. After removing the skin, clean up the surface of the muscles.

Note the arrangement of the muscles in segments or **myomeres** which are separated by partitions of connective tissue called **myosepta** (singular, myoseptum). Observe that each myomere is divided into a dorsal and a ventral portion by the **horizontal septum**. The mass of muscle dorsal of this septum is the **epaxial mass**, that ventrad, the **hypaxial mass**.

Single out one myoseptum and trace its course across the body. How many times does it bend upon itself?

Determine the direction of the muscle fibers composing a myomere. Note that their arrangement is slightly different in the ventral part of the hypaxial mass. What movements are the fibers designed to produce?

In about the middle of the region from which the skin has been removed, single out one or two consecutive myomeres. Leave these undisturbed but carefully remove the muscle fibers of several myomeres anterior and posterior to them. Use the forceps to tear away the muscle fibers. Do not cut with the scalpel unless certain that no damage is being done to the myomeres which are to remain undisturbed.

Note that the myosepta do not extend directly inward at right angles to the vertebral column but are inclined forward and backward, the direction changing with each bend that the septa make in their course across the body.

Examine a cross section cut through the tail of the shark. Note the arrangement of the myosepta in this aspect.

With the fact in mind that muscles work only while contracting and that the force exerted while contracting is in the direction of the muscle fibers, deduce a functional explanation for the arrangement of the myosepta as they have been found to be in the above study.

Plate 24. Figure 40. Drawing of a Lateral Aspect of the Trunk Musculature of the Shark Showing Actual Relations of the Myomeres.

Complete the drawing provided by drawing in the inner margin of the myosepta of the dissected myomeres. Label completely.

The Musculature of the Pectoral Girdle and Limb. The muscles of the girdles and fins of the shark are called the appendicular muscles. They are classified with the metameric muscles, because to these they owe their origin.

As the myotomes grow down from their embryonic dorsal position to form the ventral musculature of the body wall, in the region of the fins, muscle buds are given off from the ventral margin of the myotomes. As the myotomes grow on ventrad of the fins, the muscle buds pinch off and are left behind to form the musculature of the girdle and fin.

Carefully remove the skin from the pectoral fin and adjacent body wall, on the left side, sufficiently to expose the entire pectoral girdle. Remove the fascia (a sheet or layer of more or less condensed connective tissue) covering the girdle and muscles.

Note that the pectoral girdle is embedded in the general musculature of the region. The appendicular musculature is comprised of three groups of muscle fibers so disposed as to form three muscle masses or groups named and described as follows:

The **elevator group** originates from the scapula of the girdle and from the fascia of the lateral body wall. Its insertion is on the dorsal surface of the fin. The fibers of the muscle are arranged in bundles which end in tendons that are continuous with the dermal actinotrichia of the fin. Study this insertion carefully and determine its relation to the skeletal elements of the fin. The action of the muscle is that of elevating and adducting the fin, that is, to lift and pull the fin in toward the body.

The **depressor group** originates from the coracoid portion of the girdle and inserts on the ventral surface of the fin. Its action depresses and adducts the fin.

The **abductor group** originates from the girdle anterior to the cephalic margin of the fin. It inserts upon the cephalic edge of the base of the fin. Its action abducts the fin, *i.e.*, pulls the fin cephalad away from the side of the body.

In the above study, determine precisely the exact part of the girdle from which the muscle masses take their origin. Which arises from the coracoid process? Which arises from the calcified area of the girdle?

The **trapezius** muscle lies anterior to the pectoral girdle. Its origin is from the skin and from the fascia of the underlying metameric muscles immediately dorsad of the horizontal septum just anterior to the scapula. Its fibers run caudo-ventrad and insert upon the anterior border of the ventral half of the scapula. Anteriorly, this muscle is continuous with a series of muscles associated with the several gill arches. It is considered to be a portion of this series of branchiomic muscles which has shifted its association from the visceral to the appendicular skeleton. In the future, it will be treated as an appendicular muscle. What is its action?

The pectoral fins of the shark are used mainly as balancing organs, and in this capacity they do not need to execute a great variety of movements. Would this account for the comparative simplicity of the musculature? Note that the elevator and depressor muscles are about equally developed. To what con-

clusion would this point as to the role of the fins in the support of the body?

Plate 25. Figure 41. Lateral Aspect of the Pectoral Musculature of the Shark.

In addition to the pectoral musculature, label the parts of the surrounding trunk musculature and the parts of the skeleton. Color visible parts of the skeleton light blue.

The Muscular System of Necturus

The muscular system of *Necturus* shows considerable advance in complexity over that of the shark. Walking appendages which enable the animal to amble over the substratum have replaced the fins. Movements of the fins in the shark were mainly extrinsic, but in walking, there is need for movement between the individual parts of the walking appendage as well as between the appendage and the body. Such movements are intrinsic or within the limits of the appendage, and intrinsic muscles are necessary to execute them. Definite muscles have arisen in place of the muscle groups found attached to the limbs in the shark. These muscles extend not only between body and limb but also between individual parts of the limb. The increase in the complexity of the muscles is in direct proportion to the number of movements which may be executed.

The Trunk Musculature. In the shark, the trunk musculature was concerned chiefly with locomotion, which function, in the four-footed animals, is taken over by the walking appendages. Correlated with this change in the mode of locomotion, the trunk muscles function in a new capacity. They are modified to support the body which is now suspended between walking appendages. Most urodeles, and *Necturus* in particular, are not well adapted in this respect, but certain modifications characteristic of terrestrial vertebrates are to be noted.

Examine the specimen of *Necturus* provided for the study of the muscles and notice that the segmentation of the trunk muscles is indicated externally by a series of transverse furrows. *Carefully remove the skin on the left side sufficiently to expose seven or eight complete, consecutive myomeres.*

Study the exposed muscles and compare with the trunk muscles of the shark. Locate the **horizontal septum** separating

the **epaxial** and **hypaxial masses**. Note that the myomeres are bounded by the myosepta as in the shark.

The greatest change in the trunk muscles of *Necturus* is the division of the hypaxial portion into layers, the fibers of each layer extending in a different direction.

The outer layer is the **external oblique** with the fibers extending caudo-ventrad. *Leave two myomeres at the anterior end of the skinned area to show the external oblique layer undisturbed. In the next two caudal myomeres, carefully remove the fibers of the external oblique to expose the next layer, the internal oblique, the fibers of which run cephalo-ventrad. Leave two myomeres of this layer exposed and in the next two succeeding myomeres remove the fibers of the internal oblique to expose the underlying transverse layer.* The fibers of this layer run nearly perpendicular to the long axis of the body. Note that this muscle terminates ventrally in a thin tendon. Care must be used not to destroy this tendon. It is sheetlike, very thin and transparent.

Is each layer of the hypaxial mass segmented? Compare the arrangement of the myosepta with that in the shark. Deduce a functional explanation for these differences in arrangement of myosepta and muscle fibers.

Using the directions given for the dissection of the epaxial trunk muscles of the shark, dissect this muscle mass in *Necturus*. What differences or similarities are to be noted?

Plate 26. Figure 42. Diagram of a Lateral Aspect of the Trunk Musculature of *Necturus* Showing :

- a. the External Oblique Layer.
- b. the Internal Oblique Layer.
- c. the Transverse Layer.

Label completely.

The Musculature of the Pectoral Girdle. The appendicular musculature originates differently in the tetrapoda than in forms possessing the fin type of appendage. Distinct muscle buds are not given off from the myotomes as in the fin type of appendage. There is, however, a diffuse migration of cells from the ventral margin of the myotomes. These cells push out into the limb bud, lose their original character and blend with the undifferentiated mesenchyme already present there. It is from this mixed, diffuse

tissue that the muscles develop in the place and relationships that they are to occupy in the adult animal.

On the left side of the animal in the region immediately caudad of the gills, remove the skin from the side of the body and fore limb. This should be removed from the mid-dorsal to the mid-ventral line and to a point about one inch caudad of the fore limb. Caution! Certain of the muscles to be studied are closely applied to the under side of the skin. To avoid injuring them, great care must be exercised in removing the skin.

*At this time the student should review from his records of previous work, the skeletal parts comprising the shoulder girdle and fore limb of *Necturus*. Without cutting any muscles, in the exposed shoulder region, locate the scapula, suprascapula, procoracoid and coracoid elements of the girdle.*

In the study which follows, the skeletal attachments of every muscle should be carefully determined. Do not remove muscles in determining these attachments. To expose underlying muscles, it is sometimes necessary to transect and reflect the more superficial muscles. To do this the muscles should be cut as nearly as possible at right angles to the fibers, and midway between the origin and the insertion. Never remove the separated ends of the muscle from their points of attachment.

On the side of the body caudad of the scapula is a fan-shaped muscle, the **latissimus dorsi**, the fibers of which converge for insertion upon the proximal end of the humerus. The origin of this muscle is from the fascia of the skin and the trunk musculature along a line paralleling, but somewhat dorsal to, the horizontal septum.

Cephalad of the latissimus dorsi is the **dorsalis scapulae**, the fibers of which originate from the ectal surface of the suprascapula and scapula and insert upon the humerus.

Cephalad of the dorsalis scapulae is the **trapezius**. This is a small muscle which originates from the side of the body anterior to the suprascapula and inserts along almost the entire anterior border of the osseous scapula. Recall that this is one of the branchiomic muscles which early becomes associated with the appendicular group.

Ventrad of, and somewhat paralleling the trapezius, is the **omohyoideus** muscle. It originates from the third epibranchial or from the connective tissue in that vicinity. It inserts on the

girdle in the notch between the scapula and procoracoid adjacent to the insertion of the trapezius.

The omohyoideus crosses, in its course, a small muscle, the **dorsolaryngeus**. This is not an appendicular muscle and hence will be described later. It should be noted here, however, since it is shown, and should be labeled on the plate showing the pectoral musculature.

The **procoracohumeralis** muscle covers the entire ental surface of the procoracoid. It originates from the anterior half of the procoracoid and inserts upon the humerus.

The paired **sternohyoideus** muscles are joined in the median line to form a broad, flat sheet of muscle covering the ventral surface of the animal between the procoracoids of the girdle. Differentiated from the ventral portion of the anterior myotomes, the sternohyoideus still preserves the primitive segmentation consistent with its origin. The lateral fibers of the muscle diverge laterally and insert on the ental surface of the procoracoid cartilage; the medial fibers continue caudad, passing dorsal to the coracoids of the girdle. *Do not follow this portion of the muscle until later when the girdle is removed from the body.*

The **rectus superficialis hypobranchialis posterior** muscle parallels the dorsal margin of the procoracohumeralis. It originates from the posterior surface of the first ceratobranchial and inserts upon the dorsal border of the procoracoid a short distance anterior to the insertion of the omohyoideus. Do not follow this muscle forward to its origin at this time. It may be seen later when the head muscles are dissected.

Turn to the ventral side of the animal and note the fan-shaped **pectoralis** muscle. This muscle has an extensive origin just lateral to the linea alba. From this the fibers of the muscle converge to insert upon the humerus. The **linea alba** is the common mid-ventral tendon of insertion of the trunk muscles of the two sides.

The pectoralis muscle partially overlaps the **supracoracoideus**. *Transect and reflect the pectoralis to expose the entire extent of this muscle. At its anterior margin, the fibers of the pectoralis muscle parallel those of the supracoracoideus, so care must be used in separating the two.* The supracoracoideus originates from the coracoid portion of the girdle and inserts upon the proximal end of the humerus.

Transect and reflect the latissimus dorsi. This will expose the **anterior serratus** muscle. It originates posteriorly by a series of three slips (serrations) from the myosepta. The slips converge and insert on the medial surface of the suprascapula.

The **levator anguli scapulae** muscle *may be exposed by transecting and reflecting the trapezius muscle.* This is a very thin band of muscle originating from the occipital bone of the skull and inserting on the medial surface of the anterior angle of the suprascapula. Do not follow this muscle forward to its origin. Like the trapezius, the levator anguli scapulae, although attached to the girdle, is a branchiomic muscle.

After the dissection of the muscles of the pectoral girdle has been completed and checked by the instructor, remove the limb and girdle from the body by carefully transecting all the muscles which attach the girdle to the body.

Notice that the trunk musculature under the girdle continues forward uninterrupted to the gill region.

Muscles of the Upper Arm. These muscles may be studied on the girdle and limb which has been removed from the left side of the body.

The largest muscle of the limb is the **triceps**. It covers the entire dorsal surface of the humerus and originates, as the name implies, by three heads from the humerus, scapula and coracoid, respectively. The **humeral** and **scapular heads** are lateral in position, and of these two, the humeral is the more ventral. The **coracoidal head** of the triceps may be seen on the inner surface of the arm originating from the coracoid portion of the girdle a short distance caudad of the ossified scapula. All three heads of the muscle converge and insert on the olecranon process of the ulna. *Loosen the muscle at its insertion and carefully work out the slips of origin.*

Ventral to the triceps and covering the ventral surface of the humerus, locate the **biceps**. The muscle originates from the proximal end of the humerus and inserts on the proximal end of the radius. *To see its insertion, it is necessary to dissect away the muscles of the fore arm which overlie it.*

On the ventral or anterior face of the humerus, the **coracobrachialis** muscle may be located paralleling the biceps mesally. It originates from the coracoid just ventrad of the origin of the

coracoid head of the triceps and inserts along the inner side of the distal end of the shaft of the humerus.

On the mesal surface of the girdle note a small muscle, the **scapulohumeralis** which originates in the notch between the coracoid and the posterior margin of the scapula. *To expose this muscle completely, it will be necessary to transect the coracoid head of the triceps which overlaps it. Push aside the triceps and coracobrachialis muscles and follow the scapulohumeralis to its insertion on the inner face of the distal end of the humerus.*

It is impossible to homologize the appendicular muscles of *Necturus* with those in the shark since they develop differently, but they may be compared in respect to the function which they perform. Which of the above muscles may be compared with the elevator mass in the shark? Which with the depressor? Which with the abductor? What is the functional explanation for the structural complexity of the shoulder musculature of *Necturus* compared with the relative simplicity of the shark?

Plate 27. Figure 43. Drawing of the Lateral Aspect of the Muscles of the Shoulder Region of *Necturus*.

Label completely and color visible skeletal parts light blue. In all drawings of the muscular system, when muscles are shown as transected or reflected from their original position, it should be indicated in the labeling.

Plate 28. Figure 44. Drawing of the Ventral Aspect of the Muscles of the Shoulder Region of *Necturus*.

Label and color as in the preceding figure.

The Muscles of the Head and Visceral Skeleton. The muscles of the head of *Necturus* are derived from two sources. The lateral mesoderm adjacent to the visceral arches forms the branchiomeric muscles. These muscles are accordingly indigenous to the region. In addition to these, there are others present which are of somitic origin. In *Necturus*, the first three somites back of the occipital region contribute mesenchyme from which certain of the muscles of the head, called the **hypoglossal muscles**, are formed. In the following study, no separation of these two groups of muscles will be made, but the fact that two groups of different origin are present should be understood.

Carefully remove the skin from both sides of the head of the animal. Do not remove the skin from the external gills.

The **masseter** muscle extends from the jaw backward and inward over the postero-lateral portion of the skull. To expose the tendon of insertion of this muscle it will be necessary to remove the eye and the lower lip. Determine accurately its attachments. On a dried skull locate the place of origin. What is the action of this muscle?

The **temporalis** muscle lies on the top of the head, mesad of the masseter. The tendons of insertion of this muscle lie beneath the masseter muscle which should be reflected at this time. *In reflecting the masseter, do not transect it but remove it from the skull at its point of origin. Leave it attached at its insertion.* Note that the anterior and posterior parts of the temporalis muscle have separate tendons of insertion. The tendon of the posterior part of the muscle is long and narrow and overlaps the tendon of the anterior part which is broad and thin. Locate accurately the skeletal attachments of the temporalis. Note that the tendon of the posterior part inserts on the jaw anterior to the tendon of the anterior part of the muscle.

The **mylohyoideus** is a thin sheet of muscle extending between the two halves of the lower jaw and as far caudad as the **gular fold**. The gular fold is the deep groove separating the head from the trunk region. Caudad of the jaw the mylohyoideus, laterally, takes its origin from the fascia of the external ceratohyoideus, described below. *Transect the mylohyoideus along the mid-ventral line and reflect it laterad.*

The **geniohyoideus** muscles are exposed when the mylohyoideus is reflected. This is a pair of median muscles so close together that they appear as a single muscle. They originate from the trunk musculature between the anterior ends of the procoracoids and insert on the lower jaw, one on either side of the symphysis. *Transect and reflect the geniohyoideus on the left side.*

Reflecting the mylohyoideus will also expose the **external ceratohyoideus**. This is a large muscle which passes caudad of the caudal end of the jaw, extending from the region of the hypohyal cartilage of the hyoid arch to the distal end of the epibranchial of the first gill arch. What is its action? Note that some of the fibers of this muscle have an attachment to the caudal end of the lower jaw. What is the action of this part of the muscle?

The **levator branchiarum** is a small fan-shaped muscle on the dorsal side of the head just mesad of the external gills. Determine its relations and action and then *carefully dissect it away from its origin on the body, but leave it attached at its insertion.*

On the side from which the masseter muscle has been reflected, locate the **depressor mandibulae** or **digastric** muscle. This is a small muscle just laterad of the skull paralleling the squamosal bone. It is bounded laterally by the external ceratohyoideus. Determine its origin, insertion and action.

Caudad of the digastric, originating from the lateral side of the opisthotic bone, is a small muscle, the **levator arcuum branchiarum**. It inserts upon the dorsal side of the distal end of the epibranchial of the first gill arch. What is its action?

Turn to the ventral side of the animal. Lift up and reflect laterad the caudal margin of the ventral portion of the external ceratohyoideus. This will expose the small **internal ceratohyoideus** extending caudo-laterad along the ceratobranchial of the first gill arch. Determine its origin, insertion and action.

The **constrictor arcuum branchiarum** is a small muscle extending from the base of the first epibranchial across the second and attaching to the base of the third epibranchial cartilage. What is its action?

The **depressor arcuum branchiarum** inserts on the caudal margin of the third epibranchial cartilage. Its origin is from the mid-ventral line of the pharynx directly over the heart cavity. What is its action?

At this time again locate the **dorsolaryngeus** muscle, mentioned above as being crossed by the omohyoideus. Follow the dorsolaryngeus from its origin on the side of the body just caudad of the levator branchiarum and notice that ventrally it passes deeply beneath the trunk muscles and inserts along the laryngeal cartilage and trachea.

Review the entire study on the muscles of Necturus, checking up especially, at this time, those attachments of the appendicular muscles which could not be followed until after the dissection of the head muscles. Be prepared to demonstrate all or any part of the work to the instructor.

Plate 29. Figure 45. Dorsal Aspect of the Muscles of the Head and Visceral Skeleton of Necturus.

Label completely and color visible skeletal parts light blue.

Plate 30. Figure 46. Ventral Aspect of the Muscles of the Head and Visceral Skeleton of Necturus.

Label and color as in the preceding figure.

The Muscular System of the Cat.

The cat, well adapted as it is to terrestrial life and locomotion, is in need of a muscular system capable not only of a greater number of movements but, also, of greater precision of movement. A larger number of muscles than in the forms previously studied will be found in the cat to execute the greater number of movements necessary. Precision of movement comes not alone by an increase in the number of muscles. For precise movement, better coordination is also necessary. This coordination between parts of the body is a function of the nervous system, and in this respect, the cat is better equipped than lower forms. The nicety of movement possible in the cat, then, is due to the number and interaction of the muscles present. This fact should be borne in mind while dissecting and determining the action of the muscles of the cat.

The Trunk Musculature. While the study of this region is being made in the cat, the student should recall conditions in the shark and *Necturus* and, if possible, account for the differences encountered.

The Epaxial Trunk Muscles. These muscles, which were segmented in the shark and *Necturus*, have partially lost their segmental character in the cat and have become an intricate complex of muscles associated with the vertebrae and ribs. These will not be dissected.

The Hypaxial Trunk Muscles. Although no horizontal septum is present separating the dorsal and ventral trunk muscles, a deep furrow directly under the back muscles marks its former position. Below this furrow is found the hypaxial trunk or abdominal muscles. These have lost, almost completely, indications of their segmental nature. The obliquity of the fibers, which was seen for the first time in the amphibia, is retained in the mammal. In the subsequent study upon the abdominal muscles of the cat, note the direction of the fibers and compare with that in *Necturus*.

In the work which follows, make constant use of the mounted skeletons to determine the extent of and the skeletal attachments of the

muscles. On the embalmed specimen provided, expose the abdominal muscles as follows: Make a mid-ventral incision through the skin from the middle of the sternum to the pubic symphysis. From the anterior end of this incision, make a right angle cut on the left side, continuing the cut just caudad of the anterior limb dorsad as far as the mid-dorsal line of the back. From the caudal end of the mid-ventral incision, cut through the skin caudo-laterad to the knee. The flap of skin thus freed on three sides now may be carefully reflected dorsad and may be left attached on the mid-line of the back. Take care not to reflect the most superficial layer of muscle with the skin.

This most superficial layer of muscle, the **cutaneous maximus**, an integumentary muscle, is very thin and in many places is closely applied to the skin.

The cutaneous maximus muscle covers most of the entire side of the body. Its origin is from the outer surface of the latissimus dorsi, from the muscles of the arm in the axillary region, from the linea alba for a distance of two to three inches caudad of the base of the xiphoid process, and from the thorax over a line joining the axilla with the base of the xiphoid process.

From its origin at the points mentioned, the fibers of the muscle spread out fanlike and insert into the skin. The cranial fibers curve around the base of the fore limb and insert into the skin near the mid-dorsal line just caudad of the first thoracic vertebra. The fibers of the middle portion of the muscle parallel the mid-dorsal line and insert into the skin in the region of the root of the tail. The fibers of the caudal portion insert into the skin over the thigh and into the fold of skin stretching between the thigh and abdomen.

This muscle is not equally developed in all cats. Sometimes the muscle fibers do not form a continuous sheet but are somewhat scattered. More or less fat is also deposited in this layer. To what group does this muscle belong? What is its function?

Transect and reflect this muscle. To do this, cut as nearly as possible at right angles to the fibers and through their middle. Reflect the muscle leaving it attached to the skin at its insertion and to the underlying muscles at its origin. In this transection and in the dissections which follow on the cat, do not fail to consult the instructor when in doubt. A good dissection may depend on a few words of instruction or explanation.

Reflecting the cutaneous maximus will expose the **obliquus abdominis externus** muscle. This is a thin sheet of muscle covering the entire abdomen and the ventral part of the thorax. It has two points of origin.

Origin 1. From the last nine or ten ribs by means of as many muscle slips. The muscle slips end in short tendons which attach to the ribs. The slips of the external oblique interdigitate with similar slips of the anterior serratus muscle, to be studied later. This origin is covered dorsally by the latissimus dorsi, a large muscle covering a large portion of the lateral wall of the thorax, and covered ventrally by the pectoralis minor, a muscle of the chest. Lift up the caudal margins of these muscles and expose the slips of origin of the external oblique.

Origin 2. From the dorsolumbar aponeurosis. This is a broad, thin tendinous sheet covering the lumbar portion of the back. This aponeurosis is common to the external and the internal oblique, described below.

The insertion of the external oblique is into the mid-line on the sternum from the seventh costal cartilage to the tip of the xiphoid process and from that point into the linea alba to the pubis. Just laterad of its insertion on the pubis, the tendon of the external oblique is perforated by the inguinal canal in the male cat. Note that the tendon of the external oblique is shortest at its anterior margin and that it becomes increasingly longer back toward its insertion on the pubis.

Transect this muscle about one inch out from its origin. Begin the transection at the anterior margin of the muscle. In doing this be careful not to injure the muscle lying directly underneath. Reflect the upper part of the muscle back toward its origin. Reflect the ventral part of the muscle toward its insertion. Caudad of the xiphoid process, the tendon of the external oblique is closely united to the superficial layer of the internal oblique. Do not attempt to separate them at this time. Cephalad of this point, the external oblique may be reflected to the mid-ventral line.

Reflecting the external oblique exposes the **obliquus abdominis internus** muscle. This muscle also covers the abdomen. Note that the direction of the fibers is at about right angles to those of the external oblique.

Origin 1. From the fourth to the seventh lumbar vertebrae, from the dorsolumbar aponeurosis which is common to it and the external oblique.

Origin 2. From an aponeurosis similar to the dorsolumbar aponeurosis but attached to the ventral half of the iliac crest.

Origin 3. By fleshy fibers from the three **crural arches**. These are three delicate ligamentous arches which stretch from the iliac crest to the pubis. The dorsal of the three gives exit to the iliopsoas muscle of the leg, the middle to the femoral blood vessels, and the ventral to the spermatic cord. In the female where the spermatic cord is not present, the middle and ventral arches may fuse.

The fibers of the internal oblique pass cranio-ventrad and end in a thin tendon which is inserted into the linea alba with that of the external oblique and with the tendon of the transversus, described below.

Compare the tendon of the internal oblique with that of the external oblique. Notice that, unlike the external oblique, it is widest at its anterior margin.

Transect the internal oblique. This cut should be made at right angles to the fibers and should be made to pass through the center of the muscle fibers. Such a cut will parallel the edge of the tendon about one inch laterad of where it attaches to the muscle fibers. Important! It is often very difficult to separate the internal oblique from the layer of muscle immediately beneath. This separation can be started best at the anterior margin of the internal oblique. The two layers being separated are quite thin and extreme care must be taken. Reflect the dorsal part of the muscle toward its origin. Reflect the ventral part of the muscle toward its insertion as far as the lateral edge of the rectus abdominis muscle. This is a straplike muscle extending longitudinally just to one side of the mid-line. Be very careful not to cut through the tendon or to reflect it farther than the lateral edge of the rectus abdominis. This dissection may be finished after a study of the rectus abdominis and its sheath is made. These are described below.

The **transversus abdominis** muscle is exposed by reflecting the internal oblique. The fibers of this muscle are nearly transverse. It has an extensive origin.

Origin 1. By fleshy fibers or a thin aponeurosis from the cartilages of all the false and floating ribs.

Origin 2. From the tips of the pseudo-transverse processes of all the lumbar vertebrae.

Origin 3. From the ventral border of the ilium and from the dorsal and middle of the crural arches.

The insertion is into the linea alba. This can be seen best after the rectus abdominis has been studied.

The rectus abdominis and its sheath. This muscle extends from its origin on the pubis cephalad to the first costal cartilage. Its insertion is covered by the pectoralis muscles and hence cannot be studied at this time.

The sheetlike tendons of the oblique and transverse abdominal muscles form a sheath around the rectus muscle. At the caudal end of the sternum, note that the rectus is ensheathed ventrally by the tendon of the external oblique and dorsally by that of the internal oblique. Follow the latter caudad and notice that about one-third of the way back to the pubis, this tendon splits into two layers and that for a short distance, the rectus is covered dorsally and ventrally by these layers. About half of the way back, the dorsal lamina of the tendon of the internal oblique terminates, and, then, from this point to the pubis, the rectus is entirely dorsad of the tendon of the internal oblique. For some distance caudad of this point, the rectus is ensheathed dorsally by the transversus abdominis. A short distance cephalad of the pubis, locate a similar split in the tendon of the transversus which enables the rectus to pass dorsad of this muscle and immediately ventrad to the peritoneum.

Complete the dissection of the tendons of the abdominal muscles so that the above relationships may be demonstrated.

Plate 31. Figure 47. Diagrams of a Cross Section through the Ventral Body Wall of a Cat:

- a. At a Level Just Caudad of the Sternum.
- b. At a Level about Midway between Sternum and Pubis.
- c. At a Level Just Anterior to the Pubis.

Draw in the rectus abdominis in its proper relations. Label completely and color: skin brown; cutaneous maximus blue; external oblique orange; internal oblique green; transversalis yellow; peritoneum red; rectus gray.

The Musculature of the Pectoral Girdle and Fore Limb. As in Necturus, only the muscles which attach the girdle to the body and the muscles of the upper arm will be studied in the cat.

The Muscles Connecting the Girdle and Arm with the Body. *In removing the skin for this dissection, proceed as follows. Begin-*

ning at the cranial end of the sternum, make two incisions. For the first, cut cephalo-dorsad to the middle of the lambdoidal crest and, for the second, cut caudo-dorsad over the point of the shoulder, just caudad of, and parallel with, the posterior border of the scapula to the last thoracic vertebra. Reflect this triangular flap as far as the mid-dorsal line, being careful not to get under the edges of any muscles and thus remove them along with the skin. Do this carefully and, if in doubt, ask an instructor for help. Leave this flap of skin attached to the mid-dorsal line.

This exposes the trapezius group of muscles, which arise from the spines of all the cervical and thoracic vertebrae and insert upon the spine of the scapula and upon the clavicle. The trapezius, a single muscle in the shark and *Necturus*, is divided into three distinct muscles in the cat.

The **spinotrapezius** is the most caudal of the three. Its origin is from the spines of the third or fourth to the twelfth or thirteenth thoracic vertebrae. The fibers pass ventro-cephalad, converging considerably for insertion along an S-shaped line which crosses the tuberosity of the scapular spine and forms an angle of about forty-five degrees with the spine. Above the spine, the insertion is into the fascia covering the supraspinatus muscle, below the spine, into the fascia covering the infraspinatus muscle. These latter muscles will be studied in detail later. The cranial two-thirds of this insertion is by a flat tendon.

In attempting to determine accurately the insertion of the spinotrapezius, it will be found to be covered by the next muscle of the trapezius group, the **acromiotrapezius**. *Transect the spinotrapezius, cutting from the middle of the anterior border to the middle of the posterior border. Reflect the anterior portion toward its insertion and the attachments described above can be seen clearly.*

Important! Refer constantly to the skeleton to locate accurately the origins and insertions of the muscles being studied.

The **acromiotrapezius** is a flat muscle just cephalad of the spinotrapezius. Its origin is along the mid-dorsal line from the spines of the third or fourth cervical to the third or fourth thoracic vertebrae. The fibers pass almost ventrad for insertion on the spine of the scapula from the metaacromion process to the point where the line of insertion of the spinotrapezius crosses the spine, and thence out into the fascia of the spinotrapezius for a short distance. Note that the anterior portion of the origin of

the acromiotrapezius is by fleshy fibers and that the posterior part is tendinous. This tendon crosses over the mid-line of the back and is continuous with the tendon of the same muscle of the opposite side. *Caution must be used to avoid destruction of this tendon. It is thin, colorless and often embedded in fat. If in doubt, have the instructor identify it for you.*

How does the action of the acromiotrapezius differ from that of the spinotrapezius?

The **clavotrapezius** is the most anterior muscle of the trapezius group. It covers the side of the neck and extends from the mid-dorsal line of the neck to the clavicle where it is continuous with the clavobrachialis, studied later. In animals such as the horse and cow, where the clavicle is lacking, the two muscles form one continuous muscle, called the cephalohumeralis.

The origin of the clavotrapezius is from the medial or dorsal half of the lambdoidal crest and the spines of the cervical vertebrae from the axis to the beginning of the acromiotrapezius. Its fibers pass caudo-ventral, covering the point of the shoulder and insert on the clavicle.

Transect and reflect the acromio- and clavotrapezius muscles. In doing so, be careful not to injure underlying muscles.

Reflecting the above muscles will expose the **rhomboideus**. This is a rather thick muscle originating from the spines of the last two or three cervical and the first four thoracic vertebrae. The fibers pass ventro-laterad and insert on the vertebral border of the scapula.

Just anterior to the rhomboideus, is a long, flat, narrow muscle, the **occipitoscapularis**. Its origin is from the lambdoidal crest underneath the clavotrapezius. The fibers pass almost directly caudad and insert upon the coracovertebral angle of the scapula just anterior to the insertion of the rhomboideus.

The **levator scapulae ventralis** is a thin straplike muscle with its origin on the transverse process of the atlas and the basioccipital bone of the skull. It inserts on the metacromion process of the scapular spine. The origin of this muscle cannot be worked out at this time.

Reflecting the clavotrapezius will expose the **cleidomastoideus** muscle. The origin of this muscle on the mastoid process of the skull cannot be seen at this time. It inserts on the clavicle on the ental surface of the clavotrapezius.

At this point, if it has not already been done, reflect ventrad along the arm, the flap of skin covering its lateral surface.

This will expose the **latissimus dorsi** muscle which covers nearly all of the lateral wall of the thorax. The cephalic border of this muscle is covered by the spinotrapezius. The origin of the latissimus dorsi is from the tips of the spines of the vertebrae from the fourth or fifth thoracic back to about the sixth lumbar. The posterior portion of its origin is from the dorsolumbar aponeurosis. The tendon of this portion of the muscle may be so closely applied to the underlying fascia that it cannot be reflected. The fibers pass ventro-cephalad, converging at the axilla and insert upon the medial surface of the humerus along with the tendon of the teres major, described below. This insertion must be studied in more detail when the muscles of the limb are dissected.

The latissimus dorsi is much more extensive in the climbing animals such as the primates. In man, it covers nearly the whole of the back. Compare this muscle with the same one in *Necturus* and account for the differences found.

Turn now to the ventral side of the animal. Extend the mid-ventral incision that was made through the skin in the dissection of the abdominal muscles to the anterior end of the sternum. Reflect this flap of skin from the mid-ventral line to the elbow of the fore limb.

The reflection of this flap of skin exposes the pectoralis group of muscles extending between the mid-ventral line of the thorax and the fore limb. In man, this muscle is divided into two parts, a superficial pectoralis major and a deeper pectoralis minor. In the cat, these two divisions are further subdivided into several more or less distinct muscles. With the fact in mind that the precision of movement possible is directly proportional to the number of muscles present, what conclusion may be deduced from the greater complexity of the pectoralis muscles in the cat as compared with man?

The first muscle seen in a ventral view on the cranial surface of the shoulder is the **clavobrachialis**. *This is not a pectoral muscle but it must be studied and transected before the pectoral muscles can be studied.* Its superficial fibers are continuous with the clavotrapezius muscle studied above; the deeper fibers have their origin on the clavicle. The union of the clavotrapezius and the clavobrachialis is marked externally by a fibrous connective-

tissue septum, called a **raphe**. The clavobrachialis passes **distad** along the cranial surface of the arm, growing narrower as it approaches the convexity of the elbow. It inserts with the tendon of the brachialis, to be studied later. Do not attempt to determine its exact insertion at this time.

The divisions of the **pectoralis major** may now be studied.

Just caudad of the clavobrachialis is the most superficial division of the pectoralis major, the **pectoantibrachialis**. It differs from the other parts of this muscle in that it inserts into the superficial fascia of the dorsal border of the forearm. Other parts of the pectoralis major insert upon the humerus. The pectoantibrachialis originates from the lateral surface of the manubrium of the sternum. *Transect and reflect this muscle.*

This will expose the other divisions of the pectoralis major, a **superficial** and a **deeper division**, the former a much narrower muscle overlying the anterior portion of the latter.

The superficial division originates from the manubrium, and the fibers extend caudo-laterad and insert upon the pectoral ridge of the humerus.

The deeper division originates from the whole cephalic half of the sternum and from the median raphe for about one centimeter cephalad of it. The fibers extend laterad and insert upon the humerus along a line which begins at the greater tuberosity and runs parallel to the deltoid ridge until this ridge meets the pectoral ridge. It then inserts along the pectoral ridge as far distad as the beginning of the last fourth of the humerus. From its caudal border, a slender slip is given off that inserts on the forearm.

Transect and reflect both of these muscles.

This exposes the **pectoralis minor**, which consists of **at least two** and sometimes three divisions: an **anterior**, an **intermediate** and a **posterior** portion. Work out the attachments of these divisions and compare with the attachments of the pectoralis major.

The **xiphohumeralis** is a long, thin, narrow muscle which may be considered as a part of the pectoralis minor. It originates from a median raphe along the xiphoid process and passes cephalo-laterad toward its insertion. The muscle ends in a flat tendon which is connected by strong fascia with the latissimus dorsi. It passes along the inner surface of the pectoralis minor and is inserted on the humerus near the bicipital groove.

Transect all the divisions of the pectoralis minor. This will expose the brachial nerve plexus and the blood vessels which pass to and from the arm. The blood vessels have been injected. Ligate these at two points and then transect them between the ligatures. Transect the nerves also.

Turn the limb dorsad and notice the large fan-shaped muscle extending between the vertebral border of the scapula and the body. This is made up of two muscles more or less completely fused together along their lateral margins.

The posterior of these two muscles is the **anterior serratus**. It originates from the first nine or ten ribs by as many muscle slips. The slips of origin of this muscle were seen when the origin of the external oblique was studied. Its insertion is into a narrow area on the medial side of the scapula near the vertebral border.

The anterior of the two muscles is the **levator scapulae dorsalis** which originates from the transverse processes of the last five cervical vertebrae. It inserts into a triangular area on the medial surface of the scapula near its vertebral border. The insertion of this muscle is continuous posteriorly with that of the anterior serratus.

Free the girdle and limb from the body now by transecting the remaining muscles by which it is attached.

The Trunk Muscles in the Thoracic Region. Before proceeding with the study of the girdle and limb muscles, note the muscles extending between the ribs. These are the intercostals and are divided into an external layer, the **intercostales externi**; a middle layer, the **intercostales interni**; and an inner layer, the **transversus thoracis**. These three layers correspond, respectively, to the external oblique, internal oblique and transverse muscles of the abdominal region. The ribs form in the connective-tissue septa which separate the muscle segments. The intercostal muscles are axial muscles like the abdominal muscles, but unlike them, they retain their primitive segmentation due to the presence of the ribs.

Between two of the ribs, anterior and above the origin of the external oblique, remove the fibers of the external intercostal to expose those of the internal intercostal. Determine the direction of fibers in each of these muscles and compare with the external and internal oblique muscles of the abdominal region.

The transversus thoracis will not be studied. It is restricted to a limited area in the thorax and cannot be dissected without injury to other parts which are to be studied later.

At this time, locate the anterior end of the rectus abdominis. Determine its insertion.

The Muscles of the Scapula and Limb. The muscles on the mesal surface of the scapula will be studied first.

The **coracobrachialis** is a very short muscle covering the medial surface of the capsule of the shoulder joint. Its origin is from the tip of the coracoid process, and its insertion is by fleshy fibers on the humerus a short distance distad of the lesser tuberosity. *Transect this muscle and carefully reflect it.*

The **teres major** is a muscle paralleling the caudal border of the scapula. It originates from the caudal border of the scapula and inserts upon the humerus along with the latissimus dorsi just distad of the insertion of the coracobrachialis.

The **subscapularis** is a broad muscle covering the whole medial surface of the scapula. It originates from the periosteum of the whole surface of the subscapular fossa. It inserts by a broad tendon that attaches along the whole length of the lesser tuberosity.

Turn now to the ectal surface of the scapula.

The two largest muscles on this surface of the scapula are the **supraspinatus** and the **infraspinatus**. The former is cephalad of the scapular spine, the latter, caudad. In addition to these, there are two smaller muscles on the ectal surfaces, the **spino-deltoides** and the **acromiodeltoideus** extending between the spine and the deltoid ridge of the humerus.

The spinodeltoideus is the muscle stretching between the middle third of the spine of the scapula and the deltoid ridge of the humerus. It inserts by means of a flat tendon which passes beneath, and it becomes very closely applied to the under side of the acromiodeltoideus muscle. Do not attempt to work out its insertion until the latter has been studied.

The acromiodeltoideus arises from the ventral end of the scapular spine from the metacromion to the tip of the acromion process. It inserts by means of fleshy fibers on the humerus along the deltoid ridge.

Carefully transect and reflect the two deltoideus muscles, and work out the relation of their insertions to each other. If in doubt concerning how to transect these, consult the instructor.

At this time carefully work out the insertion of the supra- and infraspinatus muscles. Transect these back about one-half inch from the shoulder joint and reflect the ventral parts toward their insertions.

The **teres minor** is a small muscle originating from the glenoid border of the scapula. The origin of this muscle begins at about one-fifth the length of the border from the glenoid fossa and extends to its middle. It inserts upon the humerus just distad of the infraspinatus fossa on the greater tuberosity.

The Muscles of the Upper Arm. On the inner surface of the arm, stretching between the lateral surface of the latissimus dorsi and the olecranon process of the ulna, is a thin, flat muscle called the **epitrochlearis**. Its origin is mainly from the lateral surface of the latissimus dorsi. Some of its fibers may originate from the pectoralis minor or the teres major. Its insertion is by a flat tendon closely associated with the tendon of the pectoantebrachialis into the dorsal surface of the olecranon process.

The muscles mentioned in the following paragraphs can be identified and dissected best from the lateral side of the arm.

The **triceps brachii**, as the name indicates, is divided into three portions. These are: a **long head** (caput longum), a **lateral head** (caput laterale), and a **medial head** (caput mediale).

The long head of the triceps brachii is a heavy muscle on the caudal surface of the arm, connecting the scapula and the olecranon process. Its origin is at the glenoid end of the caudal border of the scapula. Its insertion is by a thick tendon which passes over the grooved end of the olecranon process and attaches to a round tuberosity on the end of this process of the ulna. *Transect and reflect this muscle.*

The lateral head of the triceps brachii is cephalad of the long head and is seen on the lateral side of the arm. Its origin is by a flat tendon from the deltoid ridge and by fleshy fibers from the distal edge of the tubercle of insertion for the teres minor. It inserts by a flat tendon on the lateral border of the caudal surface of the ulna. Some of the fibers fuse with the tendon of the long head and some are also continuous with the **antebrachial fascia**. This is a strong connective-tissue covering of the muscles of the forearm. *Transect and reflect this muscle.*

The medial head of the triceps brachii is exposed when the long and lateral heads have been reflected. It is composed of three

portions, the long, the intermediate and the short. These extend along the caudal border of the humerus.

The **long portion** of the medial head originates from a triangular area near the head of the humerus. The base of the triangle is between the distal edges of the lesser tuberosity and the head of the humerus. Its apex extends for a short distance distad along the shaft from the lesser tuberosity. It inserts by a long, slender tendon in close association with the tendon of the intermediate portion, described below, into the proximal end of the ulna underneath the insertion of the long head of the triceps.

The **intermediate portion** of the medial head originates from the humerus distad of the origin of the long portion and inserts onto the medial border of the proximal end of the olecranon process.

The **short portion** of the medial head is a very short muscle originating from the bony bar which encloses the supracondyloid foramen. Its insertion is onto the medial border of the olecranon process, distad of the insertion of the long head of the triceps. How does the action of this muscle differ from the other parts of the triceps brachii?

Directly underneath the flat tendon of the lateral head of the triceps, on the outside of the elbow joint, is a triangular muscle, the **anconeus**. Its origin is from the distal end and the dorsal surface of the humerus. It inserts onto the lateral surface of the proximal end of the ulna.

The **biceps brachii** is the large muscle along the anterior surface of the humerus. It originates by a strong tendon from the bicipital tubercle of the scapula. The tendon of origin of this muscle passes through the deep bicipital groove. The biceps inserts onto the bicipital tuberosity of the radius.

After the long and lateral heads of the triceps brachii are reflected the **brachialis** muscle is exposed on the lateral surface of the humerus. It originates from a long triangular area, the apex of which is distad of the insertion of the teres minor. The margin of the muscle forming the posterior side of the triangle extends to the lateral supracondyloid ridge. The anterior margin of the muscle extends along the deltoid ridge to the middle of the shaft of the humerus. It inserts on the lateral surface of the ulna just distad of the semilunar notch. Review the insertion of the **clavobrachialis** at this time.

Plate 32. Figure 48. Ectal Aspect of the Scapula of the Cat Showing the Points of Muscle Attachment.

In this and the three figures which follow, label each area shown indicating the muscle attachment and whether it is the origin or the insertion of the muscle. Color according to instructions given by the instructor.

Plate 32. Figure 49. Ental Aspect of the Scapula of the Cat Showing the Points of Muscle Attachment.

Plate 33. Figure 50. Lateral Aspect of the Humerus of the Cat Showing the Points of Muscle Attachment.

Plate 33. Figure 51. Mesal Aspect of the Humerus of the Cat Showing the Points of Muscle Attachment.

CHAPTER III

THE NERVOUS SYSTEM AND SENSE ORGANS

The nervous system comprises **central** and **peripheral** portions. The former includes the **brain** and **spinal cord** while the latter includes the **cranial nerves**, the **spinal nerves** and the **sympathetic system** of nerves. In addition to these, the **sense organs** are to be considered as a part of the nervous system.

The sense organs are for the reception of stimuli and the remainder of the nervous system for the conduction and coordination of the impulses set up by the stimulated sense organs.

Nerve impulses are of two kinds, **sensory** and **motor**. Sensory impulses pass from the sense organs or periphery toward the central nervous system, while motor impulses originate in the central nervous system and pass out to the muscles and glands of the body. Within the central nervous system are coordinating centers which insure that a given sensory impulse excites the proper motor response. Depending upon the kind or kinds of impulses carried, nerves are designated as sensory, motor or mixed. A **mixed nerve** is one which carries both sensory and motor impulses.

Sensory and motor impulses may be further classified as **somatic** or **visceral**, depending upon the part of the body with which they are associated. Somatic impulses are those concerned with functions in the body wall; visceral, with those in the viscera. Visceral impulses are always carried by the sympathetic system of nerves. Four classes of nerves are recognized, therefore, contingent upon the kind of impulse carried and where the impulse is to be carried. These are somatic sensory, somatic motor, visceral sensory and visceral motor. A mixed nerve is one containing two or more of these four kinds of fibers.

A nerve is made up of only the processes of the nerve cells. The bodies of the nerve cells may be grouped within the central nervous system where they are called **nuclei** or grouped outside the central nervous system where they form the **ganglia asso-**

ciated with the cranial and spinal nerves and with the sympathetic system of nerves.

The Nervous System and Sense Organs of the Shark.

No attempt will be made at a detailed or phylogenetic study of the nervous system. Only sufficient detail will be noted to present the fundamental features of the nervous system of vertebrates as illustrated by the shark.

The following study of the nervous system and sense organs of the shark is made in the order in which it may be dissected most readily. The student must classify for himself each part as it is dissected and determine its relationship to the nervous system as a whole.

The Cutaneous Sense Organs. Review the work on the chondrocranium of the shark. Locate again and fix in mind the relationships of the various parts of the skull, especially the nerve foramina.

Before beginning the dissection of the specimen provided, note carefully the external relations of the eyes and nostrils. Note the relative position of the spiracles, gill slits and mouth. Locate the openings of the endolymphatic ducts by means of which the internal ears communicate with the exterior. These may be seen as two minute apertures, one a little to either side of the mid-line on the dorsal side of the head at the level of the spiracles. These ducts lead through the skull at the locus of the endolymphatic fossa which has been identified in the study of the skull. Notice many small pores distributed in the skin on both the ventral and dorsal sides of the head. These are the openings of cutaneous sense organs peculiar to fish forms and aquatic amphibia. They are of several kinds; the **sensory canal system**, the **ampullae of Lorenzini**, and **pit organs**.

The sensory canal system is made up of a series of connected tubes lined with sensory cells and opening to the surface by the minute pores noted above. The canals are embedded in the deep layer of the integument, but their position may be determined externally by the linear arrangement of the pores. The sensory canal system is divided into a **lateral line canal** on the body and a **cephalic canal system** in the head region. The lateral line canal may be seen extending from a point back of the otic capsule and above the spiracle to the tip of the tail. Notice that

in the tail region, the lateral line canal becomes an open groove. This canal follows the course of the horizontal septum.

The pit organs differ in histological structure from the other integumentary sense organs in the shark. Structurally, they resemble the taste buds of higher animals. The openings of one group of these organs may be located on the dorsal side over the gill region between the lateral lines. Another group of these organs is present cephalad of the first gill arch. This group is arranged more or less regularly along a crescentic line and extends down onto the ventral side.

The cephalic canal system and the ampullae of Lorenzini may be studied more readily after the skin has been removed from the head.

Locate again the apertures of the endolymphatic ducts. Carefully encircle these with an incision made just through the skin and, in subsequent dissecting, leave this island of integument undisturbed and in place. From this point forward to the tip of the snout, make a mid-dorsal incision through the skin. Continue this cut caudad of the endolymphatic pores to a point over the gill slits and then reflect the skin from the dorsal side of the head. Similarly, make a mid-ventral incision through the integument from the mouth forward to the tip of the snout and reflect the skin on the ventral side of the head. Caution must be used in reflecting the skin in order not to cut too deeply and thereby remove the cutaneous sense organs with the skin. Remove the skin in a single piece so that, in case some parts of the sensory canal system are removed, they may be studied on the skin.

If care has been used in removing the skin, the ramifications of cephalic canals may be followed. Follow the course of the **lateral line** forward on the body and notice, at about the level of the spiracle, the **supratemporal commissural branch** which crosses over just caudad of the openings of the endolymphatic ducts and connects the canals of opposite sides. A short distance cephalad of this point, the canal divides into two; the **supra-orbital** and **infraorbital canals**. The supraorbital canal passes forward above the orbit paralleling the lateral margin of the chondrocranium, and from a point just anterior to the anteorbital process, it extends forward almost to the tip of the snout. Then, forming a loop, it takes a sharp turn caudad to a point over the nasal capsule. From this point, it passes ventrad, caudad of the

nasal capsule, and at a point ventrad of the anterior margin of the eye, it meets the infraorbital canal. The infraorbital canal, after separating from the supraorbital canal over the spiracle, passes ventrad just anterior to the spiracle and, paralleling the ventral margin of the orbit, runs forward a short distance. It then turns caudad and, just anterior to the angle of the mouth, gives off the **hyomandibular canal**, a branch which extends a short distance caudad. After giving off the hyomandibular, the infraorbital canal extends forward to the point described above where it meets the supraorbital canal. From this point, it turns mesad a short distance and then forward, mesad of the nasal capsule, to the tip of the snout. A short **mandibular canal**, unconnected with the canal system described above may be seen just caudad of the lower jaw near the angle of the mouth. The innervation of the cephalic canal system, while not demonstrable in a gross study, is from branches of the seventh cranial nerve, to be studied later. The lateral line of the body is innervated partly by the ninth but mainly by the lateral branch of the tenth cranial nerve.

The **ampullae of Lorenzini** are divided into two large groups: the **superficial ophthalmic group**, on the dorsal side of the head mesad and anterior to the eye; and the **buccal group**, on the ventral side of the head, anterior to the mouth. The openings of these organs have been noted above. Beneath the skin, each pore leads into a canal of varying length which terminates in an ampulla. The nerves are attached to the ampullae. These are supplied by the fifth cranial nerve.

It has been experimentally demonstrated that the sensory canal system is concerned with the perception of disturbances in water. This sense of wave perception, while not directly comparable with the sense of hearing in terrestrial vertebrates, possibly serves a similar purpose in aquatic animals. At the present time, little is known concerning the exact function of the ampullary and pit organs.

Plate 34. Figure 52. Lateral Aspect of the Head of the Shark Showing the Cutaneous Sense Organs.

On the outline drawing of the head of the shark, draw in the sensory canal system, the ampullae of Lorenzini and the pit organs. Label completely.

The Nose. *Make a transverse incision enlarging the external nostril so as to expose the nasal or olfactory organ.*

The **external nostril** opens into a rather large chamber, the **olfactory sac**. This sac is lined with olfactory epithelium which is thrown up into numerous **Schneiderian folds** by means of which the sensory epithelium is greatly increased. Note that the olfactory sac ends blindly. In the shark, it is a sensory organ only and is in no way connected with the respiratory tract as in terrestrial animals.

The olfactory organ is innervated by the first cranial nerve, to be studied later.

The Eye. *On the left side, remove the gelatinous material and fibrous tissue surrounding the eye and completely expose the eyeball.*

When removing the eyelids, note that the skin on the inner side of the lid, the **conjunctiva palpebrarum**, is continuous with the skin over the exposed surface of the eyeball, the **conjunctiva bulbi**.

The Eye Muscles. *Carefully cut away the cartilage of the supraorbital crest, anterior to the postorbital process of the chondrocranium, to better expose the underlying structures. Be careful not to destroy any of the many nerves which pass through the orbit. These will appear as rather stout, creamy white strands of tissue.*

The eyeball lies in the orbit. Movement of the eye within the orbit is accomplished by six muscles, four of which are visible from the dorsal side. The **superior oblique** takes origin from the skull in the antero-medial side of the orbit and extends caudad, laterad and dorsad to insert upon the dorsal side of the eyeball. The remaining three muscles visible from the dorsal side have their origin close together on the skull in the postero-medial angle of the orbit. These are rectus muscles. The most anterior is the **internal** or **medial rectus**. It inserts on the anterior margin of the eyeball. The most dorsally situated of the rectus muscles is the **superior rectus**. Its insertion is very close to that of the superior oblique. The most caudal of the rectus muscles is the **external** or **lateral rectus** which inserts upon the caudal margin of the eyeball. Now, by reflecting the eye dorsally, the remaining two muscles of the eye may be exposed. The anterior of the two muscles thus exposed is the **inferior oblique**. It has its origin in the antero-medial angle of the orbit just ventrad of the superior oblique and inserts upon the ventral surface of the eyeball. Its

insertion is just anterior to that of the **inferior rectus**. The origin of the inferior rectus is in the caudo-medial angle of the orbit together with the other rectus muscles.

Note that the six eye muscles are arranged in three groups of antagonistic pairs, by the interaction of which, movement of the eyeball in various directions is effected.

The innervation of the eye muscles will be studied in detail later. Only the innervation of the superior oblique is obvious at this time. Be careful not to destroy the small nerve supplying this muscle.

The Structure of the Eyeball. *Free the eyeball from the orbit by cutting through the eye muscles at their point of insertion on the eyeball, and by cutting through the optic stalk a short distance from the eyeball. In removing the eyeball, be careful not to destroy the deep ophthalmic nerve which runs between the superior and inferior rectus muscles closely applied to its medial surface. It will also be necessary to transect the ciliary nerves which supply the eye. These are branches of the deep ophthalmic nerve and will be studied later.*

The conjunctiva of the eye has already been noted. Find again the cut margin of this layer where it was reflected onto the inner surface of the eyelids. This is not a coat of the eye, but represents rather the epidermis of the skin over the eye. The outer coat of the eye is the **sclerotic coat** or **sclera**. It is a tough fibrous connective-tissue coat. The transparent lateral portion of the sclera is the **cornea**. The conjunctiva and the cornea are closely fused together. Through the transparent cornea may be seen the darkly pigmented **iris** through which is an opening, the **pupil**.

Cut away the dorsal side of the eyeball so as to expose the interior. The internal structure of the eye may be studied to better advantage under water.

Toward the inside of the eye from the sclera may be seen a darkly pigmented layer, the **choroid coat**. Note that in the front part of the eye, the choroid coat leaves the sclera and forms a curtainlike structure in the front of a large spherical **crystalline lens**. This free portion of the choroid coat has been identified above as the iris and the opening through it, as the pupil. Just back of the iris, the choroid coat is thrown up into a series of radiate folds forming the **ciliary process** to which the lens is

attached by the **suspensory ligament**. Internal to the choroid coat is the **retina** which appears as a whitish layer and which oftentimes in preserved specimens is collapsed. The sensory portion of the retina extends around the eye only as far as the ciliary process. Another part of the retina, nonsensory in function and indistinguishable in a gross dissection, also covers the ciliary body and posterior surface of the iris. The point at which the optic stalk passes through the external coats of the eye and spreads out into the retina is plainly visible. This point is called the **blind spot**.

The lens together with its suspensory ligament divides the eye into two parts. The posterior cavity between the lens and the retina is filled with a peculiar mucoid tissue called the **vitreous body**. The cavity between the lens and the cornea is filled with a watery fluid, the **aqueous humor**. The iris divides the anterior cavity into two parts. That part of the cavity anterior to the iris is called the **anterior chamber**, while the much smaller space between the iris and the lens is the **posterior chamber** of the eye.

The retina is the sensory part of the eye, all other parts being subsidiary to it in function. Within the retina are to be found the sensory cells which are stimulated by light. The iris regulates the amount of light which passes through the pupil into the eye. The lens together with the aqueous humor and vitreous body focuses the light upon the retina. The choroid coat serves two major functions; it darkens the interior of the eye owing to its heavy dark pigmentation, and it serves as the vascular coat of the eye. The sclera is the protective capsule of the eye. Its origin is similar to the otic and olfactory capsules, but unlike them, it does not fuse with the chondrocranium. Were such a fusion to occur, movement of the eyeball within the orbit would not be possible.

Plate 35. Figure 53. Diagram of a Section through the Eye of the Shark.

Label completely.

The Innervation of the Eye Muscles. The innervation of the eye muscles may now be studied on the side from which the eyeball has been removed. In the orbit, notice again the origin of the eye muscles. Notice a cartilaginous stalk, the **optic pedicel**,

which extends outward between the rectus muscles. This attaches to the eyeball and functions in its support. Locate the **optic nerve**, the second cranial nerve, anterior to the rectus muscles. Dorsad of the optic nerve, locate the small **trochlear** or fourth cranial nerve which supplies the superior oblique muscle. Just caudad of the palatine process of the upper jaw and immediately dorsad of the attachment of the optic pedicel with the skull, the **oculomotor** or third cranial nerve makes its exit from the brain case. Trace its course and notice that almost immediately it branches to supply the superior and internal rectus muscles. These branches innervate the muscles near their origins from the skull. After supplying these, the oculomotor turns forward in front of the external rectus to supply the inferior oblique muscle. In doing so, as it crosses back of the inferior rectus, it gives off a branch to this muscle. Near where the oculomotor branches to supply the inferior rectus, it apparently branches also to supply the **posterior ciliary** nerve to the eyeball. This nerve was cut when removing the eye. Careful dissecting will show that this nerve is really a branch of the deep ophthalmic branch of the fifth cranial nerve, described later. The **abducens**, the sixth cranial nerve, supplies the external rectus. By reflecting this muscle sharply antero-dorsad, the abducens can be seen extending along its ventral border. The roots of the nerves supplying the eye muscles will be traced later when the brain and the cranial nerves are dissected.

Notice that the trochlear nerve innervates a single muscle, as also does the abducens, but that the oculomotor innervates four of the six eye muscles. What is the significance of this fact?

Plate 36. Figure 54. Lateral Aspect of the Orbit of the Shark with the Eyeball Removed Showing the Eye Muscles and Their Innervation.

On the sketch provided, draw in the innervation of the eye muscles and label completely.

The Ear. *Clean up the dorsal surface of the skull on the left side sufficiently to identify the elevations caused by the anterior and posterior semicircular canals. Begin to expose the membranous labyrinth of the ear by carefully cutting away the cartilage in thin slices from around the anterior semicircular canal. This canal arches; the*

dorsal part of the arch is not very deeply embedded in the cartilage. Be careful not to cut through it. In a similar fashion, expose the posterior and horizontal semicircular canals. The latter is situated more laterally and at a deeper level than the first two. By carefully removing the cartilage a little at a time, expose the entire membranous labyrinth. To do this, it will be necessary to expose a part of the brain adjacent to the ear. Use caution not to destroy it or any of its nerves.

Notice that the membranous labyrinth is entirely surrounded by cartilage, but that in some places there is a space between the cartilage and the membrane. In life this space is filled with the **perilymph** while the membranous labyrinth is filled with the **endolymph**.

Note that the **endolymphatic duct** leads from the dorsal surface through the skull. Within the cartilaginous labyrinth, it expands into a broad **utriculosaccular chamber**. In the preserved specimen, this will probably appear as collapsed. It is within this chamber that the **otoliths** or ear stones are lodged surrounded by the endolymph. These consist of a mass of calcareous material and may be partially or completely disintegrated in formalin-preserved specimens.

Posteriorly and ventrally the utriculosaccular chamber projects as a tonguelike structure called the **lagena**. The lagena of the shark is the rudiment or forerunner of the cochlea of higher forms. Dorsally the three **semicircular canals** open into the utriculosaccular chamber. This portion of the common chamber into which they open is sometimes designated as the **utriculus** since it corresponds to that part of the ear of higher forms. The ventral part of the common chamber corresponds to the **sacculus**.

Note that the semicircular canals are arranged in three planes; one, anterior and oblique to the long axis of the animal; a second, posterior and oblique; and the third, horizontal. Follow each of the semicircular canals around from its dorsal attachment to the utriculus and see that, at the end of its arc, each expands into an **ampulla**. The ampullae of the anterior and horizontal canals lie close together. It is in the ampullae that the branches of the auditory nerve terminate. These sensory areas may be identified as whitish patches in the membranous labyrinth. In addition to those in the ampullae, locate similar patches in the **lagena** and **sacculus**.

The Brain. *A part of the brain has been exposed while making the dissection of the ear. Now expose the remainder by carefully chipping away the cartilage a little at a time using caution not to destroy any of the nerves associated with it. Begin this dissection at the epiphysial foramen. Note that a thin stalk extends from the foramen down and backward toward the brain. Leave this stalk in place, if possible, while exposing the brain. The brain is covered by a thin membrane in which run its nutrient blood vessels. Delicate strands of tissue connect this membrane with the membrane lining the cartilaginous wall of the brain case. Cut these but leave the membrane and blood vessels around the brain in place for the time being.*

The Development of the Brain. The parts of the brain and their arrangement are better understood when viewed from the standpoint of development.

The brain develops as an enlargement of the anterior end of the neural tube. At first two annular constrictions appear in this enlarged end dividing it into the primitive forebrain or **prosencephalon**, the midbrain or **mesencephalon** and the hindbrain or **rhombencephalon**. During subsequent development, the prosencephalon is divided into **telencephalon** and **diencephalon**. Likewise, the rhombencephalon is divided into **metencephalon** and **myelencephalon**. The midbrain or mesencephalon is not further divided. Thus the adult brain is differentiated into five divisions, naming from the anterior end back, the telencephalon, diencephalon, mesencephalon, metencephalon and myelencephalon.

From the beginning, it is seen that the brain is a hollow structure, its lumen being continuous with that of the neural tube. During later differentiation, the lumen may be lost in some regions but retained in others to form the **ventricles** of the brain.

The Dorsal Surface of the Brain. Study the dorsal surface of the brain and identify the following parts in this aspect. Later, the brain will be removed from the skull to expose the ventral surface, and at that time the brain study will be completed.

The stalk mentioned above which leads back from the epiphysial foramen is the **epiphysial** or **pineal stalk**. Follow it and notice that it apparently ends in a network of blood vessels. This stalk is actually a thin slender sac, an evagination of the thin roof

of the diencephalon. The blood vessels here form a **choroid plexus** which pushes the thin roof down into the cavity of the brain. *Carefully remove this plexus of blood vessels. This will tear away the roof of the brain and expose the ventricle.*

The most anterior division of the brain, the **telencephalon**, is composed of a number of parts. The **olfactory bulbs** which may be seen as rounded masses immediately dorsad of the olfactory sacs are the most anterior. These are connected with the **olfactory tracts** which lead medio-caudad to the **olfactory lobes** which in turn join the **cerebral hemispheres**. The olfactory lobes and cerebral hemispheres appear to be almost a single structure since they are separated only by a broad shallow furrow. The telencephalon is concerned mainly with the sense of smell.

The next division of the brain is the **diencephalon**. Its roof has already been studied. This division serves mainly as a coordinating center for the chief senses; sight, hearing, smell, taste and skin sensations.

The **mesencephalon** is well developed as two large **optic lobes**. In these are centers of sight, hearing and skin sensations connected with those in the diencephalon.

The optic lobes are overlapped posteriorly by the **cerebellum** which constitutes almost the entire **metencephalon**. Laterally, in the groove between optic lobe and cerebellum, the trochlear nerve may be seen. Dorsally, the cerebellum is divided by a median groove into right and left halves. It may also be divided by a slight transverse groove so that it appears to be separated into quadrants. This division of the brain is the center of coordination of the motor impulses and equilibrium.

Posteriorly the cerebellum overlaps the most caudal division of the brain, the **myelencephalon** or **medulla oblongata**. The anterior end of the medulla oblongata extends dorsally under the cerebellum and on each side projects laterally to form the **restiform bodies**. Caudad of these, the medulla narrows in diameter and joins the neural tube. The posterior limit of the medulla is marked by the posterior limit of the skull rather than by any structural difference between it and the neural tube. A choroid plexus is formed over the roof of the medulla. When this is removed, the thin roof of the medulla tears away leaving a large opening, the **fossa rhomboidalis**, into the ventricle of the myelencephalon. Functionally, the medulla is a complicated region

of the brain. It is concerned with all the senses except smell, taste and sight which are centered in the more anterior regions of the brain. The importance of this region will be appreciated more after the dissection of the cranial nerves, when it will be found that all except the first four of these nerves are associated with this single region of the brain.

The Cranial Nerves. *Further dissecting will be necessary to expose the cranial nerves. This is particularly true in the region of the ear which may be removed now to expose the underlying cranial nerves. The nerves are described in the order in which they are most readily dissected rather than in their numerical order.*

The **first** or **olfactory nerve** has its origin in the epithelium lining the olfactory sense organ. From this, short fibers lead back to the olfactory bulb just dorsad of the olfactory sac. The olfactory bulb is connected to the olfactory lobe of the brain by the olfactory tract. This is purely a sensory nerve. It may be possible to follow the **terminal nerve**. This is a slender nerve which extends between the olfactory sense organ and the olfactory lobe. It crosses over the dorsal surface of the olfactory bulb to the medial side of the tract and enters the olfactory lobe near the median line.

The **second** or **optic nerve** has its origin in the retina of the eye, passes inward as a thick stem through the optic foramen and enters the diencephalon. Before entering the diencephalon, each optic nerve crosses over and enters on the side opposite from that on which it originates. This point of crossing of the optic nerves is called the **optic chiasma**. This will be seen later when the brain is removed from the skull. The optic nerve is purely a sensory nerve.

The **fourth** or **trochlear nerve**, mentioned above, arises apparently from the roof but actually from the floor of the mesencephalon and emerges in the groove between the optic lobe and cerebellum. It extends slightly forward, then sharply laterad to pierce the cranial wall and innervate the superior oblique muscle of the eye.

The **third** or **oculomotor nerve** arises from the floor of the mesencephalon. It can be seen readily at a level just caudad of the palatine process of the lower jaw by carefully pressing the brain mediad away from the wall of the brain case. Trace it to its exit from the cranium. Its branches to the several muscles

which it innervates have already been identified but should be reviewed again.

The **sixth** or **abducens nerve** originates from the ventral side of the anterior end of the medulla. Its origin will be identified later when the ventral side of the brain is exposed. It emerges from the skull into the orbit just ventrad of the origin of the external rectus muscle and has been seen as a white ridge on the ventral surface of that muscle which it supplies.

The third, fourth and sixth nerves supplying the six eye muscles are all somatic motor nerves.

The **fifth** or **trigeminal** and the **seventh** or **facial** nerves are so intimately united that a microscopic examination is necessary for their separation. Both originate from the anterior end of the medulla. All of the trigeminal and most of the facial pass through the skull into the orbit together.

Carefully expose them by chipping away the surrounding cartilage.

Immediately after passing into the orbit, the trigeminal divides into the superficial ophthalmic, deep ophthalmic, maxillary and mandibular branches. The **superficial ophthalmic** branch is a part of the large superficial trunk which runs forward through the dorsal part of the orbit and emerges upon the dorsal surface of the skull through the superficial ophthalmic foramen. After leaving the orbit, it is distributed to the ampullae of Lorenzini and to the skin dorsal to the rostrum. The second branch of the trigeminal, the **deep ophthalmic** nerve, has already been seen on the side from which the eye has been removed. It runs forward attached to the medial side of the eye and leaves the orbit through the deep ophthalmic foramen to emerge on the dorsal side of the skull. There it joins with the superficial ophthalmic and is distributed in common with it. Before leaving the orbit, the deep ophthalmic gives off the **anterior ciliary** nerve into the eye. Recall that the **posterior ciliary** nerve, described earlier with the oculomotor nerve, is also a branch of the deep ophthalmic, given off near its root.

To see the remaining two branches of the trigeminal, study the side from which the eye has been removed. They lie in the floor of the orbit.

The **maxillary** branch of the trigeminal, together with the **buccal** branch of the facial described below, composes the **infra-orbital** trunk which extends cephalo-laterad across the floor of the

orbit and out onto the ventral side of the head. After leaving the orbit, the maxillary nerve is distributed to the skin and the ampullae of Lorenzini below and anterior to the eye. The **mandibular** nerve, the last branch of the trigeminal, is given off posteriorly from the trigeminal near its root and crosses the back of the orbit to be distributed to the muscles of the jaw and to the skin and ampullae of the lower jaw.

All of the branches of the trigeminal are somatic sensory nerves coming from the skin and cutaneous sense organs. In addition, the mandibular branch, since it innervates certain of the visceral muscles of the first arch, is a visceral motor nerve. In other words, the trigeminal is a mixed nerve, bearing both motor and sensory fibers.

The facial nerve, together with the trigeminal, arises from the anterior end of the medulla. It almost immediately divides into three main branches. One branch, the **superficial ophthalmic**, accompanies the similarly named branch of the trigeminal nerve. The two nerves are inseparably bound together to form the **superficial ophthalmic trunk**. Before and after leaving the orbit, the superficial ophthalmic branch of the facial supplies the supra-orbital branch of the cephalic canal system. The second branch of the facial, the **buccal**, has already been noted as making up a part of the **infraorbital trunk**. It is distributed to the infraorbital branch of the cephalic canal system. The third branch of the facial nerve is the **hyomandibular trunk**. It leaves the medulla caudad of the other branches. *To expose it, it will be necessary to remove the ear since it passes ventrad to some of the branches of the auditory nerve.* Near its attachment to the brain it has an enlargement or ganglion in its course. Expose this ganglion carefully and note that it gives off a branch from its ventral side. This is the **palatine** nerve which is distributed to the taste buds and epithelium lining the mouth. Distad of the ganglion, the hyomandibular nerve runs caudad of the spiracle and branches to supply hyomandibular and mandibular canals of the cephalic canal system, also the ampullae and pit organs, the muscles of the second arch and the epithelium of the floor of the mouth.

The superficial ophthalmic and buccal branches of the facial are sensory nerves. These nerves are lost in terrestrial vertebrates not possessing a lateral line system. The hyomandibular branch of the facial is a mixed nerve being made up of somatic

and visceral sensory and visceral motor fibers. In terrestrial animals, those branches of the hyomandibular which supply the cephalic canal system, the ampullae and pit organs, disappear leaving only the palatine and a branch supplying the muscles of the second arch. In terrestrial vertebrates this is the facial nerve.

The **eighth** or **auditory nerve** has been seen in part while dissecting the ear. Note again its branches to the various parts of the ear and follow it into the brain. It is purely a somatic sensory nerve carrying as it does only impulses for hearing and for equilibrium from the ear to the brain.

The **ninth** or **glossopharyngeal nerve** arises from the medulla caudad of the auditory nerve and passes caudo-laterad under the membranous labyrinth of the ear. *Dissect away as much of the ear capsule as is necessary to expose it.* It extends to a point just dorsad of the first gill slit and there divides into three branches. Two small branches pass anterior and one large branch posterior to the gill slit. Of the two anterior branches, one is the **pharyngeal** which is a sensory nerve to the mouth cavity, and the other is the **pretrematic** which is a sensory nerve to the anterior wall of the gill slit. The large caudal branch is the **posttrematic**. It is both sensory and motor in function, supplying the muscles of the third visceral arch as well as the epithelium lining the posterior side of the gill slit. In addition to the branches described above, the glossopharyngeal gives off a slender branch dorsally to supply the anterior end of the lateral line canal. This probably has been cut away during the dissection.

The **tenth** or **vagus nerve** has the widest distribution of any of the cranial nerves. It is attached laterally to the posterior part of the medulla. Dissect it out and follow it caudo-laterally. Soon after leaving the skull it branches into two trunks. The medial trunk is the **lateral branch** which passes, deeply embedded between epaxial and hypaxial muscle masses, almost to the tip of the tail. It supplies along its course the lateral line canal. By careful dissecting back toward the brain, the lateral branch can be separated from the other trunk of the vagus and can be seen attached to the medulla anterior to the other trunk which is the **visceral branch**. Follow the visceral branch caudad. It will be seen to give off four branches, one to each of the four remaining gills. Recall that the first gill was supplied by the glossopharyngeal. Each of the four branches of the vagus to the gills is similar

to the glossopharyngeal in respect to branches and to the function of their branches. Caudad of the branchial region, the visceral branch is continued as the **intestinal** nerve to supply the heart, digestive tract and other viscera. Like the glossopharyngeal, the intestinal is a mixed nerve. It need not be dissected.

The Spinal Cord and the Occipital and Spinal Nerves. *Clear away the thick trunk muscles over the neural arch of the vertebral column for a short distance caudad of the skull. Pare away the dorsal part of the neural arch in very thin slices and, in this way, expose the dorsal root of the spinal nerves.*

The **dorsal roots** perforate the intercalary plates of the neural arch. Near the entrance of each into the spinal cord, note a slight swelling. These are the **spinal ganglia**. Carefully press the spinal cord away from the side of the neural canal and notice the **ventral roots** of the spinal nerves. These leave the ventral side of the nerve cord by several small rootlets. The ventral root pierces the neural plate of the neural arch. Laterad of the neural arch, the ventral root joins with the dorsal root passing through the next intercalary plate caudad to form the **spinal nerve**. This union is hard to demonstrate in the shark and need not be attempted. The dorsal root is sensory and the ventral root is motor, so beyond their union, the spinal nerve is a mixed nerve.

Between the first spinal nerve and the point where the *vagus* leaves the medulla, carefully press aside the medulla and notice two or three small nerves leaving the ventral side of it. These are the **occipital** nerves from which, together with a contribution from the first spinal nerve, is formed the trunk supplying the hypobranchial muscles. This nerve need not be dissected out. Recall that the dorsal parts of the occipital somites, the ventral parts of which form the hypobranchial muscles, disappear and with them are lost the dorsal roots of their nerves.

The Ventral Surface of the Brain. *Carefully free the brain from the skull by cutting through the olfactory tracts and by gently lifting the anterior end first. Next, the large optic nerves will be seen. Cut these where they enter the brain case and reflect the brain a little farther. Next, a large structure will be seen projecting from the ventral side of the diencephalon. Free this carefully from the depression in the floor of the brain case in which it rests. Then cut through the remaining cranial and spinal nerves, also across the nerve cord and lift the brain free from the brain case.*

Examine the ventral surface of the brain. Note that in this aspect, only the diencephalon presents structures which need special comment. Follow the optic nerves to the floor of the anterior part of the diencephalon. Here they cross, the point of crossing being called the optic chiasma, mentioned above. From the optic chiasma, the optic tracts may be seen extending caudo-dorsally and entering the optic lobes of the mesencephalon. Just caudad of the optic chiasma is a large ventral outgrowth of the floor of the diencephalon, the **hypothalamus**. The depression in the floor of the brain case in which this is housed is the **sella turcica**. The hypothalamus consists of two rounded **inferior lobes** and the **hypophysis** or **pituitary body**. The latter projects as a stalk from between the inferior lobes and widens out into a soft sac. This may have been torn away while removing the brain from the brain case. If so look for it in the sella turcica. The hypophysis is formed partly from the brain and partly from an evagination from the pharynx. Locate the point where the pharyngeal component is attached to the floor of the sella turcica. In those animals where the function of the hypophysis has been determined, it is a gland of internal secretion.

Caudad of the diencephalon, the ventral surface of the brain presents no new structures, but in this aspect, again identify the cranial nerves associated with the medulla.

The Ventricles of the Brain. *Make a mid-sagittal section through the brain.*

As already noted, the brain, like the nerve cord, is hollow and its cavities, called the **ventricles**, are connected by narrow passages. The cavity of the myelencephalon, or **fourth ventricle**, was noted when the chorioid plexus of the medulla oblongata was removed, taking with it the thin roof of this division of the brain. The fourth ventricle communicates anteriorly by the **aqueduct** with the **cerebellar ventricle** in the cerebellum and the optic ventricles in the optic lobes. Anteriorly, the aqueduct also opens into the cavity of the diencephalon, the **third ventricle**. The roof of this division of the brain has possibly been torn away because here a chorioid plexus similar to that in the myelencephalon is present. Its parts will not be described, but together they form the **epithalamus**. The lateral walls of the diencephalon form the **thalamus**, and the ventral wall, as already noted, the **hypothalamus**. Anteriorly the third ventricle communicates by a passage, the **foramen of Monroe**, with the cavities of the olfac-

tory lobes of the telencephalon. These are the **first** and **second** or **lateral ventricles** of the brain.

Plate 37. Figure 55. Dorsal Aspect of the Brain, Sense Organs and Cranial Nerves of the Shark.

Label completely.

The Sympathetic System of Nerves. All the relations of the parts of the sympathetic system to each other and to the central nervous system cannot be observed in a gross anatomical study. This is especially true in the shark, and no attempt will be made to study this system in this animal. Later, when the vascular system of the cat is being dissected, to get as clear a conception of this system as possible from a gross dissection, attention will be called to those parts of the sympathetic system which may be readily dissected and observed. These will be certain of the ganglia and their connections.

The description of those parts of the cat to be observed is recorded here for future reference.

The Gross Anatomy of the Sympathetic System of the Cat. Locate again the ganglia exposed while dissecting the superior mesenteric artery. The larger and more dorsal of these is the **coeliac** or **semilunar ganglion** and the smaller and more ventral, the **superior mesenteric ganglion**. Notice that the two are connected by a pair of rather large trunks. From the coeliac ganglion, an anastomosing group of nerves, called the **coeliac plexus**, is given off anteriorly. This plexus follows the coeliac artery to the viscera supplied by the artery. Branches from the superior mesenteric ganglion form the **superior mesenteric plexus** which innervates the lower part of the intestine. Posteriorly, the coeliac and superior mesenteric ganglia give off branches which form the **aortic plexus** around the dorsal aorta. This plexus is connected with a number of plexuses in the pelvic region, only one of which, the **inferior mesenteric plexus**, will be noted. Through the inferior mesenteric plexus, the coeliac and superior mesenteric ganglia are connected with the **inferior mesenteric ganglion** which has already been observed along the inferior mesenteric artery. Work out these relationships as completely as possible.

Carefully dissect from the coeliac ganglion toward the dorsal aorta. If possible, locate two branches given off dorsally. Follow these, the anterior one of which is the **great splanchnic nerve**,

and the posterior, the **lesser splanchnic nerve**, and see that they join the large **sympathetic trunk**. The great splanchnic nerve pierces the diaphragm to join the sympathetic trunk anterior to the diaphragm. The sympathetic trunk parallels the vertebral column just laterad of the centra of the vertebrae. Follow this trunk caudad and notice the segmental swellings or **chain ganglia**. The chain ganglia are connected with the segmental nerves of the peripheral nervous system. These connections may not be seen in a gross dissection. There are two sympathetic trunks, one on either side of the vertebral column.

Follow the sympathetic trunk forward through the thoracic cavity and notice that in the cervical region it joins with a large nerve, the **vagus** or tenth cranial nerve. The branches of the vagus or other ganglia and branches of the sympathetic trunk will not be dissected.

The parts described above, incomplete as they are, have been called to the attention of the student to point out that all parts of the viscera are supplied by nerves just as all muscles and other parts are supplied by nerves. Nerves supplying the viscera belong to the sympathetic system which is a part of the peripheral nervous system. By way of the spinal and cranial nerves, the sympathetic system is connected with controlling centers in the brain and cord.

CHAPTER IV

THE VISCERA

Under this heading are grouped the digestive, respiratory, urinary and genital systems. It is more convenient to study these systems together in the several vertebrate types, than to trace each system separately.

THE DIGESTIVE AND RESPIRATORY SYSTEMS OF THE SHARK

Although distinct functionally, the digestive and respiratory systems are structurally related. In some animals, respiration may be accomplished through the surface of the body, but in most vertebrates, the modifications of the integument are so diverse and profound that special organs have developed in all classes to provide for the respiratory needs of the animal. These organs, whether of the gill type possessed by aquatic vertebrates, or of the lung type possessed by terrestrial animals, develop from modifications or outgrowths of the digestive tube. It is because of this structural relationship that these systems are treated together.

The Mouth or Oral Cavity and the Pharynx. The oral cavity represents the stomodeum of the embryo and is lined, therefore, with ectoderm, but in the adult animal, this cavity is not delimited from the entodermally lined pharynx which follows. These cavities, accordingly, will be studied together. It is with the pharyngeal portion of the digestive tube that the respiratory organs are associated.

On the specimen supplied for dissection, note the number of external gill openings or **gill slits** on each side. Locate the **spiracles** opening dorsally, cephalad of the first gill slit.

Enlarge two consecutive gill slits by cutting dorsally and ventrally towards the meson of the animal. The spaces which open to the exterior by means of the gill slits are called the **gill chambers**. The **gill chambers** are separated from each other by the **gill septa**. Note a more or less elliptical row of **gill filaments** on both the

anterior and posterior surfaces of a typical gill septum. Examine the gill filaments carefully. Approximately how many are there on each side of the gill septum? What is the reason for this relatively large number? Is the epithelial covering of the filaments continuous with the lining of the pharynx? The gill filaments borne on one side of the gill septum constitute a **demibranch**. The two demibranchs borne on the anterior and posterior surface of a given gill septum constitute a **gill** or **holobranch**.

Dissect out an entire gill. Notice its skeletal support, the **gill arch**. Projecting from the arch toward the pharynx are the **gill rakers**. Are gill filaments borne by all divisions of the gill arch?

With a sharp knife or razor blade, cut a section through the gill which will transect the gill arch and at the same time parallel the gill filaments. Examine this section closely.

Note the central blood vessel which appears, cut in cross section, just laterad of the gill arch in the connective tissue between the two demibranchs. This vessel is the **afferent branchial artery** which brings blood to the gill. Tease apart the two demibranchs and note the small branches of the afferent branchial artery which pass outward along the inner margins of the gill filaments. Teasing the demibranchs apart will also expose the cartilaginous **gill rays** which extend laterad from the arch to support the gill filaments. At the inner or pharyngeal end of each demibranch, see in section the smaller **efferent collector arteries** which carry blood away from the gill. These vessels receive branches which arise along the outer margins of the gill filaments. Between the afferent and efferent branchial arteries are the gill capillaries where the blood exchanges gases with the respiratory medium.

Mesad of the transected gill arch, the **adductor muscle** is seen cut in cross section. The somewhat discontinuous sheet of muscle between the two demibranchs is called the **interbranchial muscle**, and the continuation of this into the flap portion of the gill septum which overlaps the next gill slit is the **constrictor muscle**.

Expose the roof and floor of the pharynx as follows: Make incisions from each angle of the mouth to the pectoral girdle passing through the middle of all the gill slits. Turn the ventral wall of the pharynx caudad. On the left side, remove the lining of the roof of the pharynx and the underlying connective tissue to expose the visceral arches.

Locate the cut **mandibular arch**, **hyoid arch** and **gill arches**. Which divisions of these arches are cut by the section? Which divisions of the **gill arches** lie in the roof of the pharynx? What forms the tongue-like elevation in the anterior portion of the floor of the mouth? This structure is the **primary tongue** which is characteristic of aquatic vertebrates.

By probing, determine the relations of the spiracles. These represent a pair of gill slits which have lost their gill bearing function. How have they been modified? A few slight ridges may be present in the spiracular canal. These represent the vestigial gill. Are they present in your specimen? The spiracles are inhalant pores for the respiratory current.

The minute structure of the gill has already been studied. Now from the above dissection determine the following: the number of demibranchs, the number of holobranchs and the visceral arches which bear demibranchs. Are all the gill chambers lined with gill tissue on both anterior and posterior sides?

Plate 38. Figure 56. Diagram of a Section Passing Parallel to the Gill Filaments through a Gill of the Shark.

Label completely.

Plate 39. Figure 57. Diagram of a Frontal Section through the Roof of the Mouth and Pharynx of the Shark Showing the Skeletal Parts Exposed on the Left Side.

Label completely and color visible skeletal parts light blue. Number the visceral arches.

The Organs of the Abdominal Cavity. *Open the abdominal cavity by cutting through the ventral body wall along the mid-ventral line. Terminate this incision caudally at the pelvic girdle and anteriorly about one and one-half inches caudad of the shoulder girdle. Cut laterally on each side from each end of the longitudinal cut and turn back the flaps of the body wall thus formed.*

This exposes the **body cavity** lined with a smooth membrane, the **peritoneum**. Identify the abdominal organs, being careful not to injure the supporting membranes. These suspend the viscera from the body wall as well as attach the visceral organs together.

Locate the alimentary canal and follow it forward as far as possible. The extreme anterior portion is the **esophagus**, the

beginning of which can be seen from the dissection made on the pharynx.

The **stomach** continues caudad from the esophagus. The boundary between esophagus and stomach cannot be determined externally. Later, the alimentary tract will be opened, at which time this boundary may be determined accurately. The stomach is a hook-shaped organ, bending forward upon itself at its caudal extent. That portion of the stomach which extends cephalad is called the **pyloric region** and that between the bend and the esophagus, the **cardiac region**.

At the end of the pyloric division, at the point where the alimentary canal again extends caudad, there is a marked constriction called the **pylorus**. This is the sphincter which regulates the passage of food from the stomach to the **duodenum**, the most cephalic division of the small intestine.

The duodenum enlarges almost immediately into the next division of the small intestine, the **ileum** or **valvular intestine**. Note that its walls are thin and that they are marked by a series of rings. These rings indicate the internal attachment of the **spiral valve** to be studied in detail later.

Caudad of the valvular intestine, the intestine narrows into the **colon**. The **rectal gland** is a cylindrical body attached by a short duct to the dorsal side of the colon. This duct marks the caudal extent of the colon and the anterior limit of the **rectum**. The rectum is very short and slender, opening almost at once into the **cloaca**. This is a somewhat expanded chamber into which the urinogenital system as well as the alimentary canal empty their products. The relation of the cloaca will be taken up in more detail during the dissection of the urinogenital system.

Immediately posterior to the bend of the stomach is a triangular, reddish-brown structure, the **spleen**. Note its position a trifle to the left of the stomach.

The **liver** is the largest gland of the body and is attached to the **transverse septum** at the anterior end of the body cavity. It is divided into three lobes, two large lateral and a smaller middle lobe. The latter bears the **gall bladder** which serves as a receptacle for the bile, a secretion of the liver. Locate the **bile duct** or **ductus choledochus** by means of which the secretions from the liver reach the intestine. This extends from the middle lobe of the liver to the dorsal wall of the spiral valve. Use extreme care not to destroy its supporting membranes.

The **pancreas** is an irregular-shaped organ. One part of it is visible very closely applied to the ventral wall of the duodenum. This portion is connected dorsally by a very narrow isthmus with a large limb of the gland that extends cephalad along the cardiac stomach. Determine the shape and relations of the pancreas but, in doing so, do not injure its supporting membranes.

In the extreme anterior end of the body cavity, attached to the dorsal body wall and the transverse septum, locate the **gonads**. If your specimen is a female, locate the **oviducts**, one on either side of the mid-dorsal line and extending from the anterior end of the body to the cloaca.

The **kidneys** are the elongate, dark bodies which may be seen one on either side of the mid-dorsal line. These do not protrude far into the abdominal cavity, so are retroperitoneal in position.

The Supporting Membranes. In the vertebrate embryo, the coelom separates the lateral mesoderm into two layers; an outer one nearest the ectoderm called the **somatic mesoderm**, and an inner layer next to the entoderm called the **splanchnic mesoderm**. In the adult animal, the somatic layer forms the **parietal peritoneum** which lines the body cavity, and the splanchnic layer forms the **visceral peritoneum** which surrounds the abdominal organs. The double folds of the splanchnic mesoderm above and below the alimentary tract form the **mesenteries**. These appear as reflections of the peritoneum of the body wall across to the abdominal organs.

Certain of the abdominal organs, such as the liver and pancreas, develop as evaginations from the alimentary tract. When these evaginate, regardless of how far they may be carried away from their point of origin, the fundamental relations between visceral peritoneum and alimentary tract remain unaltered. The visceral peritoneum covers the newly formed organs in the same way that it covered the alimentary tract from which they were developed. Reflections of the visceral peritoneum between organs are called **omenta** (singular, omentum). Omenta, then, extend between parts of the viscera, while mesenteries extend between the body wall and the abdominal organs.

These relationships may be better understood after a study and comparison of *A* and *B* in Fig. 4. A study of these diagrams will reveal that the abdominal organs by strict definition are not in the coelom or body cavity but are separated from it by the visceral peritoneum.

The **dorsal mesentery** extends from the mid-dorsal line to the digestive tract. Note that it is not complete along the entire extent of the alimentary canal. That portion of the dorsal mesentery which supports the stomach is the **mesogaster**. It is attached to the stomach, spleen, duodenum and pancreas. The membrane which connects the spleen with the stomach is the **gastrosplenic omentum**. The liver is connected to the loop of the stomach by the **gastrohepatic omentum**. This is joined near

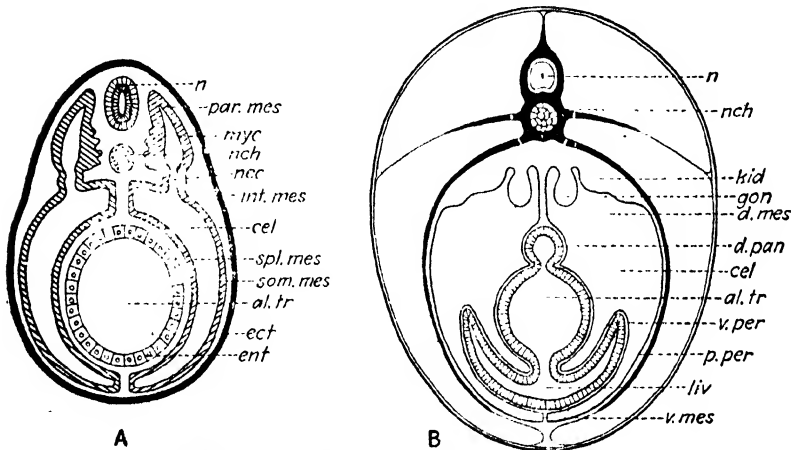


FIG. 4.—Cross-sectional diagrams to illustrate the formation of the peritoneum from the somatic and splanchnic layers of the lateral mesoderm and to illustrate the relations of the peritoneum to the abdominal organs. A. Early stage. B. Later stage.

al. tr., alimentary tract; *cel.*, coelom; *d. mes.*, dorsal mesentery; *d. pan.*, dorsal pancreas; *ect.*, ectoderm; *ent.*, entoderm; *gon.*, gonad; *int. mes.*, intermediate mesoderm; *kid.*, kidney; *liv.*, liver; *myc.*, myocoel; *n.*, neural tube; *nch.*, notochord; *nec.*, nephrocoel; *par. mes.*, paraxial mesoderm; *p. per.*, parietal peritoneum; *som. mes.*, somatic mesoderm; *spl. mes.*, splanchnic mesoderm; *v. mes.*, ventral mesentery; *v. per.*, visceral peritoneum.

the stomach by the **hepatoduodenal omentum**. This omentum also unites with the mesogaster. The bile duct extends along the edge of the gastrohepatic and hepatoduodenal omenta.

Determine the relations of the pancreas to the dorsal mesentery and to the connecting omenta.

That portion of the dorsal mesentery supporting the valvular intestine is the **mesentery proper**. At the anterior end, the mesentery proper fuses with the mesogaster. Determine the relations there. Supporting the rectum and rectal gland is the **mesorectum**.

At the anterior end of the liver find the **mesohepar** mesentery. This is a remnant of the ventral mesentery. If your specimen is a female, be particularly careful not to destroy this mesentery. The opening of the oviducts, to be studied later, is supported by this membrane.

In the anterior end of the body cavity, the gonads are connected with the dorsal body wall by mesenteries. Those supporting the ovaries of the female are called the **mesovaria** (singular, mesovarium). The testes of the male are supported by **mesorchia** (singular, mesorchium). In the female shark, the oviducts are supported and suspended from the body wall by the **mesotubaria** (singular, mesotubarium).

Plate 40. Figure 58. Diagram of a Cross Section of the Body of the Shark Passing through the Caudal Limit of the Esophagus and Showing the Relations of the Peritoneum to the Coelom and Viscera.

Plate 41. Figure 59. Diagram of a Cross Section of the Body of the Shark Passing through the Caudal End of the Cardiac Stomach and Showing the Relations of the Peritoneum to the Coelom and Viscera.

In the plates provided, only the organs which are cut by the respective sections are shown in the diagrams. With red ink or a finely pointed red crayon, draw in the peritoneum to show its actual relations. Label completely.

The Major Digestive Glands. Review the parts of the liver and the relation of the gall bladder to the liver. Again locate the bile duct on the edge of the gastrohepatic omentum.

Carefully remove the visceral peritoneum from around the bile duct and from the dorsal surface of the middle lobe of the liver. The liver tissue is very soft and in the following dissection may be scratched away with the scalpel. Dissect away the liver tissue from around the anterior end of the gall bladder. To do this, first expose the bile duct and follow it forward to the point where it leaves the gall bladder.

This will also expose the **hepatic ducts** which carry the bile from the liver. Notice that these enter the bile duct rather than the gall^o bladder. That part of the bile duct between the point of entrance of the hepatic ducts and the gall bladder is called the **cystic duct**. Carefully work out these relations. Do not confuse

the blood vessels, which are numerous in this region, with the hepatic ducts.

Follow the bile duct caudad to the intestine. After reaching the intestine, it passes caudad between the peritoneum and the muscular wall of the spiral valve. Trace it back and locate the point where it enters the intestine. Its point of entry is on the dorsal side, a short distance anterior to the first fold of the spiral valve.

Review the shape of the pancreas and locate the **pancreatic duct**. *To do this, slowly scrape away the tissue of that part of the pancreas which is closely applied to the ventral side of the duodenum and spiral valve.* The duct leaves the pancreas from the caudal margin of this part and passes beneath the peritoneum. By careful observation, the part of the duct which runs in the wall of the intestine usually may be seen from the surface. If possible, locate this portion of the duct before trying to expose the duct in the gland. This dissection is oftentimes difficult and must be executed with caution.

The Development of the Liver and Pancreas. To appreciate the definitive relationships of the liver and pancreas in vertebrates, a knowledge of their development is necessary.

In all vertebrates, the liver develops as a ventral diverticulum of the archenteron. It grows forward from its point of origin and branches again and again, the ultimate branches forming the glandular part of the organ. As the liver grows, it is soon limited anteriorly by the large blood vessels forming the sinus venosus, so that subsequent growth is in the opposite direction. As the diverticulum grows out from the intestine, it carries the peritoneum before it so that it is covered by visceral peritoneum. The distal end of the diverticulum forms the gall bladder, and the proximal end, the common bile duct. The primary branches of the diverticulum proximad of the gall bladder form the hepatic ducts.

The pancreas develops from diverticula from the intestine near the level of the liver diverticulum. There are usually three of these, one dorsal and two ventral; but in the shark, only the dorsal is present. This fact explains the relationship of the ducts in the shark, in which the bile duct enters about at the same level but on the opposite side of the intestine from the pancreatic duct. The

point of entrance of the ducts into the intestine marks that point on the intestine from which the glands developed.

During development, that portion of the intestine into which the bile and pancreatic ducts empty rotates about 180 degrees so that the pancreatic duct is ventral to the bile duct. It should be borne in mind, however, that this position is secondary and that fundamental relationships remain unaltered.

The Lining of the Alimentary Canal. *With a ventral longitudinal incision, open the alimentary canal from the point of entrance into the abdominal cavity to the pylorus.*

Note the differences in the lining of this part of the alimentary canal. The esophagus possesses projections or **papillae**, while the lining of the stomach is thrown up into folds called **rugae**. Unlike the papillae these are not permanent structures but disappear when the stomach is distended with food.

The muscular and connective-tissue coats of the alimentary canal are very elastic, but the epithelial lining of the canal is not. The rugae make possible significant enlargements in the diameter of the stomach without impairing the lining. Compare the stomach of an animal killed while the stomach was distended with food with one in which the stomach was empty. *

Continue the cut described above through the pylorus. Compare the thickness of the wall here with that in other parts of the canal. This is the sphincter which regulates the passage of food from the stomach into the intestine.

Remove the spiral valve from the body of the shark. Make two longitudinal incisions about one-fourth of an inch apart through the wall and remove this strip by carefully cutting it away from the edges of the spiral folds. Wash out the contents of the valve. With a pair of curved forceps, carefully thread a string around several folds of the spiral valve.

What would be the course of food in passing through this portion of the alimentary tract? Of what functional significance is this structure?

Plate 42. Figure 60. Diagram of the Ventral Aspect of the Viscera of the Shark Showing the Liver and the Pancreas and the Relation of the Ducts to Their Respective Organs and to the Intestine.

On the diagram provided, draw in the ducts of the pancreas and liver to show actual relations. Label completely.

THE URINOGENITAL SYSTEM OF THE SHARK

The same specimen used for the study of the digestive system may be used for this study. The spiral valve has already been removed. Now remove the remainder of the alimentary tract. In cutting through the anterior end of the stomach, be careful not to injure the gonads which are attached to the transverse septum and dorsal body wall in this region. If your specimen is a female, remove only the lateral lobes of the liver, cutting through them at about the level where they separate from the middle lobe. After the dissection of the urinogenital system has been made on your own specimen, from some other member of the class, borrow and study a specimen of the other sex. Each student will be held responsible for a knowledge of the structure of both sexes in the three forms studied.

With a blunt probe locate the **abdominal pores**. These are a pair of openings between the extreme posterior end of the body cavity and the cloaca. They open along the lateral margins of the cloaca.

From the lateral incision that was made anterior to the pelvic girdle, make a cut passing above the pelvic fin back to the abdominal pore on the left side.

The Urinogenital System of the Female.

The Genital Organs. The **ovaries** are soft, paired, oval bodies lying in the anterior end of the body cavity, dorsal and lateral to the stomach. Each ovary, as already noted, is suspended in the body cavity by a fold of the peritoneum, the **mesovarium**. If the specimen is an adult, different sized ova may be seen in the ovary.

The **oviducts** are a pair of tubes lying in the dorsal side of the body cavity and extending from the cloaca to the extreme anterior end of the body cavity. Here they pass around the liver to the ventral side of the animal. The oviduct of one side then meets its fellow from the opposite side and they have a common opening into the coelom, the **ostium tubae abdominale**. This is a large funnel shaped opening directed backward and lies in the mesohepar or suspensory ligament.

Trace one of the oviducts backward from the ostium. Notice in the region just dorsal to the ovary an enlargement of the oviduct, the **shell gland**. The shell gland is not well developed in immature animals, and at all times is more or less rudimentary in the species of shark being studied. It is best developed in those species of sharks which lay their eggs. In these forms, a horny protective coat is molded around the egg by the shell gland.

The posterior portion of the oviduct is very much enlarged to form the so-called **uterus**. Oftentimes in the laboratory specimens, this uterine portion of the oviduct contains developing young. *If your specimen is a gravid female, open the oviduct and remove the young.* Note the folds on the inner side of the uterus. These come into close contact with the embryo and make possible exchanges of materials between the embryo and the maternal tissue.

At this time, review the relations of the mesotubaria to the oviducts and to the body wall.

The **cloaca** is the common chamber into which the ducts of the urinary, genital and digestive systems open. The cloaca opens to the exterior by way of the **vent**.

At this point, make a mid-ventral incision through the pelvic girdle to the cloaca and carefully remove the left pelvic fin. This will expose the left side of the cloaca. Probe and determine the relations of the oviducts to the alimentary canal. Note the ridges which tend to make separate the portion into which the alimentary tract opens.

Projecting into the cloaca is the **urinary papilla**. Its relations will be studied later with the urinary organs.

From the above description, what must be the course of the reproductive cells in reaching the exterior? Where, owing to the presence of the shell gland, must fertilization of the ova occur? Fertilization is internal. In this connection, recall the claspers of the male which were studied earlier with the skeletal system.

The **Urinary Organs**. The **kidneys** or **Wolffian bodies** are of the mesonephric type. These will be seen extending for nearly the whole length of the body cavity on each side of the mid-dorsal line. Only the posterior portion of the mesonephros is functional, and this is much enlarged. Notice that the kidneys are extra-ceolomic or retroperitoneal.

The duct of the mesonephros or **Wolffian duct** is a slender tube which may be seen extending along the medial margin of the

caudal part of the mesonephros, about on a line with the attachment of the mesotubarium. Cephalad, it leaves the medial margin of the kidney and will be seen on its ventral surface. Trace the Wolffian duct caudad and see that a short distance cephalad of the caudal end of the mesonephros it leaves the kidney and extends downward into the mesentery which supports the extreme caudal end of the oviduct. Here the Wolffian duct enlarges to form a **urinary sinus**, the floor of which is in direct contact with the dorsal wall of the oviduct.

Carefully open the lateral wall of the sinus and locate the aperture of the Wolffian duct into it. Note also the opening of the urinary sinus of the opposite side. Insert a blunt probe or bristle into the tip of the urinary papilla and probe forward into the urinary sinus which has already been opened.

The kidney is made up of a mass of coiled mesonephric tubules which in the posterior region are concerned with the elimination of nitrogenous waste. The mesonephric tubules enter into collecting tubules, and these in turn enter into the Wolffian duct, the efferent duct of the kidney. Anteriorly, the collecting tubules enter directly into the Wolffian duct, but in the posterior third of the kidney, before entering the Wolffian duct, they turn caudad and fuse with each other to form an **accessory duct**, sometimes called a ureter. This structure, however, is not homologous with the ureter of amniotes. The accessory duct runs parallel with, and dorsad to, the Wolffian duct. It enters directly into the urinary sinus, or into the Wolffian duct just before the latter enters the urinary sinus. This variation is of no significance since the urinary sinus is nothing more than an enlarged portion of the Wolffian duct.

If possible, locate and dissect out the accessory duct. Because of its small size, its dissection is rather difficult in the female.

Plate 43. Figure 61. Diagram of the Ventral Aspect of the Urinogenital System of the Female Shark.

Label completely.

The Urinogenital System of the Male.

In the female, owing to the presence of the special ducts for conveying and harboring the ova, the urinary and genital systems are structurally separate except in the cloaca, which cavity is

utilized by both systems. Such is not the case in the male where the genital system utilizes parts of the urinary system so that the two must be considered together.

Locate the **testes** in the anterior end of the body cavity. Each testis is suspended from the dorsal body wall by its fold of the peritoneum, the **mesorchium**.

Locate the **mesonephros** and compare it in extent and shape with that of the female. The **Wolffian duct** can be seen on the ventral surface of the kidney. If your specimen is a mature individual, at the anterior end of the kidney the duct is small and greatly coiled. It becomes straight and enlarged in diameter toward its caudal end. For the reason given below, in the male, this duct is called the **ductus deferens**. In the immature male, the duct is not coiled and very closely resembles that of the female.

Traversing the anterior part of the mesorchium, the **vasa efferentia** (singular, vas efferens), which convey the spermatozoa away from the testis, can be seen. These are small fine tubules which are sometimes hard to see in preserved material. They can be seen best by holding up the mesorchium and looking through it toward the light. In the shark being studied, four vasa efferentia are present extending between testis and kidney. It may be possible to distinguish four others which begin at the kidney but end in the mesorchium without reaching the testis. The vasa efferentia enter the substance of the anterior portion of the mesonephros and here unite with mesonephric tubules. Thus a direct communication is established between testis and Wolffian duct.

Because of this connection, the Wolffian duct in the male is utilized by both the urinary and genital systems, but not simultaneously. The anterior end of the mesonephros, which in the immature shark is excretory in function, changes its function in the adult. Certain of the parts which are characteristic of a functional mesonephric renal tubule are lost in the adult. Those parts which remain secrete a viscous whitish substance which acts as a seminal fluid. This part of the kidney in the adult, then, is genital in function, and the Wolffian duct conveys only the spermatozoa plus the seminal fluid. For this reason it is called the ductus deferens.

In the adult male, the posterior part of the mesonephros is active in the elimination of nitrogenous waste. The mesonephric

tubules in this region, rather than entering the ductus deferens directly, unite to form an **accessory duct** as in the female. This duct lies immediately dorsad of the ductus deferens and, in some cases, may be readily exposed by dissecting free and lifting up the latter. Locate and identify it in your specimen, if possible.

Follow the ductus deferens caudad and notice that some distance anterior to the cloaca it enlarges to form the **seminal vesicle**. *Make a longitudinal incision through the wall of one seminal vesicle.* Notice the transverse semipartitions which give the wall a corrugated appearance. Between these folds, numerous spermatozoa are retained during the breeding season. The seminal vesicles of the two sides meet and expand posteriorly to form the **urinogenital sinus**.

This region may be exposed by removing the left pelvic fin and cloacal wall. Do not remove the fin on the right side.

Notice the **urinogenital papilla** projecting into the cloaca. Probe the opening of the papilla. It leads into the urinogenital sinus. *With the probe still in the papilla, use the scalpel or scissors to open the sinus on the left side.* Locate the opening of the accessory duct into the sinus. It opens through the dorsal wall just caudad of the opening of the ductus deferens.

Leading off from the anterior end of the urinogenital sinus ventrad of the sperm ducts, locate the **sperm sacs**. These are short, blind evaginations which appear to be a part of the urinogenital sinus, but in reality they correspond to the caudal end of the oviduct of the female. Other parts of the oviducts in the male have disappeared.

Examine the edge of the ventral body wall where it was cut by the transverse incision passing just anterior to the pelvic girdle. Locate the siphon sacs which are cut transversely by this section. These are a pair of large sacs lying just under the skin ventral to the base of the pelvic fin. Explore the sac that remains on the right side with a blunt probe. Notice that it opens posteriorly into the base of the clasper groove. These sacs are provided with glands the secretion of which fills the sac. The walls of the sac are muscular, and its function appears to be to force the spermatozoa along through the clasper groove during copulation.

From the claspers, the spermatozoa pass into and along the course of the oviducts. The eggs are probably fertilized in the anterior ends of the oviducts, cephalad of the shell gland.

Plate 44. Figure 62. Diagram of the Urinogenital System of the Male Shark Showing the Urinogenital Sinus Opened on One Side.

Label completely.

The Development of the Kidney Systems of Vertebrates. A knowledge of the development of the kidney systems of vertebrates is necessary to understand completely and to appreciate their definitive relationships; also to understand how two systems, so different in function as the urinary and genital systems, come to be structurally related. For this purpose the following brief account is given.

Three kidneys make their appearance in vertebrates, **pronephros**, **mesonephros** and **metanephros**. These three kidneys appear successively in the order named in phylogeny, in ontogeny and in their relative positions in the body.

The following table summarizes their occurrence in vertebrates.

Pronephros	Mesonephros	Metanephros
Functional in embryos of all anamniotes	Permanent in anamniotes (except in a few which retain the pronephros)	Permanent in amniotes
Permanent in some cyclostomes and teleosts		
Transitory in embryos of amniotes	Transitory in amniotes	

All three types of kidneys develop from the same region of the mesoderm, the mesomere or intermediate mesoderm. This occurs after the epimere or paraxial mesoderm has broken away from the intermediate mesoderm. In the anterior part of the embryo, the intermediate mesoderm, like the paraxial mesoderm, is divided into a series of segments, called **nephrotomes**. In the posterior region, the nephrotomes are not distinct and the intermediate mesoderm here forms an unsegmented, solid mass of kidney-forming or nephrogenous tissue.

The pronephros or head kidney appears first in development and is the most anterior in the body. The number of nephrotomes involved varies in the several classes of vertebrates from one in some teleosts to twelve in some of the Apoda. From the somatic wall of each pronephric nephrotome, there grows

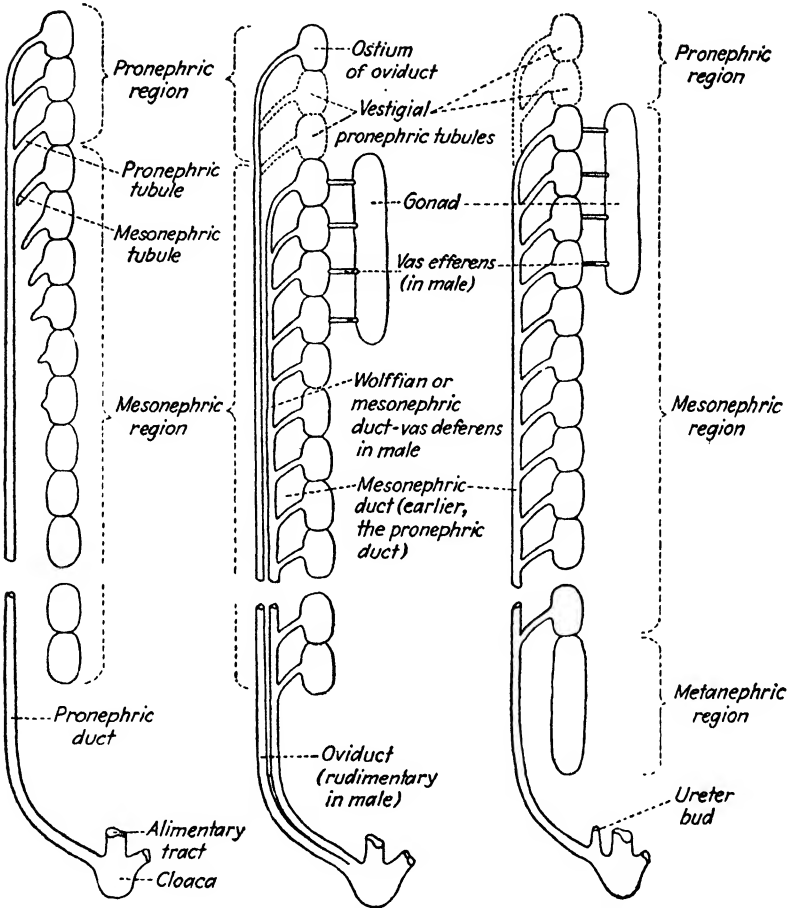


FIG. 5.

FIG. 6.

FIG. 7.

FIG. 5.—Schema showing the relations of the kidney systems of anamniotes (embryonic stage). The pronephric tubules have united laterally to form the pronephric duct. The mesonephric tubules are forming but have not yet tapped the pronephric duct.

FIG. 6.—Schema showing the relations of the kidney systems and the genital systems of anamniotes after the pronephric duct has split to form the oviduct and the Wolffian duct. The schema presents both male and female relationships. In the adult one of these becomes dominant while the other remains rudimentary or disappears.

FIG. 7.—Schema to show the relations of the metanephros of amniotes to the pro- and mesonephric systems (embryonic stage). The pronephric duct, utilized by the mesonephros, does not split to form the oviduct, but forms the vas deferens of the adult male. The oviduct is not shown in the schema since in amniotes, it is a peritoneal structure unlike that of anamniotes. The ureter bud, indicated as arising from the Wolffian duct, grows forward into the metanephric region.

laterally toward the ectoderm a hollow tube or a solid cord of cells

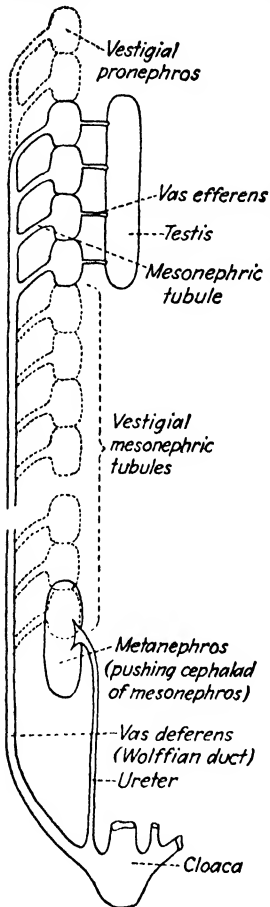


FIG. 8.—Schema to show the relations of the kidney systems of amniotes (later stage). The metanephros is the functional kidney of the adult. The pro- and mesonephric systems disappear, except those parts of the mesonephric system which are utilized by the genital system of the male. Changes occurring in the cloacal region are not indicated in the schema.

which later acquires a lumen. In either case, these form the **pronephric tubules**. Each tubule communicates with the coelom by its original opening between the cavities of the lateral and intermediate mesoderm. This opening is called the **nephrostome**. The distal ends of the pronephric tubules continue to grow laterally until just beneath the ectoderm they bend caudad, the anterior tubules fusing with those behind. From this fusion, a longitudinal duct, the **pronephric duct**, is formed which, independent of subsequent tubule formation in the mesonephric region behind, grows caudad just beneath the ectoderm to the posterior end of the body cavity where it fuses with the alimentary tract. An opening breaks through placing the coelom in communication with the outside world by way of the pronephric duct and cloaca.

In the pronephric kidney, the **glomerulus**, the vascular component of the kidney system, projects into the coelom mesad of the nephrostome so that materials filtered from the blood are thrown into the coelom and are later taken up through the nephrostome and passed to the exterior by the pronephric tubule and pronephric duct.

The mesonephros, also called the **Wolffian body**, is the second kidney system to form. It arises after the pronephros, and its duct has developed by the formation of a series of **mesonephric tubules** which grow laterally from the nephrotomes lying caudad of those involved in the formation of the pronephros. These tubules grow out in a cephalo-caudal sequence and tap the

already formed pronephric duct. After this connection is established, the pronephric duct becomes known as the **mesonephric duct**.

The glomerulus, in the mesonephric kidney, instead of being formed to extrude into the coelom, develops at a higher level and thus pushes into the splanchnic wall of the nephrotome. Thus materials filtered from the blood are thrown directly into the lumen of the mesonephric tubule. This eliminates the coelom from the course followed, consequently the nephrostomes in the mesonephric kidney usually seal off so that the coelom is not connected with the exterior by way of the mesonephric tubules. The wall of the nephrotome immediately surrounding the glomerulus is called **Bowman's capsule**. Together, the **glomerulus** and Bowman's capsule form a **Malpighian body** or **renal corpuscle**.

Although the metanephric type of kidney is not encountered in laboratory study until the cat is taken up, it is described here in anticipation of its study later.

The metanephros develops caudad of the mesonephros but by a method which differs from that employed by the first two kidney systems. From the dorsal side of the posterior end of the Wolffian duct near where it enters the cloaca, a bud grows forward forming a tube, the **ureter**, which parallels the Wolffian duct and pushes forward into the unsegmented nephrogenous tissue caudad of the mesonephros. In this process, the nephrogenous tissue is pushed forward and dorsad of the caudad end of the mesonephros with the result that, in the adult, the kidney lies some distance anterior to the caudal limit of the body cavity. Within the nephrogenous tissue, the ureter divides successively to form the collecting tubules of the adult kidney. These open into an expanded portion of the ureter, the **pelvis**. That part of the kidney tubule distad of the collecting tubule is formed from the nephrogenous tissue independently of the ureter component, however, it secondarily acquires an opening into the collecting tubule. Nephrostomes are never formed in the metanephric kidney.

Both ovaries and testes form as a pair of longitudinal thickenings of the peritoneum called **genital ridges**. These lie one on either side of the dorsal mesentery and between it and the Wolffian body.

In the study made upon the urinogenital system of the shark, it was noted that, in the female, a separate duct was present to serve the ovary. In the male, one duct served both the mesonephros and the testis.

In the shark, when the mesonephros develops, the pronephric duct splits longitudinally. This split begins at the anterior end of the mesonephros and continues caudad to the cloaca so that two ducts are formed. The mesal duct, connected with the tubules of the mesonephros, forms the Wolffian duct; the lateral duct, connected anterior to the mesonephros with the pronephric tubules, forms the **Müllerian duct** which is the oviduct of the adult. The ostium of the oviduct is a derivative of the nephrostomes of the pronephros. The split in the pronephric duct occurs in both male and female sharks, but in the male, the ovi-

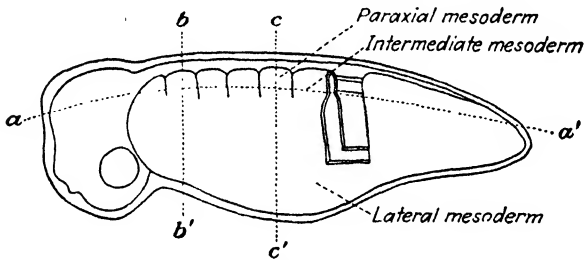


FIG. 9.—Lateral aspect diagram of a vertebrate embryo with *a-a'* indicating the plane of section for Figs. 5 to 8, *b-b'* for Fig. 10 and *c-c'* for Fig. 11.

ducts, since they do not function, remain rudimentary and form only the sperm sacs of the adult.

In the amphibia and amniotes to be studied later, the formation of the oviduct is unlike that in the shark. In amphibia, the nephrostomes form the ostia of the oviducts, and the pronephric tubules may form the beginning of the oviducts, but the remainder of each arises by the formation of a longitudinal groove in the peritoneum which parallels the Wolffian duct to its point of entrance into the cloaca. Later this becomes rolled into a tube and connects with the anterior pronephric component to form the oviduct of the adult. The pronephric duct does not split longitudinally but transversely, the anterior part fusing with the posterior peritoneal derivative as described.

In amniotes, the anterior end of the peritoneal groove does not join with the pronephric component but remains open to form the ostium of the oviduct. Thus in amniotes, the oviducts are

derived entirely from the peritoneum, and the pronephros plays no part in their formation.

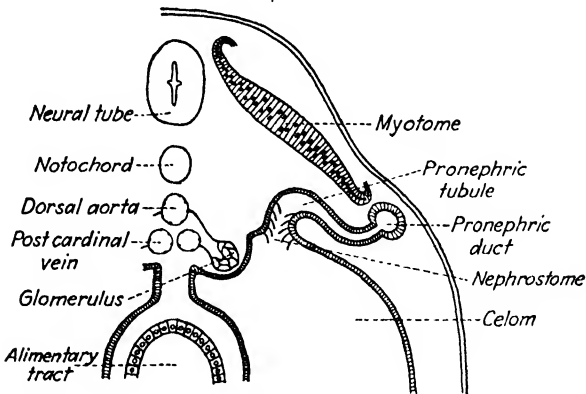


FIG. 10.—Cross-sectional diagram through the pronephric region to show the relation of the glomerulus to the coelom, to the pronephric tubule and to the pronephric duct.

The ovary, in the shark and in the forms to be studied later, has no direct connection with the oviduct. The ova must pass into the coelom before entering the oviduct.

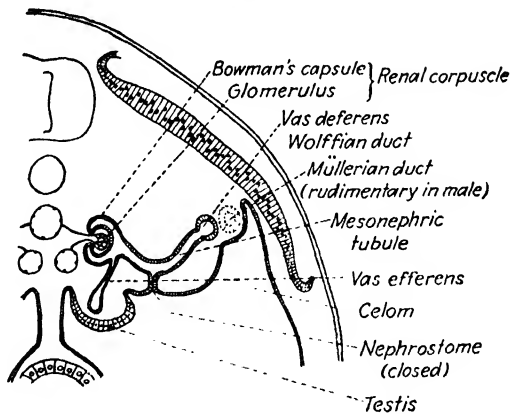


FIG. 11.—Cross-sectional diagram through the mesonephric region to show the relation of the glomerulus to the mesonephric tubule and to show the relation of the mesonephric tubule of the testis.

In male elasmobranchs, amphibia and amniotes, the Wolffian duct, in addition to serving the mesonephros, also serves to carry the sperm away from the testis.

While the seminiferous tubules are developing in the testis, cords of cells, called medullary cords, grow across from the walls of the Bowman capsules of the anterior mesonephric tubules and unite with the tubules in the testis. These acquire a lumen and form the vasa efferentia which place the testis in communication with the Wolffian duct by way of the mesonephric tubules. In this way the Wolffian duct forms the vas deferens for the testis. Owing also to this direct connection, the spermatozoa, unlike the ova, are not thrown free into the coelum but are retained within tubular walls to their point of exit from the body.

A study of the accompanying series of diagrams will aid in visualizing the processes described beginning on page 131.

THE DIGESTIVE AND RESPIRATORY SYSTEMS OF NECTURUS

Study the following external features on the specimen supplied for this work. Note the number and relative sizes of the external gills. What are the structural adaptations present here for increasing the area of the respiratory epithelium? Does the method used in *Necturus* differ from that in the shark? Ventrad of the proximal ends of the gills are the **visceral clefts**. How many are there? Locate the **external nares**.

The Mouth Cavity and Pharynx. *Expose the floor and roof of the mouth cavity and pharynx as follows. With the scissors or scalpel, separate the upper from the lower jaw at their point of articulation by cutting through the angle of the mouth on each side. Extend each of these cuts caudo-dorsad above the gills and lay back the floor of the mouth.*

In the roof of the mouth, note the teeth arranged in three patches on each side. Recall that these are borne by the pre-maxillary, vomer and palatopterygoid bones. Just laterad of the caudal teeth borne by the vomer bones, locate the **internal nares**. Enlarge one of these openings anteriorly and notice that it leads into the **nasal capsule** into which the external naris also opens.

In the floor of the mouth, note the short tongue. Is the tongue of *Necturus* markedly different from that of the shark? Locate the visceral clefts or gill slits in this aspect. Between what skeletal parts, do they lie? Are any traces of internal gills present? On the margins of the gill slits, notice the small blunt projections. To what in the shark are they comparable? On

the median line, at about the level of the caudal end of the gill slits is a narrow slit, the **glottis**. This is the opening into the lungs to be studied later. The glottis marks the caudal extent of the pharynx.

The Organs of the Abdominal Cavity. *Open the abdominal cavity by a longitudinal incision a little to the left of the mid-ventral line, taking care not to injure the underlying organs. This cut should extend from the base of the arm to the base of the leg. Make lateral cuts on the left side so that the body wall may be folded back.* Examine the thin membrane, the **mesohepar**, extending between the ventral body wall and the liver. How far in each direction does it extend?

To expose the viscera more completely, make similar lateral cuts on the right side, cut through the mesohepar, and fold back the body wall from each side.

In the following study of the viscera, be careful not to destroy the supporting membranes. After the organs have been identified, make a study of these membranes similar to that made in the shark. Be able to describe and name the mesenteries and omenta of *Necturus*. The fundamental relationships are the same as in the shark.

The dark-colored **liver** is nearly median in position. Is it divided into lobes as in the shark? On the right side and dorsal surface of the liver locate the **gall bladder**.

To the left of the liver, locate the **stomach** which is limited posteriorly by a constriction, the **pylorus**. Notice that the stomach is merely an enlarged straight portion of the alimentary tract. In respect to shape, the stomach of *Necturus* is more primitive than that of the shark. The elongate, dark-colored organ on the left side of the stomach is the **spleen**.

On either side of the liver in the dorsal part of the coelom are the elongate **lungs**. Which of the two is the longer? Slit open one of these and notice that the organ is saclike with smooth walls. The anterior relations of the lungs will be studied later.

Follow the **intestine** from the pylorus back to the **cloaca**. Feces tend to accumulate in the region just anterior to the cloaca so that it may appear enlarged, but when the tract is entirely empty, there is no sudden or gradual enlargement. The colon has not differentiated in *Necturus* as in the higher **amphibia**.

The **pancreas** is the irregular-shaped organ near the pyloric end of the intestine. The **bile** and **pancreatic ducts** are short and quite small in *Necturus*. They need not be dissected.

Complete the study of the mesenteries and omenta at this point.

By careful dissection, remove the liver from its attachment to the transverse septum. In doing so, take care not to injure the lungs. Just caudad of the transverse septum, locate the point where the lungs of the two sides pass ventrad of the esophagus and unite to form a short, broad **trachea**. Insert a blunt probe into the glottis and notice where it appears on the ventral side.

Necturus is one of the perennibranchiate amphibia, that is, the gills are functional throughout life. This animal never leaves the water as do most amphibia. Because the gills are retained as the major respiratory organs, the lungs are very simple in structure and are not important in respiration.

*Important! No drawings will be required on the digestive and respiratory systems of *Necturus*, but each student will be held for an oral demonstration or written quiz.*

THE URINOGENITAL SYSTEM OF NECTURUS

The same specimen used for the study of the digestive and respiratory systems may be used for the following study. Remove the alimentary canal by carefully cutting through the dorsal mesentery, through the esophagus and through the intestine about one inch anterior to the vent.

The Urinogenital System of the Female.

The Genital Organs. The **ovaries** are elongate, paired, saclike organs extending across a considerable distance in the posterior part of the roof of the body cavity. Each ovary is attached to the dorsal body wall by the **mesovarium**. Notice in the ovary the different-sized ova, the size depending upon the season of the year and the age of the individual.

Dorsal to the ovaries are the much coiled **oviducts** or **Müllerian ducts**. These ducts are less coiled in immature individuals. Trace one of these forward and find its opening into the body cavity, the **ostium tubae**. How far cephalad is this opening? What is its shape and which way does it project? What must

the course of the ova be in reaching the oviduct? Now trace the oviduct caudad to the **cloaca**. *To do this it will be necessary to cut through the pelvis and open up one side of the cloaca. Important! While doing this, care must be taken not to injure the urinary bladder, described later, which projects out from the ventral wall of the cloaca.* Notice that the two oviducts open into the cloaca by a pair of **genital papillae**. These are quite evident.

The **Urinary Organs**. The **mesonephros** or **Wolffian body** is the same type of kidney as was found in the shark. The mesonephroi extend along the dorsal body wall, one on each side of the mid-dorsal line. They are club-shaped structures. As in the shark only the enlarged posterior portion is functional as an organ of excretion. Notice that, unlike the shark, the kidney in *Necturus* is not retroperitoneal.

The **Wolffian duct** is plainly visible running along the lateral margin of the kidney. Notice a large number of small **collecting tubules** passing from the kidney into the Wolffian duct. Trace the latter back to its place of entrance into the cloaca. Near the posterior end of the kidney, the Wolffian duct inclines toward the mid-line and runs diagonally across the ventral surface of the kidney to open on the dorsal wall of the cloaca. What is the relation of its opening to that of the oviduct?

Notice the thin-walled evagination off the ventral wall of the cloaca, called the **urinary bladder**. What is its relation to the openings of the Wolffian ducts? How must it function? Note that the bladder is attached to the body wall along the mid-ventral line by a fold of the peritoneum.

Plate 45. Figure 63. Diagram of the Ventral Aspect of the Urinogenital System of the Female *Necturus*.

Label completely.

The Urinogenital System of the Male.

The Genital Organs. The **testes** are two elongate bodies lying in the posterior part of the roof of the body cavity. Each is suspended by a fold of the peritoneum, the **mesorchium**. Find the **vasa efferentia** extending from a testis across the mesorchium into the substance of the anterior part of the kidney. Here they unite with mesonephric tubules which in turn convey the spermatozoa into the **Wolffian duct**. The latter, then, as in the shark,

is the efferent duct of the testis and is called the **vas** or **ductus deferens**.

Trace the *vas deferens* in both directions. It extends as far forward as the anterior end of the kidney. Note that anteriorly, it is very much coiled, enlarged in diameter and heavily pigmented; posteriorly, it is smaller in diameter, has less pigmentation and is less coiled. The degree of convolution and the state of distension vary greatly according to the season, being greatest during the period of male sexual activity. Notice that the diameter of the *vas deferens* is largest anterior to the *vasa efferentia*. The anterior end of the kidney is not functional as an excretory organ and is called the **genital kidney**. The enlarged Wolffian duct in this region serves as a **seminal vesicle**.

Note that the pigmentation of the Wolffian duct is most dense in the region of the genital kidney, and especially so along the lateral edge where a broad, black, longitudinal stripe marks the course of the **rudimentary oviduct**. Posteriorly, starting at the point where the kidney begins to enlarge, the pigmentation becomes less dense. The line marking the course of the rudimentary oviduct persists, however, but grows progressively fainter until it disappears. Some distance anterior to the cloaca, it usually appears again on the lateral side of the *vas deferens*. Trace the stripe of pigmentation anteriorly and note that it disappears in the region in which the ostium tubae is found in the female.

At the point where the kidney begins to enlarge, the *ductus deferens* decreases in diameter, and the convolutions become considerably less prominent and less frequent. As it runs caudad, it becomes nearly a straight tube lying two to four millimeters from the lateral edge of the kidney and receives the **collecting tubules** of the functional kidney. How many of the collecting tubules can you find? After receiving the collecting tubules, the duct bends slightly mesad and runs obliquely across the ventral surface of the kidney. It opens into the cloaca on its dorso-lateral wall, just caudad of a transverse fold which separates the intestine from the cloaca, and opposite the urinary bladder. There is no urinogenital papilla.

The Urinary Organs. See the description given above for the female.

The above study has shown that specialized copulatory organs are lacking. Nevertheless, fertilization is internal.

Two types of glands are present in the cloaca of the male; **pelvic glands** in the roof of the cloaca, and **cloacal glands** distributed along the walls of the cloaca. The function of the cloacal glands is the secretion of a small globule of gelatinous material which is attached to some object in the water. To the top of this globule, a mass of spermatozoa is attached by the secretion of the pelvic glands. The structure thus formed is called a **spermatophore**.

Later the spermatophore is taken up into the cloaca by the female. In the female the tubules of the pelvic glands are modified to form a **spermatheca** which harbors the spermatozoa. The remainder of the spermatophore disintegrates. It is thought that in most cases the ova are fertilized as they pass from the oviducts into the cloaca. There is evidence, however, that in some salamanders the spermatozoa pass up the oviducts, so that fertilization occurs anterior to the cloaca.

The interrelationship of the urinary and genital systems should be understood. Note that this is not the same in the two sexes. Be able to trace the course of the sex cells to the point of fertilization and to the exterior.

Plate 46. Figure 64. Diagram of the Ventral Aspect of the Urinogenital System of the Male Necturus.

Label completely.

THE DIGESTIVE AND RESPIRATORY SYSTEMS OF THE CAT

The study of those parts of the digestive and respiratory systems which lie within the thorax will be postponed until the blood system is dissected, at which time the organs of the thorax will be exposed. The anterior end of the digestive and respiratory tracts may be studied from demonstration specimens supplied for the purpose.

The Mouth Cavity and Pharynx. In the cat, the primitive mouth cavity and the anterior end of the pharynx are divided horizontally by the **palate**, not present in the forms previously studied, into an upper respiratory passage and a lower food tract. Two regions are recognized in the palate; the **hard palate** being that part formed by the premaxillary, maxillary and palatine bones, the **soft palate** being the membranous portion caudad of

the hard palate. *Locate these and the following structures in a cat's head which has been sectioned through the meson and, also, in the dried skull.*

The **nasal cavities** lie above the hard palate in the anterior part of the skull. They are almost entirely filled by the ethmoid and vomer bones. The roof is formed by the nasal bones and the anterior portion of the frontals; their sides are formed by the frontals, lacrymals, maxillaries, premaxillaries and palatines; their floor is formed by the palatines, maxillaries and premaxillaries. The two nasal cavities are entirely separated by the mesethmoid which is continued forward into the cartilaginous nasal septum. The external opening of the nasal cavity is the **external naris**. Posteriorly, the nasal cavity opens into the nasal pharynx by the **internal naris**. The nasal cavity is entirely lined with mucous membrane, but only part of this membrane functions in the reception of olfactory stimuli.

The **nasal pharynx** is directly caudad of the nasal cavity and is that cavity which is enclosed when the soft palate is pushed dorsad against the dorsal wall of the pharynx at the time of swallowing.

Below the palate, the mouth cavity is continuous caudally with the **oral pharynx**. Within this combined cavity, notice the teeth which have already been studied in connection with the skeletal system, and the tongue. Notice that the mammalian tongue is a protrusible, muscular organ and recall that it is formed from the secondary tongue of amphibia plus additions from the first and third visceral arches of the pharynx. What is its relation to the body of the hyoid apparatus?

The nasal and oral divisions of the pharynx are continuous caudad of the soft palate with the **laryngeal pharynx**. This is the location of the **pharyngeal chiasma**, or that point where the dorsal respiratory passage crosses the food tract to the ventral position that it occupies back of this point. In other words, the laryngeal pharynx is that part of the pharynx common to both respiratory and food tracts. The laryngeal pharynx leads posteriorly into the esophagus above and into the trachea through the glottis below.

The **larynx** is the enlarged upper end of the air passage which leads from the pharynx to the lungs. It consists of several cartilages which were described under the skeletal system. Over the

opening into the larynx, the **glottis**, is the triangular cartilage, the **epiglottis**, which closes the glottis when food is passed from the oral pharynx into the esophagus. Determine how this works. Refer to the drawing of the larynx, Plate 11, Fig. 14, and with this aid locate the laryngeal cartilages.

The **trachea** is that portion of the air passage which extends from the larynx to the bronchi. The wall of the trachea is supported by **tracheal cartilages**. Do these completely encircle the trachea?

Note! The remainder of the respiratory system will be studied later, but it is described at this time for future reference.

Within the thorax at about the level of the sixth rib, the trachea divides into two main **bronchi**. Are these supported by cartilages as was the trachea?

The bronchi pass immediately into the **lungs** which, in life, almost completely fill the thoracic cavity. In an embalmed specimen, the lungs collapse and shrink away from the walls of the thorax.

The lungs are separate from each other except at the radix where they are united by the bronchi. They lie one on each side of the thorax with the **mediastinal septum** between them. The right lung is slightly larger than the left. It divides into three small proximal lobes and a larger distal lobe. The left lung is divided into three main lobes of which the anterior two are partly united at the base. Each bronchus divides into as many main branches as there are lobes in the lung on its side.

The peritoneum lining the thorax is called the **parietal pleura**, and that covering the lungs, the pulmonary or **visceral pleura**. Each lung is suspended from the dorsal side and from the diaphragm by a fold of the pleura called the **pulmonary ligament**.

The Organs of the Abdominal Cavity. *To expose the viscera, make a longitudinal incision through the transverse muscle on the left side where the abdominal muscles were dissected. This cut should be to one side of the mid-ventral line and extend from the edge of the ribs back to the pubis. From the anterior end of this incision, make two lateral cuts through the body wall. The lateral cuts should follow the margin of the ribs.*

Before reflecting the flaps of the body wall thus formed, carefully lift the ventral body wall and notice, on the mid-line just anterior to the pubis, a thin mesentery, the **suspensory ligament**

of the bladder. Study its relations now since it may be injured in the subsequent study.

In the anterior end of the body cavity is the **liver**. Caudad of the liver the visceral organs are covered by an extensive fold of the peritoneum called the **great omentum**. Without tearing, carefully free this omentum from the folds of the intestine. This omentum represents the mesogaster of lower forms, which, in the cat, instead of passing directly to the stomach, passes from its median dorsal attachment between the kidneys and the diaphragm, ventrad of the intestine as far caudad as the pelvis, at which point it turns and passes cranial to reach the caudal margin of the stomach. These folds thus form the **omental sac**, the cavity of which is the **lesser peritoneal cavity**. Each wall of the sac is double like a mesentery, so that the great omentum consists of four sheets of peritoneum.

The lesser peritoneal cavity within the omental sac communicates with the peritoneal cavity proper through the **foramen of Winslow** which is located dorsad of the duodenum toward the medial side of the right lobe of the liver.

The lesser peritoneal cavity is closed anteriorly by the **lesser omentum**. This is a double sheet of peritoneum which stretches horizontally from the liver to the duodenum and the anterior margin of the stomach.

The **esophagus** is a straight tube which extends from the pharynx to the stomach. It lies dorsad of the trachea until it reaches the region near the middle of the trachea, then it passes to the left and lies dorso-laterad of the trachea. It pierces the diaphragm and immediately enters the stomach. That part of the esophagus anterior to the diaphragm should be studied later when the thorax is opened.

Compare the **stomach** of the cat, in respect to shape and position in the body, with that of the shark and *Necturus*. That portion of the stomach which communicates with the esophagus is known as the **cardiac region** and that communicating with the intestine, as the **pyloric region**. Owing to the curvature of the stomach, a concave and a convex side may be distinguished. The caudal convex margin of the stomach is called the **greater curvature**; the cephalic concave margin, the **lesser curvature**. The greater curvature extends to the left into a prominent convexity called the **fundus** of the stomach. Each of the three

regions, cardiac, pyloric and fundus, is characterized by a special type of glandular epithelium.

The constriction at the pyloric end of the stomach is the **pylorus**.

The **small intestine** is divided into three regions, the **duodenum**, **jejunum** and **ileum**. These regions are recognized because of the character of their epithelial lining; externally, the limits between the regions cannot be determined. The duodenum is that division of the small intestine which continues caudad from the pylorus. It takes a U-shaped turn and passes into the jejunum without definite limits which may be determined externally. The ducts of the pancreas and liver open into the duodenum.

The caudal end of the ileum passes into the **large intestine**. At the junction of the small and large intestine, is an outpocketing, the **caecum**. It is at this point that the **vermiform appendix** is located in man. The large intestine is divided into **colon** and **rectum**. The rectum is the caudal portion. There is no marked division between these two regions of the large intestine.

Examine the mesentery supporting the intestine and notice that it is continuous. However, each different region is specifically named according to the part of the intestine which it supports. Locate the **mesorectum** and **mesocolon**. Anteriorly, the mesocolon passes into the **mesentery proper** which is broad and very much folded to follow the loops of the intestine. At the caudal end of the duodenum, the mesentery is drawn out into a fold, the **duodenorenal ligament**, which attaches the duodenum to the right kidney.

The **liver** occupies the cranial part of the abdominal cavity and is closely applied to the **diaphragm**. It is divided into main **right** and **left lobes**, each of which is further divided. The left is divided into an **anterior left median** and a **posterior left lateral** lobe. The right is divided into **right median** or **cystic**, **right lateral** and **caudate** lobes. The right lateral lobe is further partially divided into an anterior and posterior portion. In position the cystic lobe is anterior, the right lateral is posterior and the caudate lobe is attached to the mesal side of the posterior portion of the right lateral lobe. The caudate lobe projects into the lesser peritoneal cavity of the omental sac. Determine its relations by probing through the foramen of Winslow with the little finger.

The liver is divided into its main lobes by the **suspensory ligament** which is a portion of the primitive ventral mesentery. Notice that the free caudal margin of this ligament is thickened. This is called the **ligamentum teres** and represents the remains of the foetal umbilical vein. The liver is attached to the diaphragm by the **coronary ligament**. The coronary ligament is broad where it passes from the left lateral lobe to the diaphragm and this portion of it is called the **triangular ligament**. Is a right triangular ligament present in your specimen? The caudal division of the right lateral lobe of the liver is attached to the kidney of that side by the **hepatorenal ligament**. This is continuous with the duodenorenal ligament.

Find the **gall bladder**. On which lobe of the liver is it located? The gall bladder opens into the **cystic duct**. At its distal end, the cystic duct is joined by several **hepatic ducts** bringing bile from the liver. The duct formed by the union of the cystic and hepatic ducts is called the **common bile duct** or the **ductus choledochus**. This runs along the ventral margin of the foramen of Winslow and opens through the **ampulla of Vater** together with the pancreatic duct, described below, into the dorsal side of the duodenum about three centimeters caudad of the pylorus.

Dissect the bile duct and determine its relations. In doing so be careful not to injure the pancreatic duct. Open the duodenum and locate the ampulla of Vater.

The **pancreas** is a flattened gland of irregular and more or less indefinite outline. It consists of two arms which are at right angles to each other. One arm extends along the greater curvature of the stomach, supported in the descending limb of the great omentum; the other extends caudad along the duodenum, supported in the duodenal mesentery. A branch of the **pancreatic** or **Wirsung's duct** extends into each arm of the pancreas, the two uniting just before entering the duodenum.

By carefully scraping away the tissue of the pancreas, find and expose the pancreatic duct. Begin this dissection near where the duct enters the intestine and work distally from that point.

As explained on page 124, the anlage of the pancreas may be from both dorsal and ventral diverticula of the intestine. In the cat both are present, but the dorsal diverticulum forms the larger part of the gland. Notice that the arm of the pancreas lying along the greater curvature of the stomach is the larger of the two.

The ventral diverticulum forms the smaller duodenal arm of the pancreas. The definitive duct of the pancreas is that of the ventral diverticulum, the one belonging to the dorsal pancreas being lost. This is the developmental explanation of the definitive relationships of the bile and pancreatic ducts. Occasionally, the dorsal duct persists also and is called the **accessory pancreatic duct** or **duct of Santorini**.

The **spleen** is a lymphatic organ and has no function in connection with digestion. It is a long, flattened organ lying on the left side of the stomach supported in the descending limb of the great omentum.

THE URINOGENITAL SYSTEM OF THE CAT

The Urinogenital System of the Female.

The Urinary Organs. The cat possesses the metanephric type of kidney. As explained on page 134, it is derived from the intermediate mesoderm of the extreme caudal end of the body cavity.

The **kidneys** of the cat are compact bean-shaped organs lying on either side of the mid-line against the dorsal body wall. The right kidney is located slightly more cephalad than the left. Each is covered with peritoneum on its ventral side only, so the kidneys are retroperitoneal in position.

Cut through the peritoneum to expose the kidney on one side of the body.

About in the middle of the median border of the kidney, there is an indentation called the **hilus** of the kidney. It is at the hilus that the renal artery enters and the renal vein and **ureter** leave the kidney. *Carefully remove the fat from around these vessels to expose them completely. With a sharp knife or razor blade, slice away the ventral surface of the kidney for some distance.* Notice that within the kidney the ureter expands in diameter. This expansion is the **pelvis** of the ureter. Careful examination will disclose a narrow space surrounding the pelvis of the ureter and separating it from the kidney tissue. This space, called the **sinus** of the kidney, opens to the exterior of the kidney at the hilus. The blood vessels of the kidney enter and leave through this sinus.

At this time recall that, during development, the ureter bud, given off from the Wolffian duct, pushes forward into the nephrog-

enous tissue of the metanephric region and expands to form the pelvis of the ureter in the definitive kidney. The space between these two parts of distinct embryonic origin is never entirely obliterated, but persists to form the sinus of the adult kidney.

Carefully dissect the pelvis of the ureter. It will be seen that laterally the substance of the kidney projects inward and almost fills the pelvis of the ureter. This cone-shaped projection is called the **papilla**. It is through the apex of the papilla that the numerous collecting tubules, too small to be seen with the unaided eye, open into the pelvis of the ureter. Over the surface of the papilla, the wall of the pelvis is closely applied to the kidney tissue so that in this region the sinus is obliterated.

Examine the sectioned kidney tissue. It shows two regions, an outer, darker, granular zone called the cortex and an inner striated, lighter zone, the medulla.

Trace the ureter caudad, freeing it of surrounding fat, but being careful not to injure the blood vessels near it. Locate the points at which the ureters of the two sides open into the **urinary bladder**. The bladder is a pear-shaped organ which lies in the abdominal cavity anterior to the pubis between the ventral body wall and the rectum. Caudad, it is continued into a narrow **neck** which passes dorsad of the pubic symphysis.

Carefully separate the two halves of the innominate bone by cutting through the symphysis. Trace the continuation of the neck of the bladder, which is the **urethra**, to the exterior.

The **suspensory ligament** of the bladder has already been noted. Two other ligaments pass, one from each side of the bladder, to the dorsal body wall at the sides of the rectum. These are the **lateral ligaments** of the bladder.

Lying cranio-mediad of the kidneys, locate the two **suprarenal glands**. They are usually embedded in more or less fat. These are ductless glands of internal secretion and are not a part of the urinary system.

The Genital Organs. The genital organs of the female consist of the ovaries which harbor the ova, and the Fallopian tubes which received the ova from the ovaries, the uterus in which the young develop and the vagina which leads from the uterus to the exterior by way of the urinogenital sinus.

Locate the **uterus** which lies immediately dorsad of the bladder. It consists of a **body** and two **horns** or **cornua** which project

cephalo-laterad and are continuous with the Fallopian tubes. Folds of the peritoneum, the **broad ligaments**, extend from the dorsal body wall along each uterine cornu and along the sides of the uterus.

The **Fallopian tubes** are narrow, sinuous tubes, each of which expands, at the anterior end, into a funnel-shaped opening, the **ostium tubae abdominale**. The walls of the ostium are thin and are thrown up into folds.

Caudo-mesad of the ostium is the small ovoid **ovary**. The ovary is held in position by the broad ligament of the uterus. The ovary is further held in position by the **ligamentum ovarii**, a short thick cord which extends from its caudo-ventral margin to the ventral surface of the uterine cornu.

Posteriorly, the uterus is continuous with the **vagina**. The inner wall of the uterus projects for a short distance into the vagina as the **cervix**. *Slit open the wall of the vagina and locate this structure.* It will be found at about the level of the anterior margin of the pubis.

The vagina extends from the uterus dorsad of the pelvic symphysis to a point a short distance cephalad of the caudal border of the ischiatic symphysis. At this point it is joined by the urethra to form the **urinogenital sinus**. The external opening of the latter is the **vulva**.

In the mammalian embryo, as in the shark and Necturus, two oviducts are present; but during development, the two fuse at their posterior ends to form the single, median vagina and the body of the uterus. The uterine cornua and the Fallopian tubes represent the anterior, unfused parts of the oviducts.

Plate 47. Figure 65. Drawing of the Ventral Aspect of the Urinogenital System of the Female Cat.

Label completely.

The Urinogenital System of the Male.

The Urinary Organs. *For the study of the kidney, use the description and directions given under the female urinary organs. Dissect the ureters and trace them into the urinary bladder. Caution! Be very careful not to cut the ducts of the testes at the point where they loop around the ureters. Read the text below for a complete description of these ducts. In the male, do not separate*

the two halves of the innominate bone to follow the urethra until after the vas deferens has been dissected as instructed below.

The Genital Organs. Locate the ureter again and follow it caudad toward the bladder. Notice that near its entrance into the bladder, it is looped by a slender tube, the **vas deferens**. Follow the ventral limb of the loop of the vas deferens caudad and see that it passes through a funnel-shaped opening into the **inguinal canal**, which leads through the body wall.

Next locate the **scrotum**. This is a pouch of the integument which lies ventrad of the anus on the median line against the ischiatic symphysis. It is marked by a median groove which indicates the position of an internal septum dividing its cavity into lateral halves. The **testes** lie in the scrotum, one in each compartment.

Carefully remove the skin from the ventral side of the pelvic girdle back as far as the scrotum.

The vas deferens, the blood vessels supplying the testis and the associated sheath of these structures, extending between the inguinal canal and the scrotum, constitute the **spermatic cord**. *Carefully dissect the cord free. With a longitudinal incision, carefully slit open the sheath of the spermatic cord near the middle of its length and locate the vas deferens inside of it. It is important to note that the cavity within the spermatic cord is continuous with the coelom. Probe through the spermatic cord toward the coelom.*

Like the definitive position of the testes of the two animals previously studied, the embryonic position of the testes of the cat is in the body cavity proper. During development, however, they push caudad from the coelom to lie, in the adult, in the scrotum. Fundamental relations, nevertheless, remain unchanged. The cavity surrounding the testis in the scrotum is continuous with the coelom by means of the lumen within the sheath of the spermatic cord. Actually, then, the inner layer of the sheath of the spermatic cord is peritoneum.

Follow the vas deferens caudad into the scrotum by cutting open the spermatic cord. Notice that it runs along the medial side of the testis and in this region is very much coiled. At the caudal end of the testis the vas deferens is continuous with the **epididymis** which makes an acute cephalic bend to lie on the medial side of the testis dorsad of the vas deferens. About three-fourths of the way forward, the epididymis turns laterad across

the dorsal surface of the testis, runs around the lateral margin, and appears on the ventral surface at the extreme anterior end of the testis. This enlarged cranial end of the epididymis is called the **caput epididymis**, and it is here that the **vasa efferentia** connect the epididymis with the tubules of the testis. The portion of the duct distad of the caput is called the **cauda epididymis**. The whole epididymis, being encased in a tough fibrous sheath, appears straplike. Its coiled nature is not apparent externally.

Again locate the vasa deferentia where, shortly after entering the body cavity, they loop over the ureter and pass caudad together along the dorsal wall of the neck of the bladder as far as the cranial border of the pubis.

Separate the two halves of the innominate bone, and dissect away the fat from around the neck of the bladder and the vasa deferentia.

Locate the point where the latter enter the **prostate gland** which appears as a marked swelling at the beginning of the urethra. The **urethra** is the common urinogenital duct formed after the vasa deferentia enter the neck of the bladder. Open the urethra in the region of the prostate gland and locate the openings of the vasa deferentia, close together on the dorsal side.

The urethra extends from the openings of the vasa deferentia to the end of the **penis**. The penis is a cylindrical organ directed backward, and lies immediately ventrad of the scrotum. It is covered by the integument which projects over the end as the **prepuce**. *Cut through the prepuce and expose the penis.*

The penis is formed by three bodies of vascular, erectile tissue, two **corpora cavernosa penis** and the **corpus cavernosum urethrae**. Each corpus cavernosum penis is attached to the caudal border of the ischium near the symphysis. From this attachment, the two corpora approach one another to form the **crura**, then become closely united and pass along the ventral surface to the free end of the penis. The corpus cavernosum urethrae is dorsal and surrounds the portion of the urethra which extends through the penis. All three bodies unite at the free end of the penis to form a small **glans**. Only the proximal ends of the corpora cavernosa penis, where they attach to the pelvic girdle, can be seen by gross dissection; elsewhere they are internal.

At the root of the penis, one on each side of the urethra, locate the two **bulbourethral** or **Cowper's glands**.

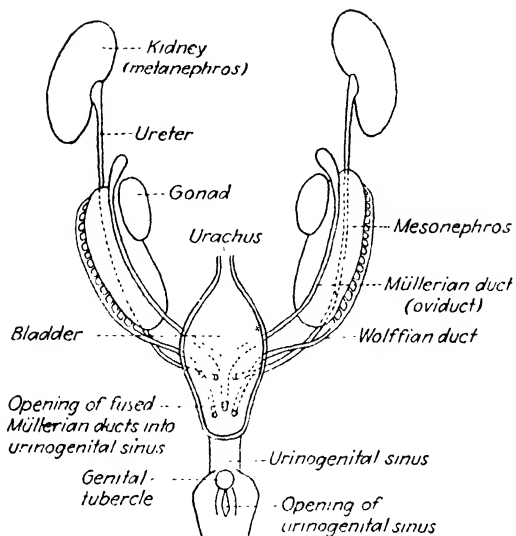


FIG. 12.—Schema presenting the indifferent stage in the urinogenital system of mammals. (Modified from Corning.)

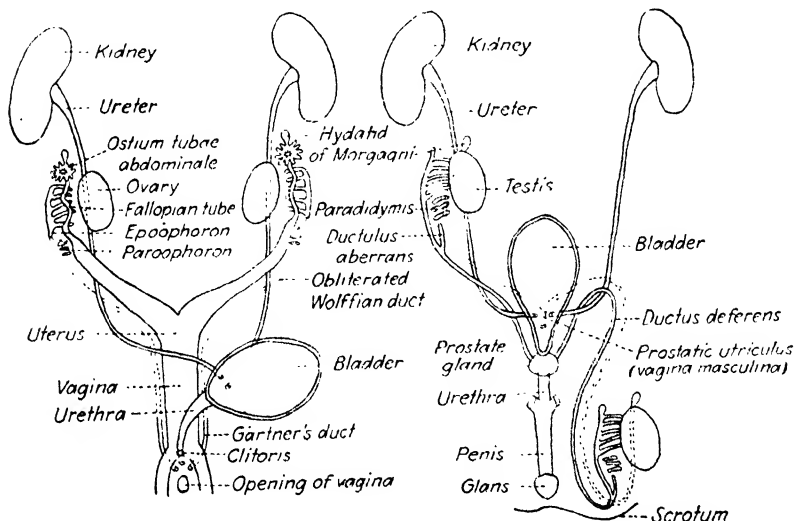


FIG. 13.

FIG. 14.

FIG. 13.—Schema of the female urinogenital system of mammals indicating the vestigial remains of the mesonephric system. (Modified from Corning.)

FIG. 14.—Schema of the male urinogenital system of mammals indicating the vestigial and rudimentary remains of the mesonephric system and the female genital organs. On one side of the diagram, the testis is shown in its embryonic position; on the other, in its position after its descent into the scrotum. (Modified from Corning.)

Vestigial and Rudimentary Structures in the Urinogenital System of Mammals. It has been noted above that the functional kidney of the cat is the metanephros. The mesonephros, nevertheless, is present and functional during development. In the male sex of the shark and *Necturus*, it has been seen that the Wolffian duct of the mesonephros becomes the efferent duct of the testis owing to the connection established by the vasa efferentia. This duct, then, is urinary and genital in function, unless as in the shark, accessory ducts develop to carry away the urinary products of the mesonephros.

This same connection between testis and Wolffian duct is established in the cat; thus when the metanephros becomes the functional excretory organ in the adult, the Wolffian duct is retained and is functional as the efferent duct of the testis, the vas deferens. Other parts of the mesonephric system are also retained as vestigial structures.

The history of the kidney system is the same in the female as in the male cat, but because special genital ducts develop and function in the female, the entire mesonephric system becomes vestigial in the adult. These special genital ducts develop in both sexes, but in the male, except for a few rudiments, they disappear.

The diagrams on page 153 give a graphic summary of the ontogeny of the urinogenital system of the mammal, showing the parts retained as functional, vestigial and rudimentary structures.

Plate 48. Figure 66. Drawing of the Ventral Aspect of the Urinogenital System of the Male Cat.

Label completely.

CHAPTER V

THE CIRCULATORY SYSTEM

The circulatory system of vertebrates comprises a circulating fluid vehicle, the **blood** and **lymph**, and the **vascular system**, the system of vessels which contain the fluid vehicle as it circulates through the body. The vascular system may be considered as composed of two parts; the **blood vascular system** which includes that part of the system carrying the blood, and the **lymphatic vascular system**, that part carrying the lymph back into the main blood stream.

The blood vascular system is made up of the following parts: a pumping organ, the **heart**; vessels carrying blood away from the heart, the **arteries**; vessels bringing blood to the heart, the **veins**; and a network of microscopic tubes interposed between the arteries and veins, the **capillaries**. In a few places in the body, notably in the liver, networks are present in which the diameter of the tubes is larger than that of the capillaries. These are called **sinusoids** to distinguish them from the capillaries.

The lymphatic vascular system consists of a number of **lymph spaces** or sinuses which occur beneath the skin, between muscles, in the mesenteries and in numerous other places in the body. These spaces drain into more or less definite **lymph vessels** which lead into **lymphatic trunks**. These in turn open into the veins. In the course of many of the lymph vessels will be found aggregations of lymphatic tissue, the **lymph nodes**. These nodes are the production centers for certain types of blood cells and also serve as a seat of destruction of foreign particles which may get in the lymph stream.

The conspicuous function of the circulatory system is that of carrying food and oxygen to, and waste away from, the tissues. This exchange of materials between the blood and the tissues takes place only in the capillaries. The function of the larger vessels, therefore, is only that of carrying the blood to or away from the capillaries.

In this course the study of the circulatory system is limited to a consideration of the blood vascular system. Special methods of technic are necessary to demonstrate the lymphatics.

THE BLOOD VASCULAR SYSTEM OF THE SHARK

The elasmobranchs possess the **single** type of circulation. In this type of circulation, impure blood enters the heart and is pumped to the gills where it transfers its gaseous waste into the water around the gills and receives from it a fresh supply of oxygen. The vessels receiving the oxygenated blood from the gill capillaries unite above the gills to form the dorsal aorta which sends off branches to all parts of the body. In the tissues the blood loses its oxygen and food, takes up waste and returns to the heart.

Thus all blood is oxygenated each time that it is pumped through the heart. This complete single circulation is the simplest and most efficient to be found in vertebrates.

Insert a short pencil or similarly shaped piece of wood about four inches back into the mouth of the shark provided for the study of the vascular system. This will elevate the floor of the mouth toward the dissector so that the following dissection may be made more conveniently.

Remove the skin of the ventral side of the animal from the lower jaw caudad to the posterior limit of the pectoral girdle. This will expose a more or less continuous thin sheet of muscle in which the fibers run mainly in a transverse direction. These are the ventral constrictor muscles of the visceral arches. Remove this sheet of muscle and expose the ventral longitudinal or hypobranchial muscles. In removing this sheet of muscle and the muscles described below, it will be necessary to cut through a number of small injected arteries. The origin of these arteries will be described later.

Just anterior to, and originating from, the coracoid portion of the pectoral girdle, are the paired coracoarcuales muscles. These insert on the heavy connective tissue which forms the floor of the pericardial cavity. On the mid-line anterior to the coracoarcuales muscles, locate the median coracomandibularis muscle extending cephalad to insert at the symphysis of the lower jaw. Remove this muscle and expose the paired coracohyoideus muscles. Carefully cut through these muscles as closely as possible to their insertion on the hyoid arch, reflect them caudad and cut them loose from their origin. In

cutting through the insertion end of these muscles, be careful not to injure the ventral aorta, a large blood vessel described below, which at this point lies just dorsad of the coracohyoideus muscles. The origins of the coracohyoideus muscles are more or less continuous with the insertions of the coracoarcales muscles which should also be removed now.

The rather intricate directions given above for exposing the heart and ventral aorta have been outlined with a purpose other than that of merely exposing these parts, which could have been done more readily. It should be understood by the student, that the blood vessels have very definite relations to the surrounding structures just as muscles have definite relations to bones, nerves to muscles, mesenteries to viscera, etc. Subsequently, in following the blood vessels, little account will be taken of these relationships, the objective being that of exposing the vessels and determining their distribution. The presence of these relationships and their exactness should be appreciated, however. It would be the ideal method to study the blood vessels in relation to all other structures along their course, but time will not permit of such a detailed study.

The Heart.

Removing the muscles described above will expose the **pericardium** of the heart on the mid-line just anterior to the pectoral girdle. *Expose the heart by cutting through the pericardium. To expose the heart completely, it will be necessary to transect and remove the middle portion of the pectoral girdle also.*

Locate the thick-walled, muscular **ventricle** with the tubelike **conus arteriosus** extending cephalad and apparently piercing the anterior wall of the pericardial cavity. On either side of the ventricle will be seen a part of the thin-walled **auricle** or **atrium**. Lift up the caudal end of the ventricle and note, beneath it, the thin-walled, triangular **sinus venosus** extending caudally to the posterior wall of the pericardial cavity.

The sinus venosus receives all of the venous blood from the body veins and passes it on to the auricle through a slitlike opening past the **sinuauricular valve**. From the auricle the blood passes into the ventricle past the **auriculoventricular valve**. This valve consists of two pocketlike flaps, the concavities of which are directed toward the ventricle. They permit the flow of

blood toward the ventricle, but a flow in the opposite direction is prevented by their closure. From the ventricle, the blood passes through the conus arteriosus to the ventral aorta which lies anterior to the pericardium. The conus arteriosus is provided with **semilunar valves** which prevent the back flow of the blood.

The heart will not be opened until the end of the study of the blood system. At that time the valves described above should be studied.

From the above study, it is to be seen that the heart of the shark is a four-chambered organ considering the sinus venosus and the conus arteriosus as parts of the heart. These four chambers are connected in tandem. In this respect, the heart of the shark differs from the four-chambered heart of the mammal to be studied later.

The Arteries.

The Afferent Branchial Arteries. Trace the ventral aorta forward from the cephalic end of the conus arteriosus. This vessel is usually not injected and is of about the same color as the surrounding tissue. Care must be used in exposing it.

Trace the branches of the ventral aorta, the **afferent branchial arteries**, into the gills on the right side. *To do this it will be necessary to dissect away the coracobranchiales muscles.* The afferent arteries lie dorsad of these muscles.

There are five afferent arteries on a side. Three of these are given off from the ventral aorta very close together not far cephalad of the pericardial cavity. The two afferent arteries nearest the heart leave the dorsal side of the aorta by a common trunk. This soon divides into two; the more caudal branch supplies the holobranch of the sixth visceral arch, the other supplies the holobranch of the fifth visceral arch. The afferent artery supplying the holobranch of the fourth visceral arch leaves the ventral aorta just a short distance cephalad of the common trunk of the caudal two afferent arteries. After giving off these branches, the ventral aorta runs cephalad to a point not far caudad of the basihyal cartilage where it divides into two branches, one given off to each side of the animal. Follow the branch on the right side and see that it soon divides in two. These are the remaining two of the afferent branchial arteries. The caudal one of the two supplies the holobranch of the third visceral arch; the cephalic, the demibranch of the second arch.

Note the branches given off from the afferent branchial arteries to the gill filaments. In this connection, recall the work done on the respiratory system of the shark.

Important! In working upon the vascular system of any animal it always is advisable to make free use of sketches while the dissection is in progress. These sketches may be used in building up the completed drawing after the entire system has been dissected. It often happens that vessels already dissected are destroyed while dissecting others. Hence, the necessity of keeping a record of the course of each vessel while it is being dissected.

The Efferent Branchial Arteries. *Expose the efferent branchial arteries in the following manner. If the ventral aorta is injected, ligate the conus arteriosus where it leaves the heart and again where it leaves the pericardium, and between these ligatures transect the conus. If the ventral aorta is not injected it need not be ligated. Insert one point of the scissors into the angle of the mouth on the left side and cut caudad to the last gill chamber. This cut should pass through the center of all the gill slits. Now make a transverse cut which will connect the last gill chambers of opposite sides. This cut will pass through the posterior basibranchial which forms the dorsal wall of the pericardial cavity and the heart must be reflected ventrad in making it. Turn aside the ventral wall of the pharynx and carefully remove the membrane lining the roof and right side of the pharynx. This will expose the efferent branchial arteries. Follow these back to the gills and expose the entire efferent branchial system of arteries. To do this it will be necessary to cut through and carefully remove the visceral arches.*

Note that each demibranch is drained by an **efferent collector** artery and that the efferent collector of the posterior demibranch of one arch joins with the efferent collector of the anterior demibranch of the succeeding arch to form an **efferent branchial** artery. The same two efferent collector arteries are connected below the gill cleft in such a way that an arterial loop is formed around the cleft. Four such loops are formed around the anterior four gill clefts and the resulting four efferent branchial arteries unite to form the dorsal aorta. A complete loop is not formed around the last gill cleft since gill filaments are lacking on the posterior wall of this chamber. Determine how blood from the last demibranch reaches the dorsal aorta. Notice that the two efferent collector arteries on a single arch are connected by a number of **cross**

trunks. How many of these are there on an arch? What are their relations to the afferent artery?

The Branches of the Efferent Collector Arteries. From the ventral angles of the arterial loops, a number of arteries are given off which supply the hypobranchial region, the pericardium and the heart. These connections may have been destroyed in dissecting out the afferent arteries, but locate them, if possible. Note especially the **coronary** arteries which carry a rich blood supply to the heart; also, the **pericardial** arteries which course down the dorsal wall of the pericardial cavity supplying the region en route.

Two cephalic branches will be found leaving the efferent collector which drains the demibranch borne by the hyoid arch. The more medial and dorsal branch of these two, the **hyoidean efferent artery**, leaves the efferent collector just before this collector is joined by the succeeding efferent collector to form the first efferent branchial artery. The more lateral and ventral branch is the **afferent pseudobranchial artery**. This leaves the efferent collector at about the middle of its course through the demibranch. Trace this artery to the spiracle where it will be seen to break up into a network of smaller vessels. This breakup is probably reminiscent of the time when the spiracle was an unmodified gill chamber and bore gill tissue.

The blood distributed to the spiracle by the afferent pseudobranchial is collected by the **efferent pseudobranchial artery**. Follow this vessel cephalad and note that just before it enters the brain case through a foramen in the orbit, it gives off the **ophthalmic** artery to the eye region. Do not follow this artery farther cephalad at this time.

Trace the hyoidean efferent artery cephalad. Find a small artery joining it on the medial side and note that this small artery leaves the medial side of the first efferent branchial artery. This is one member of the **paired aortae**. Find its mate on the other side. Just after receiving the paired aorta, the hyoidean efferent divides into two branches: one branch, the **external carotid**, bends sharply laterad and is distributed mainly to the side of the head; the other branch, the **internal carotid**, runs toward the mid-line and enters the brain case through the carotid foramen.

At this time remove the middle portion of the upper jaw and expose the ventral surface of the brain case. Cut a small opening into the

brain case just anterior to the carotid foramen and enlarge this opening until the entire brain is exposed. Do not cut any small vessels.

Locate again the internal carotid and efferent pseudobranchial arteries. Note that the internal carotid of one side meets and crosses its fellow of the opposite side and together they enter the brain case through the carotid foramen. Within the brain case the internal carotids cross to opposite sides and each meets with the efferent pseudobranchial artery of that side to form a single vessel, the **cerebral** artery. This artery runs cephalad almost as far as the optic nerve where it divides into three vessels supplying the brain and spinal cord. These are the **anterior cerebral** which runs forward between the cerebral hemispheres of the brain, the **median cerebral** which passes forward to supply the olfactory tract and bulb, and the **posterior cerebral** which bends acutely caudad. The posterior cerebral arteries of opposite sides unite at about the level of the carotid foramen to form the **spinal** artery which courses caudad and ventrad to the spinal cord.

The anterior cerebral arteries of the two sides are usually connected by a commissure. There is thus formed by the anterior and posterior cerebrals a complete arterial loop around the ventral part of the brain. This is called the **circle of Willis**. Note that, owing to this arrangement, the brain may receive its blood supply from either or both sides of the body.

The Branches of the Dorsal Aorta. Trace the efferent branchial arteries caudad and note that they unite to form the **dorsal aorta**.

The **subclavian** artery to the pectoral fin is given off from the aorta between the third and fourth efferent branchial arteries. Do not attempt to dissect it at present. It can be studied better after the large veins in that region have been dissected.

Open the abdominal cavity with a mid-ventral incision passing from a point just caudad of the pectoral girdle to the pelvic girdle.

The next artery to leave the aorta is the **coeliac axis** which supplies the reproductive organs, stomach, duodenum, spiral valve, liver and pancreas. Do not attempt to dissect out the dorsal aorta at the point where the coeliac axis is given off. The veins of this region must be studied first.

The coeliac axis enters the body cavity at the anterior end and almost immediately gives off one or several branches to the

reproductive organs. In the male these are called the **spermatic** arteries and in the female the **ovarian** arteries.

Important! In following the arteries which supply the viscera, be careful not to injure the veins to be studied later.

The coeliac axis continues caudad through the coelom on the right side of the stomach to about the level of the pylorus. Here it branches into two arteries, the **gastrohepatic** and the **anterior intestinal**. The former is very short and soon divides into the **hepatic** which parallels the bile duct and goes to the liver through the gastrohepatic omentum, and the **gastric** which supplies the stomach. Work out the distribution of the **gastric** artery.

The anterior intestinal continues across to the pylorus where it divides into three branches, the **pyloric**, the **ventral intestinal** and the **intraintestinal** arteries.

The pyloric artery is distributed to the pyloric end of the stomach. Several small pyloric arteries may be given off here rather than one common trunk.

The ventral intestinal artery courses along the dorsal side of the ventral head of the pancreas and, after giving off a **pancreatic** artery into this organ, appears on the ventral wall of the valvular intestine. Here it gives off paired branches which run along the attached edge of the spiral valve more or less completely encircling the intestine. *It will be necessary to dissect away some of the pancreas to locate the pancreatic artery.*

The intraintestinal artery gives off the **duodenal** artery supplying the duodenum, and then pierces the intestine at the beginning of the spiral valve. Trace this artery into the spiral valve and note that it follows the spiral valve caudad.

The next artery to be given off from the dorsal aorta is the **posterior intestinal** which runs across to the dorsal side of the spiral valve and supplies the posterior half of this organ.

Just caudad of the posterior intestinal, the **gastro-pancreatico-splenic** artery leaves the aorta and sends branches to the spleen, stomach and dorsal arm of the pancreas.

Occasionally the posterior intestinal and gastro-pancreatico-splenic arteries leave the aorta by a common trunk. When this occurs, the common trunk is called the **anterior mesenteric** artery.

The **posterior mesenteric** artery leaves the aorta a short distance caudad of the anterior mesenteric or gastro-pancreatico-splenic artery. It supplies the rectal gland and rectum.

Carefully cut through the peritoneum along the lateral margin of the mesonephros and reflect the kidney mesad. Note the parietal arteries given off from the dorsal aorta segmentally. Note that each parietal gives off a small ventral branch, the renal artery, which supplies the kidney. The parietal arteries are given off from the dorsal aorta along its entire length.

Cut through the pelvic girdle and locate the **iliac** arteries. Before the iliac artery runs out into the fin as the femoral artery it gives off two branches. The first is the **rectal** supplying the walls of the rectum. The other is the **posterior lateral** artery which runs forward supplying the posterior lateral body wall. Anteriorly this artery is continuous with the anterior lateral artery which is a branch of the subclavian artery.

The dorsal aorta, as the **caudal** artery, leaves the body cavity and traverses the hemal arch to the tip of the tail. As it passes along, it gives off segmental branches to the muscles of the tail.

The Veins.

The blood has been traced in its course through the arteries, from the heart by way of the gills, to all parts of the body where it performs its work of giving up food and oxygen to the tissues, and of taking up carbon dioxide and nitrogenous waste. This work is done in the capillaries. The capillaries then unite to form small veins, and these, in turn, unite into larger veins which return the blood to the heart. Some of the veins, however, break up in certain organs and collect again as veins before entering the heart. Such a breakup in the course of a vein is called a **portal system**. Two portal systems are present in vertebrates, one in the kidney called the **renal portal system**, another in the liver called the **hepatic portal system**.

The Hepatic Portal System. All the blood distributed to the viscera by the coeliac axis, posterior intestinal and gastropancreaticosplenic arteries returns to the heart by way of the liver.

The **posterior intestinal** vein receives blood from the rectum, rectal gland and posterior half of the valvular intestine. It begins in the rectal gland. *Make a transverse cut through the middle of this organ and note the vein coursing through its center.* Toward the caudal end, it leaves the rectal gland on the ventral side, bends sharply cephalad, runs along on, and receives branches

from the dorsal side of the valvular intestine. It leaves the dorsal surface of the spiral valve at about the middle and goes to the spleen where it receives the **gastro-pancreaticosplenic vein** which drains the region supplied by the artery of the same name. After receiving this vessel, it turns cephalad and runs along the dorsal surface of the dorsal arm of the pancreas from which it receives many small branches.

At the cephalic end of the pancreas, the posterior intestinal joins with the **anterior intestinal**, the **gastric** and the **duodenal** to form the **hepatic portal vein**.

Trace the anterior intestinal caudad and note that it is formed by the union of two large veins; the **ventral intestinal** from the ventral wall of the valvular intestine, and the **intraintestinal** from the spiral valve. Each of these vessels, before uniting to form the anterior intestinal, receives branches from the surrounding region. The ventral intestinal receives a branch from the ventral lobe of the pancreas and one from the spleen and stomach. The intra-intestinal, shortly after emerging from the spiral valve, receives branches from the pylorus, pyloric stomach and duodenum.

The gastric vein receives blood from the stomach. Notice that it collects blood from the region supplied by the main gastric artery.

The duodenal vein, which is not so large as the gastric or anterior intestinal vein, collects from the duodenum.

The hepatic portal vein runs through the gastrohepatic omentum, paralleling the bile duct, and enters the liver where it divides into two main branches, one to each lobe. The branches of the hepatic portal vein experience a complete breakup into sinusoids and then recollect as two large **hepatic** veins which enter the **sinus venosus**.

Locate the hepatic veins but do not attempt to follow them into the sinus venosus at this time. To locate them transect the liver about three-fourths of an inch caudad of its attachment to the transverse septum. They can be seen, cut in cross section, one on each side of the liver.

The Renal Portal System. Blood distributed to the tail is collected in the **caudal vein** which passes cephalad through the ventral division of the hemal arch. At the point where this vein enters the body cavity, it divides into two **renal portal** veins. These pass cephalad on either side of the mid-line along the

dorsal surface of the mesonephroi. Small **afferent branches** extend from these two veins into the mesonephroi where they break up into capillaries. These recollect into efferent branches which lead into the postcardinal veins.

To trace the caudal and renal portal veins, transect the tail just caudad of the cloaca. Note the two divisions of the hemal arch, the upper containing the caudal aorta, and the lower, the caudal vein.

Make successive thin sections of the tail until the point is reached where the caudal vein divides into the two renal portal veins. On one side dissect the kidney free from the dorsal body wall being careful not to injure the renal portal vein. Insert one point of the fine scissors in the vein and cut cephalad, opening the dorsal wall of the vessel. Note the small openings in the ventral wall of the vessel. These are the afferent veins to the kidney.

As stated above, the **postcardinals** are the veins which receive the blood from the kidneys and return it to the heart. The right one of these may be traced as a single vessel from the caudal end of the kidneys forward to about the level of the posterior mesenteric artery where it is joined by the left postcardinal. At this point, the right and left postcardinals are joined by several cross trunks. From this point they course forward, one on each side of the dorsal mesentery. Along their course from the posterior to the anterior end of the body cavity, they receive **segmental veins** from the body wall. Near the anterior end of the body cavity, the postcardinal veins expand into large **postcardinal sinuses**, connected with each other across the mid-line.

Open one of the postcardinal veins by slitting its ventral wall longitudinally. Continue this cut forward through the postcardinal sinus to the postero-lateral margin of the sinus venosus. Wash out the clotted blood or injection mass which may be found in the postcardinal sinus.

Notice the supporting connective-tissue strands which stretch from wall to wall in the postcardinal sinus. That part of the vessel looping the esophagus between the sinus venosus and postcardinal sinus is the **duct of Cuvier**.

The Veins of the Body Wall. The body wall is drained by the **lateral abdominal veins**. Locate these coursing up the sides of the animal just beneath the peritoneum. In the region of the cloaca, right and left lateral abdominal veins are continuous across the mid-line, and each receives a **cloacal vein** from the rectal

region and a **femoral** vein from the pelvic fin. It will not be possible to locate these in an uninjected specimen. Between the pelvic and pectoral fins, the lateral abdominal vein receives branches from the musculature of the body wall.

In the anterior end of the body cavity, the lateral abdominal vein unites with the **brachial** vein from the pectoral fin to form the **subclavian** vein which bends sharply dorsad and enters the duct of Cuvier. *Locate the brachial vein by cutting the fin off close to the body and identifying it cut in cross section. Probe this vein and determine where it joins the lateral abdominal vein.*

The Veins of the Head. Blood supplied to the head is returned to the heart by the jugular veins. In the specimen being studied, it will be possible to locate and identify these vessels near their point of entrance into the sinus venosus.

The **inferior jugular** veins may be located where they were cut in cross section in the dissection of the arteries anterior to the heart. Examine the transected dorsal wall of pericardial cavity. On the mid-line, locate the transected posterior basibranchial and, on either side of this, the cut ends of the last gill arch. In this section just ventrad to the gill arch, locate the inferior jugular vein cut in cross section. With a blunt probe or stiff bristle, probe backward and locate its opening into the sinus venosus. Probe forward and, if possible, determine the course of the vessel.

From the dorsal angle of the last gill slit, make a transverse cut toward the mid-line. This cut will open up the **superior jugular** vein which is also called the **anterior cardinal** vein. It runs just dorsal to the gills. Probe backward to locate its opening into the sinus venosus, and forward to determine the direction of its course.

The study of the subclavian artery may be completed now that the veins in this region have been dissected.

Locate the point where the subclavian leaves the dorsal aorta and note that it passes dorsad of the postcardinal sinus and out toward the pectoral region. Dissect it out and, of its several branches, identify the **brachial** artery which passes through the coracoid foramen to the pectoral fin, the **coracoid** artery to the ventral portion of the pectoral girdle, and the **anterior lateral** artery to the body wall. The anterior lateral artery is continuous posteriorly with the posterior lateral artery given off from the iliac artery.

The Internal Structure of the Heart. *Cut through the sinus venosus along its line of attachment to the posterior wall of the pericardial cavity. Open the auricle by means of a transverse incision, and the ventricle and conus arteriosus, by a mid-ventral incision. Study the internal structure of the heart described on page 157.*

The Pericardioperitoneal Canal. Connecting the peritoneal cavity and the pericardial cavity is a passage called the **pericardioperitoneal canal**. It opens into the peritoneal cavity just dorsad of the sinus venosus. Probe backward from the pericardial cavity and determine the relations of this canal.

In all vertebrates the pericardial cavity represents a special part of the coelom set aside, as it were, as a housing for the heart. During development, it is separated from the coelom proper by the formation of the transverse septum. In most vertebrates, the transverse septum is complete, and the two cavities are accordingly unconnected, but in the shark, the septum is incomplete so that the cavities remain in communication. This connection is the pericardioperitoneal canal.

Important! *The course of the blood from the heart to the gills, and from the gills to all parts of the body and back to the heart again should be visualized. In the quizzes over this part of the work, the student will be expected to be able to trace the course of the blood anywhere throughout the body.*

Plate 49. Figure 67. Diagram of the Ventral Aspect of the Arterial System of the Shark.

The diagram for the arterial system of the shark, and all the vascular diagrams which follow, are printed on two sheets. Place the two sheets together so that the two parts of the diagram match. In the diagram for the arterial system of the shark, only the body outline and more important organs are shown. Draw in all the described arteries in their proper relations.

Plate 50. Figure 68. Diagram of the Ventral Aspect of the Venous System of the Shark.

In the above diagram, in addition to the body outline and important organs, certain of the described veins usually not well injected are also shown. Draw in the remainder of the described veins in their proper relations.

THE BLOOD VASCULAR SYSTEM OF NECTURUS

For the following study upon the vascular system of Necturus, a gelatin injected specimen is used. The gelatin is quite brittle so great care must be used in dissecting in order not to destroy the vessels. By means of sketches, keep a record of the course of each vessel as it is being dissected.

Remove the skin from the ventral and dorsal surfaces of the head and body on the left side as far caudad as the anterior limb. Do not remove the skin from the external gills at this time. Lift up the coracoid portion of each half of the pectoral girdle and snip it off with the scissors. Carefully remove the segmented trunk muscles from beneath the coracoids and as far forward as the gular fold and expose the pericardium. Cut through the pericardium and expose the heart.

The Heart.

The heart will probably be filled with injection mass, so it may be somewhat greater than its natural size. Locate the **ventricle** with the **conus arteriosus** leading forward from it. Locate the **right** and **left auricles**. Lift up the auricles and locate the **sinus venosus**. Note its peculiar ring-shaped appearance.

Compare the location of the heart in Necturus with that of the shark. Recall that the dissection of the heart in the shark necessitated removing a number of the hypobranchial muscles. Notice in Necturus that the heart lies caudad of the hypobranchial region, and may be exposed by removing trunk muscles only.

The primitive and embryonic position of the heart in all vertebrates is in the hypobranchial region. In higher vertebrates, it is drawn caudad until, eventually in mammals, it lies in the thorax. In respect to position of the heart, Necturus is intermediate between the shark and the cat to be studied later.

The Arteries.

The Afferent Branchial Arteries. *Trace the afferent branchial arteries to the gills on both sides of the animal. To do this, it will be necessary to dissect away the trunk musculature between the anterior end of the conus arteriosus and the gills.*

Notice that the conus divides, sending two vessels to each side of the animal. The two vessels given off on each side run laterad

and pass dorsad of the constrictor arcuum branchiarum muscle. Beyond this muscle, the cephalic vessel runs out along the ventral margin of the epibranchial of the first gill arch and breaks up in the first gill.

Caution! In following the first afferent branchial artery, be careful not to destroy the external carotid, described below, which appears at this time to be a branch from the afferent artery to the hypobranchial muscles.

The caudal vessel from the conus arteriosus divides under the constrictor arcuum branchiarum muscle into two branches, and these run out along the epibranchials of the second and third gill arches to the last two gills. There are, therefore, three **afferent branchial** arteries in *Necturus*, one going to each of the external gills.

The Efferent Branchial Arteries. *Very carefully remove the skin from the dorsal surface of each of the external gills and notice that each is drained by an efferent branchial artery. Care must be used in locating these arteries. They lie immediately beneath the surface.*

Follow the efferent branchial artery from the first gill. *To do this, dissect the external ceratohyoideus muscle free from its attachment on the distal end of the epibranchial of the first gill arch. At the end of the epibranchial, the first efferent artery divides into two branches, the **external** and the **internal carotids**.*

The external carotid turns ventrad, runs along the epibranchial paralleling the first afferent artery and is distributed anteriorly to the hypobranchial musculature. Where the afferent branchial and the external carotid arteries parallel each other, they anastomose so that the external carotid may appear to be a branch of the afferent branchial. This is actually not the case. If true, the external carotid would receive only impure blood.

To follow the internal carotid and the efferent branchial arteries from the other two gills, carefully dissect away the levator branchiarum muscle and lift up the segmented trunk musculature in this region. Notice a rather large vessel extending cephalo-mesad from the base of the external gills. This is the **radix aorta**. See that it is formed by the union of the efferent branchial arteries from the last two gills. Just anterior to the radix aorta is the internal carotid.

Locate the **pulmonary** artery given off from the radix aorta just mesad of the union of the second and third efferent branchial

arteries. Follow it posteriorly only as far as the shoulder region at this time.

It is not possible to complete the dissection of the arteries in this region from the dorsal side. To accomplish the dissection, cut through the mandibular arch at each angle of the mouth. On the left side, cut caudad from the angle of the mouth through the gill arches, just mesad of the external gills. Now cut transversely through the dorsal wall of the pericardial cavity to the last gill slit of the opposite side. This cut will pass through the conus arteriosus close to its connection with the heart.

This will expose the roof of the pharynx so that the radix aorta and the internal carotid may be followed. Notice that just before the internal carotid turns cephalad to supply the head, it is connected with the radix aorta by a **commissural** artery.

Locate the **vertebral** artery branching cephalad from the radix aorta and mesad to the connection with the internal carotid. In the region just caudad of the occipital condyle, this artery divides, one branch which need not be followed runs forward to supply the brain, the other, a small branch, turns posteriorly along the vertebral column.

The radices aortae of the two sides pass inward, ventrad to the vertebral column and unite to form the **dorsal aorta**.

The Branches of the Dorsal Aorta. A short distance caudad of the union of the two radices of the aorta, the **subclavian** arteries are given off to supply the arm and shoulder region. *Carefully remove the muscles necessary to expose the scapular and suprascapular portions of the girdle and cut the latter away from the body to locate the subclavian artery immediately beneath.*

Do not attempt to follow this artery to its origin from the dorsal aorta at this time, but follow it laterad and see that it divides into two main branches. One branch, the **cutaneous** artery, extends posteriorly to supply the pectoralis muscles and the lateral body wall; the other, the **brachial** artery, supplies the arm.

Open the abdominal cavity and study the branches of the dorsal aorta. Caution! In studying the arteries, care must be used not to destroy the veins. In injecting the animal, the abdominal cavity was partially opened. A cut was made to the right side of the mid-ventral line so as not to destroy a vessel which runs along the body at this point. Make a similar cut to the left side of the mid-ventral line

so that the viscera may be examined from both sides. The mid-ventral strip of the body wall will be held in place by the ventral mesentery which attaches the liver to the body wall. Extend these cuts as far caudad as the pelvic girdle.

The dorsal aorta in *Necturus*, unlike that in the shark, is not attached closely to the body wall but suspended in the body cavity by a dorsal mesentery. Stretch this mesentery lightly and notice paired segmental branches, the **parietal** arteries, given off to the dorsal body wall.

The first visceral branch of the aorta is the **gastric** artery supplying the cephalic end of the stomach. Notice also that one or more small branches of this artery run across and supply the cephalic end of the spleen.

The **coeliac axis** is the next large visceral artery arising from the dorsal aorta. This artery sends branches to the stomach, intestine, pancreas, spleen and liver. Carefully separate the viscera and trace the branches to the parts named.

Caudad of the coeliac axis, the dorsal aorta gives off a variable number of **posterior mesenteric** arteries which supply the intestine. Count the number in your specimen.

The gonads are supplied by numerous short branches direct from the aorta. In the male, these traverse the mesorchium and are called the **spermatic** arteries; in the female, they traverse the mesovarium and are called the **ovarian** arteries. Also in the female, a number of short branches, the **oviducal** arteries, are given off from the aorta to supply the oviducts.

The **renal** arteries are direct branches from the aorta and are very short. Examine closely the ventral surface of the kidney along the medial margin. If the animal has been well injected, the glomeruli may be seen showing through the visceral peritoneum as tiny red spots. In respect to size, the glomeruli in the kidney of *Necturus* are among the largest to be found in vertebrates.

Remove the skin in the pelvic region from the ventral and lateral body wall and leg, on the left side. Locate the ilium, carefully cut through it and extend this cut forward to meet the one made through the body wall on the left side.

Separate the two halves of the ilium and note immediately beneath it the **iliac** artery and vein. Trace this artery from the point where it leaves the dorsal aorta being careful not to destroy

the vein. See that at about the level of the lateral margin of the kidney, one branch, the **epigastric** artery, extends cephalad to supply the body wall. Some distance beyond this point, the iliac artery divides into two: one branch, the **femoral** artery, enters the leg at the head of the femur; the other, smaller than the femoral, the **hypogastric** artery, runs posteriorly to supply the urinary bladder and the cloaca.

After giving off the iliac arteries, the dorsal aorta is continued into the tail as the **caudal** artery. Along its course it supplies branches to the cloacal glands and to the muscles of the tail. *Transect the tail just caudad of the vent and locate this artery in the hemal arch just ventrad of the centrum of the vertebra.*

The Veins.

Locate the **caudal** vein cut in cross section just beneath the caudal artery in the hemal arch. This vein runs cephalad and at the caudal end of the kidneys divides into right and left **renal portal** veins which continue toward the head along the lateral margins of the kidneys. As the renal portal vein courses cephalad, notice that it becomes smaller because it gives off afferent branches to the kidney.

Now locate the large vein, the **postcava**, which returns the blood from the kidneys. This vessel arises between the kidneys and is formed by the union of the efferent veins from the kidneys. As it runs forward it receives numerous **spermatic** or **ovarian** veins from the gonads. At the anterior end of the kidneys, it bends ventrally and enters the dorsal side of the liver a little to the right side.

Within the liver the postcava receives the **hepatic** veins. *Carefully scrape the liver tissue away from the postcava.* Notice that soon after entering the liver it receives one hepatic vein from the rear of the liver, and just before leaving the liver, it receives a second, larger than the first.

Before entering the sinus venosus, the postcava is enlarged to form the **hepatic sinus**. This sinus may receive a small hepatic vein from the left side.

Locate the renal portal veins again. Follow them cephalad and notice that anteriorly they are continuous with a pair of veins, the **postcardinals**, which course forward, one on each side of the dorsal aorta, and enter the **ducts of Cuvier** which in turn

enter the sinus venosus at the level of the transverse septum. Along their course these veins receive the **parietal** veins from the body wall and, in the female, the **oviducal** veins from the oviducts.

Near where the postcava turns ventrad to enter the liver, a small anastomosing vein connects it with the postcardinal veins. In the male, this is a single Y-shaped vessel; the bottom of the Y attaching to the postcava, and the two branches of the Y with the postcardinals. In the female, there are a number of irregular anastomosing vessels in this region.

Locate the **femoral** vein from the leg which was seen while dissecting the branches of the iliac artery. Trace it mesad and note that it joins the renal portal vein at the lateral margin of the kidney.

The system of veins, described above, which collects blood from the leg and tail region, distributes it to the kidneys, collects it again into the postcava and returns it to the heart, constitutes the **renal portal system**.

Before joining the renal portal vein, each femoral vein gives off a cephalic branch, the **pelvic** vein. Notice that right and left pelvic veins run around to the ventral side and meet on the mid-line to form the **ventral abdominal** vein. A little cephalad to the point of union of the pelvic veins, the ventral abdominal receives one or more **cystic** veins from the bladder.

After receiving the cystic veins, the ventral abdominal runs forward receiving branches from the ventral body wall and then enters the caudal end of the liver along the posterior margin of the ventral mesentery. On the dorsal surface of the liver, it joins with the hepatic portal vein described below.

The **hepatic portal** vein receives blood from the stomach, intestine, spleen and pancreas. Trace the **mesenteric** vein from the intestine. Just before reaching the liver, it receives a branch from the anterior which collects blood from the pyloric end of the stomach, ventral portion of the pancreas and duodenal region of the intestine. A little farther cephalad, it is joined by the **splenic** vein from the spleen. This vein also receives blood from the dorsal arm of the pancreas. The ventral abdominal vein, described above, joins these vessels to form the hepatic portal vein which breaks up along the dorsal side of the liver. Follow the hepatic portal vein cephalad and notice that, toward the

anterior end of the liver, it receives two or more **gastric** veins from the anterior end of the stomach.

The blood, collected and distributed to the liver by the hepatic portal vein, is collected from the liver by the hepatic veins, described above. These enter the postcava. This system of veins constitute the **hepatic portal system**.

The **pulmonary** veins may not be injected, but they may be located coursing forward, one on the ventral side of each lung. Shortly before entering the left auricle, they unite into a common trunk.

On the right side of the specimen, the veins which unite to form the duct of Cuvier may be studied. Some of these are very superficial, lying just beneath the skin, so that care must be used in removing the skin in order not to injure them. These veins are usually not injected but are filled with clotted blood so that their course may be followed quite readily.

Carefully remove the skin from the lateral surface of the upper arm. This will expose the **subclavian** vein which drains the arm and shoulder region. Follow it to the point where it enters the duct of Cuvier.

Careful removal of the skin from the region dorsal and medial to the external gills will expose the **jugular sinus** which is an enlarged section of the **external jugular** vein. Dissect away the levator branchiarum muscle and follow this vein caudad. Note that it turns ventrad, runs deeper between the epibranchial of the first gill arch and the trunk musculature and receives the **internal jugular** vein on the medial side. After receiving the latter, as the **common jugular** vein, it turns caudad, runs just ventrad of the epaxial muscle mass and enters the duct of Cuvier near the entrance of the subclavian vein.

A little mesad of the common jugular vein, the Cuvierian duct receives the **lingual** vein which returns blood distributed to the hypobranchial region by the external carotid artery. This vein parallels the course of the external carotid for some distance before entering the duct.

Locate the **lateral** vein which enters the rear of the duct of Cuvier mesad of the subclavian vein. This vein drains the muscles of the body wall and runs forward between the hypaxial and epaxial muscles.

The blood vascular system of *Necturus*, while similar in many respects to that of the shark, nevertheless, shows certain adaptations incident to terrestrial life. *Necturus* is strictly an aquatic form, and although the type of circulatory system possessed by the shark would meet the requirements of its habitat very well, in common with the more terrestrial members of its class, it has inherited a circulatory system partially adapted for lung respiration.

In amphibia, in general, the auricle is divided by a septum into right and left chambers, the left auricle receiving the pulmonary veins from the lungs, and the right auricle, the systemic veins from the body. There is no division of the ventricle into right and left chambers. Blood from the lungs and body, kept separate in the auricles, may mix in the ventricle, although a complete mixing is prevented by valves in the conus and by the arrangement of parts. This is an **incomplete double** type of circulation.

Since *Necturus* is strictly aquatic, the lungs are not important respiratory organs, and there is no need whatever for keeping the blood from body and lungs separate. Accordingly, the septum separating the two auricles, although complete, is fenestrated, which permits mixing of blood in the auricles. Thus, while structurally of the incomplete double type, the vascular system of *Necturus* is functionally similar to the complete single type possessed by fish, as exemplified by the shark.

With these changes in the heart, may be correlated other changes in the venous system.

The postcava is a new vessel not present in forms possessing the complete single type of circulation. The appearance of this new vessel, which collects blood from the posterior part of the body and returns it to the right auricle, is to be correlated with the introduction of lung respiration.

The lateral abdominal veins of the shark are considered as having joined to form the ventral abdominal vein of the amphibia, and at the same time, the anterior connection with the duct of Cuvier is switched to the hepatic portal vein.

The new postcava and altered connections between old veins found to be present in the shark, make possible, in *Necturus*, the return of blood to the heart by a number of routes. Be able to follow the blood in its course through these various routes.

Plate 51. Figure 69. Diagram of the Ventral Aspect of the Arterial System of Necturus.

Draw in the arteries not already shown in the diagram and label completely.

Plate 52. Figure 70. Diagram of the Ventral Aspect of the Venous System of Necturus.

Draw in the veins not shown in the diagram and label completely.

THE BLOOD VASCULAR SYSTEM OF THE CAT

To expose the heart, the thorax must be opened. To do this, make two longitudinal cuts, one on either side of the sternum about one fourth of an inch laterad of the mid-ventral line. These cuts will pass through the cartilaginous sternal elements of the ribs and should extend from the first rib caudad to the diaphragm. From the caudal end of each of these longitudinal cuts, cut laterad freeing the wall of the thorax from the diaphragm. Then remove the lateral wall of the thorax on each side by making a cut on each side passing diagonally across the thorax from the cephalic end of the longitudinal cut to the point where the wall of the thorax was freed from the diaphragm.

Caution! Care must be used in cutting through the first rib in order not to destroy the blood vessels which supply the arm. They lie immediately in front of the first rib. In this dissection, the sternum will be left in place for the time being to preserve the sternal arteries and veins.

Notice the **mediastinal septum** attached to the dorsal side of the sternum. This septum separates the pleural cavities of the two sides. Suspended in this septum, and extending some distance anterior to the heart, is the **thymus gland**. The thymus gland varies greatly in size depending on the age of the cat. It may all but disappear in old cats.

At this time complete the study of the respiratory system of the cat using the description given on page 144.

Dissect away the mediastinal septum and the thymus gland, being careful not to injure any blood vessels. Cut through the pericardium and expose the heart.

The Heart. Without cutting the heart, locate its four chambers, the **right and left auricles** and the **right and left**

ventricles. Notice that the right auricle receives two large vessels, the **superior vena cava** from the anterior part of the body and the **inferior vena cava** from the posterior. Locate the **pulmonary** artery as it leaves the right ventricle. Identify the **aorta** leaving the left ventricle. The pulmonary veins and the internal structure of the heart will be studied later.

Carefully clean up all the vessels entering or leaving the heart.

The Veins Cephalad of the Heart. All the blood from the region cephalad of the heart is brought to the right auricle by the superior vena cava or precava. Just before it enters the right auricle, the precava receives the **azygos** vein which passes forward along the mid-dorsal line of the thoracic cavity. Dissect out this vein and note the **intercostal** veins entering it from both sides.

The precava receives on its ventral side, a short distance anterior to the heart, the **sternal** vein which is formed by the union of two **internal mammary veins**. These parallel the two **internal mammary arteries** which may be studied at this time so that the sternum may be removed. Dissect out the internal mammary arteries and veins. See that the arteries give off, and the veins receive, branches from the sternum. Caudad of the last costal cartilage, the internal mammary artery leaves the thoracic cavity, distributes along the lateral border of the rectus muscle. In the female this artery supplies the mammary gland. Notice that the artery is paralleled in its course by the internal mammary vein.

At about the level of the first intercostal space, the precava is formed by the union of two **innominate** veins. Follow the innominate vein on the right side being careful not to destroy any of the arteries and note that, just anterior to the first rib, it is formed by the union of two large veins, a lateral **subclavian** and a medial **external jugular**.

Just caudad of the union of these two veins, the innominate vein receives on its dorsal side the **vertebral** and **costocervical** veins. Considerable variation may be encountered in the relationships of these two veins. They may unite and enter the innominate by a single trunk, or they may enter separately. They may enter the precava rather than the innominate, or one may enter the innominate, and the other, the precava. The arrangement on the two sides may differ. The vertebral vein can be followed only to the point where it emerges from the

vertebrarterial canal. The costocervical vein drains the region supplied by the corresponding artery described later.

Follow the subclavian on the right side. Before entering the thoracic cavity, this vein is called the **axillary** vein. It will be studied later when the corresponding artery is dissected.

Trace the external jugular toward the head. A short distance anterior to its union with the subclavian, it is joined by the **internal jugular** vein which runs along the lateral side of the trachea and returns blood from the head. The internal jugular varies greatly in size and in its point of entrance into the external jugular.

At a point just anterior to the shoulder, the external jugular receives laterally the **transverse scapular** vein. Follow the vein by transecting the clavotrapezius muscle and see that it crosses the lateral surface of the scapula. On the upper arm, this vein is continuous with one branch of the **cephalic** which is a superficial vein returning blood from the arm. Before entering the external jugular, the transverse scapular vein receives branches returning blood from the region supplied by the thyroid axis artery, described later. These branches may enter the external jugular directly.

Trace the external jugular forward to the angle of the jaw to see that here it is formed by the union of two vessels, the **anterior** and **posterior facial** veins collecting from the head.

A large commissure connects the anterior facial veins of opposite sides. Sometimes this commissure is located caudad of the union of the anterior and posterior facial veins and connects the external jugular of opposite sides.

Blood supplied to the brain in the cat may be returned to the heart by the posterior facial, internal jugular or vertebral veins. All these three veins have communicating branches.

The Arteries Cephalad of the Heart. The aorta is the single large vessel arising from the left ventricle. It makes a sharp curve dorsad and to the left, then passes caudad along the left side of the vertebral column. The portion of this vessel running within the thoracic cavity is called the **thoracic aorta**; after piercing the diaphragm and entering the abdominal cavity it is called the **abdominal aorta**.

The first large branch of the aorta distad of the heart is the **innominate** artery. It gives rise first to a small **mediastinal**

artery distributing to the mediastinal septum and thymus gland, and then to **left and right common carotid** arteries. Sometimes both left and right common carotid arteries leave the innominate by a common trunk. Beyond the point where the carotids are given off, the innominate is continued as the **right subclavian** artery.

The **left subclavian** artery arises directly from the aorta slightly distad of the origin of the innominate. Follow it toward the head and see that it curves around the first rib and enters the arm.

The origin of the common carotids has been described above. Follow the right common carotid toward the head. It runs forward almost to the level of the larynx and then gives off the following branches.

1. The **superior thyroid** artery leaves the common carotid from the ventral side at the level of the larynx and supplies the thyroid gland, some of the throat muscles and superficial muscles of the larynx.

2. At about the same level as the superior thyroid, one or two **muscular branches** pass to the muscles on the dorsal side of the neck.

3. The **occipital** artery is given off dorsally from the common carotid a short distance anterior to the superior thyroid artery. It is distributed mainly to the deep muscles of the neck back of the head.

4. The **internal carotid** is one of the terminal branches of the common carotid. It is a very small artery given off from the dorsal side very near to the origin of the occipital. The two may at times come off as a common trunk. The internal carotid passes cephalad and mesad along the inner margin of the auditory bulla and enters the bulla with the Eustachian tube.

5. After giving off the internal carotid, the continuation of the common carotid is called the **external carotid** artery.

Dissect out the branches of the external carotid. They are as follows:

1. The **lingual** is a large artery which leaves the external carotid near its beginning and passes cephalo-mesad to supply the tongue.

2. Small **muscular branches** are given off anterior to the lingual to supply certain of the muscles of this region.

3. The **external maxillary** artery leaves the external carotid opposite the angle of the jaw. It sends one branch to the submaxillary gland and then runs on to supply the lips and muscles of the lip region.

4. The **posterior auricular** artery is given off laterally a short distance anterior to the external maxillary. It supplies the muscles of the external ear.

5. As the external carotid passes between the cartilaginous auditory meatus and the caudal angle of the jaw, it gives off the **superficial temporal** artery distributing mainly to the temporal muscle.

6. After giving off the superficial temporal, the external carotid turns mediad as the **internal maxillary** artery, the terminal branch of the external carotid. The distribution of this artery will not be studied.

Trace the subclavian artery on the right side. It gives off the following branches:

1. The **vertebral** artery is given off dorsally from the subclavian a little caudad of the point where it turns laterally around the first rib. This branch can be followed only to the point where it enters the vertebralarterial canal. As it passes through the canal, it gives off lateral branches to the muscles of the neck and to the spinal cord. After emerging anteriorly from the vertebralarterial canal, the vertebral arteries of opposite sides unite to form the basilar artery which is one of the main arteries supplying the brain.

2. The **internal mammary** artery is given off from the ventral side of the subclavian about at the same level as the vertebral. Its distribution has been described above.

3. Just anterior to the origin of the vertebral artery, the **costocervical axis** is given off from the dorsal side. This divides almost at once into a small **superior intercostal** artery supplying the first and second intercostal spaces and a larger branch which almost immediately divides into two. One of these, the **transverse colli**, turns laterad in front of the first rib and supplies the anterior serratus, levator scapulae and rhomboideus muscles; the other, the **deep cervical**, leaves the thoracic cavity between the heads of the first and second ribs and supplies the deep muscles of the neck. The transverse colli and the deep cervical arteries need not be followed beyond the point where they branch from each other.

4. The **thyrocervical axis** leaves the subclavian a short distance anterior to the costocervical axis. Follow this artery distad. See that after giving off several small branches to the surrounding muscles, it parallels the course of the transverse scapular vein as the **transverse scapular** artery.

Laterad of the first rib after giving off the four branches named above, the subclavian is continued as the **axillary** artery. Dissect out its branches and the branches of the axillary vein.

1. The **anterior thoracic** artery is the first branch passing forward to supply the medial ends of the pectoralis muscles.

2. The **long thoracic** artery is given off a short distance laterad of the anterior thoracic. It passes caudad to supply the middle portion of the pectoralis muscles and is continued back to the inner surface of the latissimus dorsi muscle.

3. A short distance laterad of the long thoracic, the **subscapular** artery is given off from the axillary. The branches of this artery need not be followed.

4. After giving off the subscapular, the axillary is continued as the **brachial** artery which runs along the humeral side of the biceps muscle and passes through the supracondyloid foramen of the humerus. Its branches need not be followed.

The Arteries Caudad of the Heart. Dissect out and trace the aorta caudad through the thoracic cavity.

Locate the **intercostal** arteries given off dorsally from the thoracic aorta. Note that there is a pair of these for each intercostal space beginning with the third. Recall that the first two intercostal spaces were supplied by the superior intercostal arteries.

Locate the **bronchial** arteries which may arise directly from the aorta at the level of the fourth intercostal space or from the fourth intercostal arteries. They follow the bronchi to the lungs.

Small **esophageal** arteries, varying in number and in their origin from the aorta, supply the esophagus.

Owing to the obliquity of the diaphragm, one or two pairs of **lumbar** arteries arise from the thoracic aorta. These correspond to the intercostal arteries but extend between lumbar rather than costal vertebrae.

Trace the aorta through the diaphragm into the abdominal cavity. *Caution! Be careful in tracing the abdominal aorta and its branches immediately caudad of the diaphragm. In this region,*

the arteries are dorsal to the inferior vena cava and its branches which must not be destroyed while dissecting. Caudad to the kidneys, the arteries are ventral to the vein and its branches.

Within the abdominal cavity, the remainder of the lumbar arteries are given off segmentally to supply the dorsal body wall and lumbar vertebrae.

In addition to the lumbar arteries, the following larger branches are given off:

1. A short distance caudad of the point where the aorta enters the abdominal cavity, the **coeliac** artery is given off ventrally.

The branches of the coeliac are very variable. The student should trace all the branches and represent them as they are in his or her specimen. The arteries may then be named according to the region which they supply. The usual arrangement is as follows:

- a. Sometimes two **phrenic** arteries, small vessels supplying the diaphragm, are given off from the coeliac very close to the aorta. Usually, however, they are given off from the adrenolumbalis, described below. They may arise directly from the aorta near the origin of the coeliac.

About three or four centimeters from its origin from the aorta, the coeliac divides into three main branches.

- b. The most cephalic branch given off from the coeliac is the **hepatic** artery. Trace it cephalad, dorsad of the stomach. It passes to the liver together with the common bile duct but just before reaching the bile duct, it gives off the **gastroduodenal** artery which turns caudad giving off branches to the greater and lesser curvature of the pyloric region of the stomach and to the duodenum and pancreas.

- c. The next branch given off from the coeliac is the **left gastric** artery distributing to the lesser curvature of the stomach. This branch may arise from the hepatic rather than from the coeliac. A small branch, the **dorsal ventricular** artery, is given off from the left gastric and passes toward the dorsal part of the greater curvature of the stomach near its cardiac end. The dorsal ventricular may come off directly from the coeliac artery.

- d. The third and largest branch of the coeliac is the **splenic** artery. It divides into two large branches, one to the cephalic end and the other to the caudal end of the spleen. The latter sends a large branch to the pancreas.

2. The **superior mesenteric** artery is the next branch given off ventrally from the aorta about one centimeter caudad of the coeliac. It supplies the small intestine, caudal portion of the pancreas and the ascending and transverse divisions of the colon. Work out the distribution of this vessel.

On the left side of the superior mesenteric artery near where it leaves the aorta, are two small bodies, closely connected together, from which radiate a number of fibers. These are ganglia of the sympathetic nervous system. While dissecting the arteries, do not destroy these or their connections. They will be studied in more detail later.

3. The **adrenolumbar** arteries, one on each side, are the next to arise from the aorta. They leave the aorta one or two centimeters caudad of the superior mesenteric, passing laterad, and supply the muscles of the dorsal body wall. One large branch of this artery turns caudad, runs dorsad of the kidney and anastomoses with the iliolumbar artery, described below. Paired arteries such as these may not always leave the aorta at exactly the same level.

Usually the **phrenic** arteries are cephalic branches from the adrenolumbar arteries. They reach the diaphragm through its dorsal border. As stated above, they may arise from the coeliac artery.

4. The **renal** arteries are the next pair originating from the aorta. They supply the kidneys.

5. The **spermatic** arteries arise from the aorta at the level of the caudal ends of the kidneys, or occasionally they may arise from the renal arteries. Each artery first extends laterad, then turns caudad and passes through the inguinal canal, together with the corresponding vein and vas deferens, to supply the testis and other structures in the scrotum.

The corresponding branch in the female, is called the **ovarian** artery. It passes laterad to supply the ovary and the cephalic end of the uterus.

6. The **inferior mesenteric** artery is the next branch of the aorta. It is a visceral branch supplying the descending colon and the rectum.

Along the course of this artery is another small ganglion of the sympathetic nervous system. Do not destroy it or its connections.

7. The **iliolumbar** arteries arise from the aorta a short distance caudad of the inferior mesenteric. They pass laterad and divide

into caudal and cephalic branches supplying the back muscles of the region. The cephalic branch anastomoses with the adreno-lumbar artery.

8. Just caudad of the iliolumbar arteries, the **external iliac** arteries branch from the aorta. Each external iliac extends obliquely caudad and just before reaching the tendon of the abdominal muscles at the extreme caudal end of the body cavity, divides into two branches, the **deep femoral** and the **femoral** arteries.

The deep femoral is the medial branch. A short distance from its origin, it gives off branches to supply the bladder, the fat in the inguinal region, the rectus abdominis muscle and then passes on to supply muscles of the hind limb.

The femoral artery passes through the tendon of the abdominal muscles and extends distad to supply the limb.

The branches of the deep femoral and femoral arteries need not be studied.

9. The **internal iliac** arteries leave the aorta about one centimeter caudad of the external iliacs. A short distance from its origin, each internal iliac gives off a branch, the **umbilical** artery, to supply the bladder. It is this artery which, in the embryo, continues out through the umbilical cord to supply the placenta. After giving off the umbilical, the internal iliac continues on to supply the structures within the pelvis and the muscles of the pelvic walls. These branches need not be studied.

10. After giving off the internal iliacs, the aorta is continued as the **medial sacral** artery which supplies the muscles dorsal to the sacrum and the tail.

Interrupt the study of the vascular system at this point to study the sympathetic system of nerves. The description and instructions for this study are given on page 115. In making this study, do not destroy the blood vessels.

The Veins Caudad of the Heart. All the blood coming from the body caudad of the heart, except that carried by the azygos, is returned to the right auricle through the **inferior vena cava** or **postcava**.

This vein is formed at about the level of the last lumbar vertebra by the union of the two **common iliac** veins. It passes

forward, at first dorsal to the aorta, then about midway in the body cavity, it turns around the right to the ventral side of the aorta. It enters the dorsal part of the caudate lobe of the liver, runs forward through this organ, pierces the diaphragm and passes through the thoracic cavity ventrad of the caudal lobe of the right lung and enters the right auricle.

On its way to the heart, it receives the following vessels:

1. The **lumbar** veins which accompany the corresponding arteries.

2. The **iliolumbar** veins which accompany the corresponding arteries.

3. The **right spermatic** vein in the male, or the **right ovarian** vein in the female. The **left spermatic** and **ovarian** veins enter the renal vein of the left side.

4. The **renal** veins from the kidneys. Often two veins rather than one come from the kidneys on either or both sides.

5. The **adrenolumbar** veins which accompany the corresponding arteries.

6. The **hepatic** veins from the liver. These veins vary in number. They collect the blood carried to the liver by the portal vein and hepatic artery and enter the postcava just caudad of the diaphragm. Scrape away the liver tissue to locate these veins.

7. The **phrenic** veins from the diaphragm. These veins do not accompany their corresponding arteries but enter the postcava as it pierces the diaphragm.

The **portal** vein collects blood which has been distributed to the digestive organs and returns it to the liver where it breaks up into capillaries to be recollected into the hepatic veins. This system of veins constitutes the **hepatic portal system**.

Identify the portal vein where it enters the liver. The branches which form this vein need not be studied.

Trace the common iliac veins caudad and see that each is formed by the union of a large **external iliac** and a smaller median **internal iliac** which accompany the corresponding arteries.

Each external iliac is formed by the union of the **deep femoral** and the **femoral** veins which accompany the corresponding arteries.

The **medial sacral** vein which accompanies the corresponding artery usually enters the left common iliac. If it can not be found entering this vein, look for it on the right side.

There is considerable variation in the formation of the common iliac veins, in their union to form the postcava and in the vessels entering the postcava. The following are some of the more common variations encountered:

1. The common iliac veins may be longer than normal so that the postcava is formed farther cephalad than usual.
2. There may be in the abdominal cavity two lateral trunks instead of the single postcava. These unite in the region of the kidneys after receiving the veins named above which normally enter the postcava.
3. The postcava may receive the left rather than the right spermatic or ovarian vein, in which case, the renal vein receives the right spermatic or ovarian vein.
4. The median sacral vein may enter the right rather than the left common iliac, or it may fork, one branch joining each of the common iliac veins.

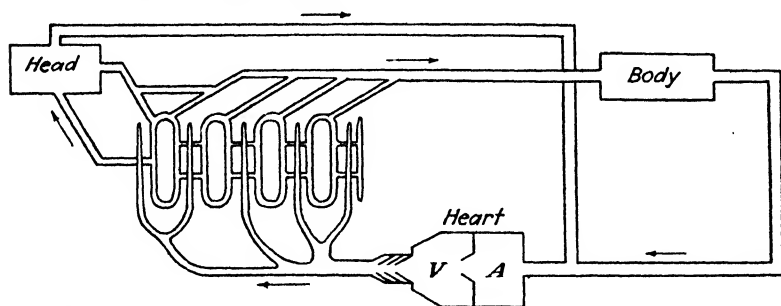
The Pulmonary Veins and Internal Structure of the Heart. *After studying the lungs with the description given on page 144 of the manual, dissect out the pulmonary veins.* They enter the left auricle in three groups. Each group is composed of two or three veins. The first group comes from the anterior and middle lobes of the lung on the right side, the second, from the corresponding lobes on the left side, and the last, from the terminal lobes of both sides.

Remove the heart from the body by cutting through the vessels which enter and leave it. Determine the position of the septum separating the right and left ventricles. This can be located since the walls of the right ventricle are much thinner than those of the left. Open both ventricles on the ventral side by longitudinal incisions which parallel the septum. Wash out the starch mass.

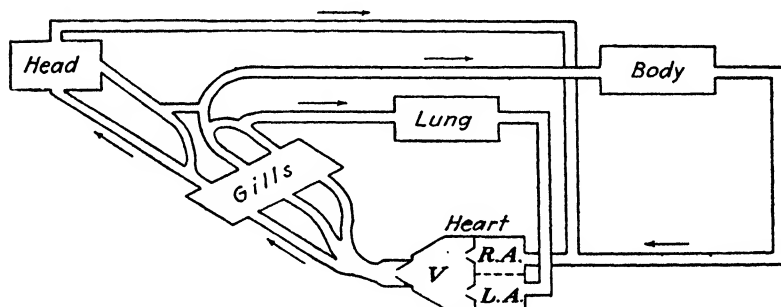
Locate the **tricuspid valve** between the right auricle and ventricle and **bicuspid valve** between the left auricle and ventricle. Notice how the flaps of the valves are fastened to the walls of the ventricle by strong tendinous cords. What is their function? Determine how the valves function. Note the **semilunar valves** at the base of the aorta and at the base of the pulmonary artery. Determine how they function.

Note that two of the heart chambers present in the two forms previously studied are lacking in the cat. The conus arteriosus has split to form two vessels, the pulmonary artery leaving the

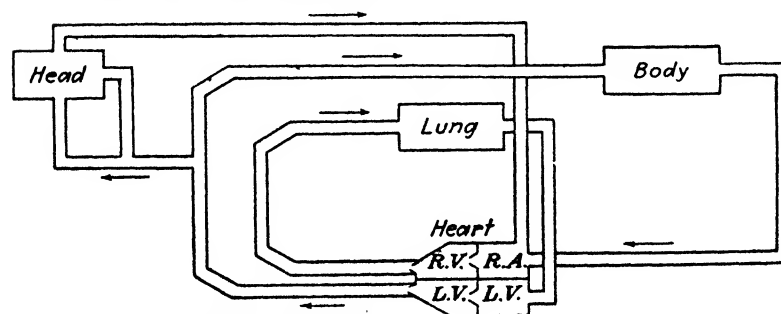
right ventricle and the aorta leaving the left ventricle. A sinus venosus is lacking also. Veins returning from the body enter directly into the right auricle.



A. Shark - Single Plan



B. Necturus - Incomplete Double Plan



C. Cat - Complete Double Plan

FIG. 15.—Schemas to illustrate the types of circulatory plans in vertebrates. (Modified from Barrell.)

The cat possesses a **complete double** type of circulation in which plan the heart is completely divided into right and left

chambers. Recall that in *Necturus* the auricle is divided into right and left chambers, but that both empty into a single ventricle. In the cat the ventricle is also divided into right and left chambers. This complete division of the heart is accompanied by a division of the circulation into two systems, one associated with the right and one with the left side of the heart. The system associated with the right side of the heart which supplies the lungs is called the **pulmonary circulation** and that associated with the left side which supplies the body, the **systemic circulation**.

As a result of this division, it is necessary that blood be pumped through the heart twice for each complete circuit of the body, once to be oxygenated in the lungs and once to perform its work in the tissue capillaries.

The diagrams shown on page 187 present the single, the incomplete double and the complete double plans of circulation in vertebrates as illustrated, respectively, by the shark, *Necturus* and the cat.

Plate 53. Figure 71. Diagram of the Ventral Aspect of the Arterial System of the Cat.

Complete the diagrams as in previous studies and label completely.

Plate 54. Figure 72. Diagram of the Ventral Aspect of the Venous System of the Cat.

Proceed as in Fig. 71.

DATE OF ISSUE

This book must be returned
within 3, 7, 14 days of its issue. A
fine of ONE ANNA per day will
be charged if the book is overdue.

--	--

